

Science of Wound Healing and Dressing Materials

Vibhakar Vachhrajani
Payal Khakhkhar



Springer

Science of Wound Healing and Dressing Materials

Vibhakar Vachhrajani • Payal Khakhkhar

Science of Wound Healing and Dressing Materials

 Springer

Vibhakar Vachhrajani
Diabetic Foot and Wound Management
Vijay Vachhrajani Memorial Hospital
Rajkot
Gujarat
India

Payal Khakhkar
Diabetic Foot and Wound Management
Vijay Vachhrajani Memorial Hospital
Rajkot
Gujarat
India

ISBN 978-981-32-9235-2

ISBN 978-981-32-9236-9 (eBook)

<https://doi.org/10.1007/978-981-32-9236-9>

© Springer Nature Singapore Pte Ltd. 2020

This work is subject to copyright. All rights are reserved by the Publisher, whether the whole or part of the material is concerned, specifically the rights of translation, reprinting, reuse of illustrations, recitation, broadcasting, reproduction on microfilms or in any other physical way, and transmission or information storage and retrieval, electronic adaptation, computer software, or by similar or dissimilar methodology now known or hereafter developed.

The use of general descriptive names, registered names, trademarks, service marks, etc. in this publication does not imply, even in the absence of a specific statement, that such names are exempt from the relevant protective laws and regulations and therefore free for general use.

The publisher, the authors, and the editors are safe to assume that the advice and information in this book are believed to be true and accurate at the date of publication. Neither the publisher nor the authors or the editors give a warranty, expressed or implied, with respect to the material contained herein or for any errors or omissions that may have been made. The publisher remains neutral with regard to jurisdictional claims in published maps and institutional affiliations.

This Springer imprint is published by the registered company Springer Nature Singapore Pte Ltd.
The registered company address is: 152 Beach Road, #21-01/04 Gateway East, Singapore 189721, Singapore

In loving memories of my parents



*Late Sri Rasikray Tuljashankar Vachhrajani
and Smt. Janakbala Rasikray Vachhrajani*

I specially thank

*My wife, Kalyani; my daughter, Dr. Dhwani;
and my son, Kunj, who allowed me to work
relentlessly for a very long time.*

Dr. Vibhakar Vachhrajani

*Dedicated to
My spiritual guru,
Sri Sri Ravi Shankar*

*My life is totally changed by his knowledge
and with his blessings.*



Foreword



Diabetes mellitus is a serious chronic disease. The global prevalence of diabetes is estimated at over 200 million. This figure has been predicted to reach 333 million by 2025 because of longer life expectancy, sedentary lifestyle, and changing dietary patterns. In India, the estimated number of patients with diabetes is 74 million while 35 million are patients with pre-diabetes. This means that India has approximately 100 million people with diabetes.

Although many serious complications, such as kidney failure or blindness, can affect individuals with diabetes, it is the complications of the foot that take the greatest toll. Foot problems are a threat to every person with diabetes. Worldwide, more than a million lower limb amputations are performed each year as a consequence of diabetes, which means that in every twenty seconds a lower limb is lost to diabetes somewhere in the world. In India every year approximately 200,000 higher level amputations are done for diabetes-related foot complications. This figure is unacceptably high. The treatment and subsequent care of people with diabetic foot problems have a significant impact on healthcare budgets and a potentially devastating effect on the lives of affected individuals and their family members, particularly in developing countries like India.

Of all lower extremity amputations, 40–70% is related to diabetes. In most studies, the incidence of lower leg amputation is estimated to be 5–25/100,000 inhabitants/year: among people with diabetes the number is 6–8/1000. Lower extremity amputations are usually preceded by a foot ulcer in people with diabetes. The most important factors related to the development of these ulcers are peripheral neuropathy, foot deformities, minor foot trauma, and peripheral vascular disease. The spectrum of foot lesions varies in different regions of the world due to differences in socioeconomic conditions, standards of foot care, and quality of footwear.

Foot complications are one of the most serious and costly complications of diabetes. However, through a care strategy that combines prevention, the multidisciplinary treatment of foot ulcers, appropriate organization, close monitoring, and the education of people with diabetes and healthcare professionals, it is possible to

reduce amputation rates by 49–85%. Most of the foot ulcers in Asia are of neuropathic origin. Such neuropathic ulcers are usually possible to heal. This perspective should motivate those fighting to make a difference for people living with diabetes around the world.

Several population-based studies observed a significant reduction in major amputations over time, and, after correction for the increasing number of people with diabetes, in some countries a relative decrease was observed over a longer period of time in the number of lower-extremity amputations in people with diabetes. On the other hand, there are also several countries that report an increase in rates of amputation. The reason for this discrepancy is unclear, but factors such as health-care organization and reimbursement could be involved. Leg amputations are related to increased mortality in people with diabetes. By the time an amputation is necessary, people have usually had diabetes for many years, and often have severe comorbidity. Death around the time of the amputation occurs in up to 10% of cases. Death rates increase over the 5 years following amputation: 30% of patients die within 1 year, 50% die within 3 years, and 70% die within 5 years. In developing countries, these figures tend to be even higher because many people seek medical attention only when their foot problem is so far advanced that their limbs and their lives are threatened.

Diabetic foot complications result in huge costs for both society and people living with diabetes. Foot problems use 12–15% of the healthcare resources for diabetes. In developing countries, the latter figure may be as high as 40%. In some developing countries, foot problems may account for up to 40% of available resources. In India every hospitalization for foot ulcer infection costs Rs 50,000. However, reliable and population-based studies are not available in India especially for operated patients.

Therefore, it is of utmost importance to prevent the ulcers and if they do occur then to treat these ulcers very effectively. Wound care as a science has unfortunately not developed in India. Most of the practitioners still follow 40-year-old methods of wound care. Modern wound care is not part of routine undergraduate or postgraduate teaching. However, in diabetic foot ulcers it is vitally important to treat these wounds with modern modalities. Wound care treatment literature available from developed countries is many times not suitable for Indian situations. Books dedicated solely to wound care in diabetes and in general are rarely available in India. This void has been bridged by Dr. Vachhrajani's book. This book provides very comprehensive knowledge about all aspects of wound care. It gives the pros and cons of all available material, which is usually not explained by many manufacturers. This book will fulfill a longstanding need of medical practitioners. I congratulate Dr. Vachhrajani for his successful efforts in describing such a complicated topic in a very simple manner. I hope the reader will use this book to improve wound care and reduce amputations in diabetes.

Arun Bal, MS, PhD

Foreword



I am glad to write a few words about this excellent review on diabetic foot. Diabetic foot is an important complication among people with diabetes in India. It has been shown that by proper management of the diabetic foot, it is possible to prevent amputations in India.

This book covers all the important aspects in the management of diabetic foot and many other surgical conditions, like debridement, wound dressings, and the latest technologies in wound healing. I would recommend this book to all the doctors interested in this subject.

Vijay Viswanathan, MD, PhD, FRCP
MV Hospital for Diabetes and
Prof M Viswanathan Diabetes Research Centre
Chennai, India

Foreword



Dear Reader,

Diabetes is a major public health burden that has grown to epidemic proportions globally. Throughout the world, the prevalence of chronic, noncommunicable diseases is increasing at an alarming rate; almost 80% of the total adults with diabetes are in developing countries. However, managing diabetic complications is more complex than managing diabetes and keeping sugar levels under control; so is diabetic foot.

Patients with diabetes and neuropathy of other etiologies often have chronic non-healing wound problems. There is a huge burden of long-term dressings and thereby financial burden. Cardiac bypass surgery, orthopedic surgery with implantation for fractures, and vascular surgery with graft could lead to infection due to the presence of foreign objects within the body. These complex wounds also need to be managed.

The book *Science of Wound healing and Dressing Materials* edited by **Dr. Vibhakar Vachhrajani** and **Dr. Payal Khakhkhar** has basic to advanced material for wound management consultants, including undergraduate and post-graduate students. To my knowledge, this book has touched upon even the ancient modalities of treatment for wound management. There is no such comprehensive book by any Indian author available in the market. The principles of debridement and the chemistry of different dressing materials without giving emphasis to manufactures is a point to be noted. In the modern era, the practice is becoming market driven; here the authors have maintained balance.

For any neuropathic ulcers, offloading and immobilization is the principle, which is unknown to many consultants. The chapter exclusively describes the offloading modalities.

The doctors who are not in the field of exclusive wound management are sometimes unaware of different modalities of treatment other than dressing materials like oxygen therapy, ultrasonic therapy, etc. In this book, this segment is covered. This book has also explored diabetic as well as non-diabetic wound problems and management.

I wish those who are interested in wound management will have a good reference book and I congratulate Dr. Vibhakar Vachhrajani and Dr. Payal Khakhkhar for bringing out a wonder book for the reader.

Sincerely,

A handwritten signature in black ink, reading "Banshi", written over a single horizontal line.

Dr. Banshi Saboo

Acknowledgments

As I had a thought of writing a book, Dr. Payal Khakhkhar and Dr. Kunjal Mendha started collecting details of dressing materials available in the market. From day one of starting the write-up of this book, Dr. Payal Khakhkhar worked very hard to upgrade our knowledge from many books and the Internet. She helped me in writing, editing, preparing tables and charts, and continuously upgrading the knowledge of dressings. She even discussed with many surgeons to include newer things in wound care. My special thanks to both of them.

I thank Dr. Arun Bal, Dr. R. T. Mehta, and Dr. S. T. Hemani for giving me good suggestions to improve the subject details in this book. I thank Dr. Gauraviben Dhruva for her guidance in pathophysiological aspect of wound healing.

I thank my wife Kalyani, my daughter Dr. Dhvani, and my son Kunj, for allowing me to give enough time to write a book and to give me encouragement, inspiration, and all the support. I thank Amrish Anjaria for helping me to verify the chemistry part of dressings. I thank Dr. Parth Joshi for helping me proofread the whole book.

My special thanks to Dr. Dastur who has made me a diabetic foot and wound management surgeon. Since last more than 20 years, he gave me the challenge to treat all his diabetic foot patients which inspired me to work hard in this field. The phenomenon work of diabetic foot management inspired me to work for other types of difficult-to-heal wounds, and I started managing all types of complicated wounds. Dr. Dastur is the main source of inspiration for me to select a neglected branch like diabetic foot and wound management. As I was more and more involved in this segment of surgery, a thought came in my mind to write a book. My local “guru” is my respected senior surgeon of Rajkot, Dr. Darius Dastur.

I thank all my hospital staff and a very huge family of more than 30,000 patients who had faith on me for their ailment. I learned so many things from my patients.

Dr. Vibhakar Vachhrajani

Contents

1	Introduction	1
	Cytokines	2
	Growth Factors	3
	Proteinases or Proteases	3
	Moisture Vapor Transmission Rate (MVTR)	5
	Wound Measurements	5
	Simple Dressings	6
	Saline Gauze Dressing	6
	Film Dressing (Non Medicated)	6
	Paraffin Gauze Dressing	6
	Composite Dressings	7
	Surgical Treatment for Wound Healing	8
	References	9
2	Pathophysiology of Wound Healing	11
	Repair of Wounds of Skin	12
	Additional Features of Wound Healing	14
	Wound Contracture	14
	Tensile Strength of the Wound	14
	Primary and Secondary Wound Healing	15
	Biochemistry of Wound Healing	15
	Control of Healing Process	15
	Diabetes and Wound Healing	15
	Role of Exudate	16
	Epithelial Mesenchymal Interaction in Healing	16
	Role of Vitamins and Nutrients in Healing	16
	Factors Influencing Healing of Wounds	17
	Comments	19
	References	19
3	Debridement	21
	Mechanical Debridement	27
	Wet to Dry Dressing	27
	Whirlpool or Hydrotherapy	27

Pulsed Lavage or Pusatile Jet Lavage	28
Jetforce	29
Ultrasonic Therapy	31
Chemical Debriders	31
Enzymes	31
Dakin's solution	35
Eusole	35
Biological Debridement	35
Maggots Therapy	35
Application	36
Contra indication for Use of Maggot Therapy	38
Treatment of Maggots Infected Wound	38
Autolytic Debridement	38
Surgical Debridement/Sharp Debridement	39
Comments	40
Biofilm and its management	40
References	41
4 Antiseptics and Local Antibiotics	43
Merbromin	43
Comments	44
Acriflavineum Chloride	44
Comments	44
Chloroxylonol	45
Preparations	45
Chlorhexidin	45
Comments	45
Hydrogen Peroxide	46
Chemistry of Hydrogen Peroxide	46
Comments	47
Benzoin Resin	47
Comments	47
Iodine	48
Mechanism of Action	48
Comments	49
Silver	49
Mechanism of Action	50
Contraindications of Silver Dressings	52
Comments	52
Octenidine Dihydrochloride (0.05% W/V)	52
Polyhexamethylene Biguinide 1% v/v (0.2%PHMB)	52
Hypochlorous Acid and Sodium Hypochlorite	53
Tetrachlorodecaoxide (TCDC) 0.002%	54
Local Antibiotics	54
Antibiotic Beads	54
Comments	56
References	56

5 Absorbent Dressings	59
Foam Dressings	60
Chemistry	60
Sizes/Shapes	60
Mechanism of Action	60
Uses	61
Limitations	61
Cotton and Acrylic Fiber Dressing	62
Features of Three Layers	62
Uses	62
Hydrocolloid Dressings	63
Chemistry	64
Mechanism of Action	64
Uses	64
Contraindications	64
Alginate Dressings	65
Chemistry	65
Mechanism of Action	65
Uses	66
Limitations	66
Hydrofibre Dressing	66
Ceramic Wound Dressing	66
Comments	67
References	68
6 Moisturising Dressings	69
Glycerine Magnesium Sulphate	70
Hydrogel	70
Comments	70
References	71
7 Other Types of Dressings	73
Collagen Dressings	74
Mechanism of Action	74
Clinical Application	75
Trial	76
Comments	76
Honey Dressings and Sugar Paste Dressings	77
Mechanism of Action	77
Clinical Use	77
Sugar Paste	78
Comments	78
Hyaluronic Acid (HA)	78
Function	78
Comments	79

Dressings to Control Malodor	79
Charcoal Dressing	80
Metronidazole Dressing	80
Comments	80
Hemoglobin Spray	81
Comments	81
pH Modulating Dressings	81
Comments	82
Local Insulin Treatment	82
Comments	83
References	83
8 Other Modalities of Treatment	85
Local Oxygen Therapy	86
Indications	88
Comments	88
Ozone Therapy	88
Mechanism of Action	89
Technique	89
Indications	89
Comments	89
Toxicity of Ozone	90
Hyper Baric Oxygen Therapy (HBOT)	90
Indications	90
Mechanism	92
Hyperbaric Therapy Chamber	94
Side Effects	94
Applied Science	94
Comments	94
Negative Pressure Wound Therapy: (NPWT)	95
Equipment	95
Mechanism	96
Uses	96
Advantages	97
Contra Indications	97
Comments	97
Electric Therapy	97
Effects of Electrical Stimulation	98
Indications of Electric Therapy	99
Ultrasonic Therapy for Wound Debridement and Healing	99
Mechanism of Action	99
Precautions and Contraindications	100
Comments	100
Extracorporeal Shock Wave Therapy: (ESWT)	101
Mechanism of Action	101
Comments	101

Compression Bandage and Devices	102
Indications.	103
Lymphatic Compression Device	106
Comments	107
Low Level Laser Therapy: (LLLT)	107
Indication	108
Contraindications	108
Comments	109
References.	109
9 Growth Factors (Third Generation Wound Healing Agents) and Hormones	113
Platelet Derived Growth Factor (PDGF).	114
Effects on Wound	114
Trials	115
Epidermal Growth Factor	115
Transforming Growth Factor	115
Fibroblast Growth Factor	115
Vascular Endothelial Growth Factor (VGEF).	116
Platelet Rich Plasma [PRP], Platelet Releasate	116
Classification.	116
Mechanism of Action of PRP	116
Method to Prepare PRP.	116
How to Apply	117
Trial.	117
Hormones	117
Comments	118
References.	118
10 Regenerative Therapy.	119
Regenerative Therapy Includes.	120
Stem Cell Therapy	120
Cellular Therapy	123
Skin and Living Skin Equivalents (LSEs).	124
Gene Therapy	131
References.	133
11 Offloading, Footwear and Immobilization	137
Offloading	137
Methods to Measure Pressure Areas.	138
Methods to Offload	139
Footwear	142
Role of Insoles	142
Out Sole Modifications	147
Silicone Devices	151
Adhesive Felt Pads [Felted Foam Dressing (FFD)]	154

Immobilization	155
Comments	157
References.	157
12 Hypertrophic Scars and Keloids	159
Silicone Gel Sheet.	160
Mechanism of Action	161
Comments	161
References.	161
13 Different Types of Wounds	163
Burns Wounds	163
Malignant Wounds	164
Radiation Wounds.	165
Pressure Ulcers	166
Vasculitic Ulcers	167
Case Presentations	168
References.	174
Index	177

About the Authors

Vibhakar Vachhrajani, MBBS, MS is a practicing surgeon with over 30 years of experience and has worked in the area of diabetes and wound care for over two decades. Dr. Vibhakar has trained at prestigious institutes such as Kings College London, Lutheran General Hospital, Chicago, and Raheja Hospital, Mumbai. Apart from surgery, he is also a keen researcher and has published his work in various journals across the globe. Dr. Vibhakar has also delivered lectures at various platforms at the national and international levels. He has organized more than 100 public awareness programs to prevent limb amputation and is currently running a tertiary care center for diabetic foot and wound management in Rajkot.

Payal Khakhkhar, BHMS has over 7 years of experience in diabetes and wound care management. She has worked in different departments in government hospital, Rajkot, Gujarat. At present she is working at Vijay Vachhrajani Memorial Diabetic Foot Hospital, Rajkot. As an evid researcher, she has participated in phase 3 clinical trials on wound management protocols at national and international institutions. She is also a trained diabetes educator from V Mohan's Institute Of Diabetology, Chennai, and has held various lectures in the field of diabetes prevention at state and the national level.

Abbreviations

ATA	Atmosphere absolute
BFGF	Basic fibroblast growth factor
BM-MSC	Bone marrow mesenchymal stem cells
C	Celsius
CAD-CAM	Computer-assisted design-computer-assisted manufacturing
CGF	Control gel formula
CMC	Carboxymethyl cellulose
DFU	Diabetic foot ulcer
DNA	Deoxyribonucleic acid
DVT	Deep vein thrombosis
EGF	Epidermal growth factor
EPC	Endothelial precursor cell
ESC	Embryonic stem cell
ESWT	Extracorporeal shock wave therapy
ETO	Ethylene oxide
F	Fahrenheit
FGF	Fibroblast growth factor
GABA	Gamma-aminobutyric acid
GF	Growth factor
H ₂ O ₂	Hydrogen peroxide
HA	Hyaluronic acid
HBO	Hyperbaric oxygen
HBOT	Hyperbaric oxygen therapy
HGF	Hepatocyte growth factor
HOCL	Hypochlorous acid
IGF	Insulin-like growth factor
IL	Interleukin
KCL	Potassium chloride
LLLT	Low-level laser therapy
LSE	Living skin equivalent
MMP	Matrix metalloproteinases
MRSA	Methicillin-resistant <i>Staphylococcus aureus</i>
MSC	Mesenchymal stem cell
MVTR	Moisture vapor transmission rate

NaoCl	Sodium hypochlorite
NPWT	Negative-pressure wound therapy
NSAIDs	Nonsteroidal anti-inflammatory drugs
PAPB	Polyaminopropyl biguanide
PCMX	Para-chloro-meta-xyleneol
PDGF	Platelet-derived growth factor
PDLLA	Poly-DL-lactic acid
PGA	Phosphoglyceric acid
PHMB	Polyhexamethylene biguanide
PLA	Poly lactic acid
PLGA	Poly lactic-co-glycolic acid
PMMA	Polymethyl methacrylate
P-PRF	Pure platelet-rich fibrin
PRP	Platelet-rich plasma
PVD	Peripheral vascular disease
RONPT	Regulated oxygen-enriched negative pressure-assisted wound therapy
SIS	Small intestine submucosa
SOD	Superoxide dismutase
<i>Staph. a.</i>	<i>Staphylococcus aureus</i>
TCC	Total contact cast
TCDO	Tetrachloro decaoxide
TcPO ₂	Transcutaneous pressure of oxygen
TGF	Transforming growth factor
USFDA	United States Food and Drug Administration
VEGF	Vascular endothelial growth factor
VLU	Venous leg ulcer
VRE	Vancomycin-resistant enterococci
VRSA	Vancomycin-resistant <i>Staphylococcus aureus</i>

Introduction

1

Abstract

Since so many years people have been trying to heal wounds. Ancient people used so many herbal products to heal wounds like ghee, honey, leaves of different trees, wine, milk, lint, etc. Even many herbal preparations are available today with combination of turmeric powder, aloe vera, karanj oil, etc. Nowadays there are so many varieties of dressing materials available. Contaminated and colonized wounds do not require antiseptics and antibiotics, only infected wounds need a use of antibiotics. There are many systemic and local causes for non healing of a wound. Proteinases, cytokines and growth factors have a significant role in the process of healing.

Man's struggle to heal wounds is very old. In unicellular life, there is healing by regeneration but with evolution to amphibians and mammals it is lost. In mammals, the repair is by inflammation and scar formation. Wound care industry is growing tremendously. The market is worth billions of rupees and many new products are poured in the market, virtually claiming to be better than the older ones. As such, the underlying disease must be treated properly to accomplish excellent healing without use of expensive therapies.

There are many types of dressing materials available in the market. Every person does dressing as per his/her choice and experience. Many a times the dressing materials used are not necessary and non-scientific. But nature is great. Sometimes wound heals with only simple dressing. Every wound has psychological trauma to the patient so the patient must be treated not only medically but psychologically as well. There are systemic factors and local factors which are responsible for non-healing of wound.

Normal wound healing involves immunological and biological systems, it is dynamic and complex process, and involves multiple cells at different stages. In this book we are not discussing in detail about traumatic wounds, burns and

malignant ulcers. Whenever there is a doubt of diagnosis of wound/ulcer, we should take a biopsy to confirm the diagnosis. Many patients have human papilloma virus infected skin around the ulcer in the foot. It is resistant to heal.

Ancient Egyptians used honey, milk, grease, lint, mud or clay and herbs for dressings. Ancient Greek people were using wine and vinegar also to wash wounds [1]. In the mid nineteenth century, Joseph Lister and Louis Pasteur helped to establish a scientific base for wound management. Complex sugars of honey are known to suppress the growth of gram positive bacteria. Wine suppresses pseudomonas proliferation. Milk products may contain cytokines and serve to control pH of the wound [2]. Tannic acid extracted from tea leaves is also used as a wound healing agent.

In Indian literature too, turmeric powder is used as an antiseptic and haemostatic. Even chili powder is used as dressing material after dog bite by common man. The normal saline is a solution of salt, which also works as antiseptic. Some Indian surgeons have used honey and ghee in wounds with satisfying results. Recently one ointment is available with combinations of Aloe vera, Karanj oil, Cow ghee, Honey and Turmeric extract [3, 4]. There are local applications available in homeopathic medicine also.

‘Contamination’ and ‘Colonization’ are the words required to be understood before using antiseptics. Contamination is the presence of non replicating micro organisms on the wound surface (Sibbald et al. 2006). In colonization micro organisms adhere to the surface of the wound and replicate. Colonization does not impair the healing process. Contaminated and colonized wounds do not require antiseptics as bio burden is not causing clinical problems. Wound is thought to be infected when micro organisms on the wound surface penetrate into the wound tissues. Localized infection, spreading infection needs topical antimicrobial dressings.

Wound bed preparation is another important factor to be considered before dressing materials. It is a comprehensive approach where reducing edema and exudates, eliminating and reducing bacterial burden, and correcting the abnormality that contributes to impaired healing are prime important.

In cleaning of wounds, minimal mechanical force should be used with gauze or sponge. Many studies have documented that use of antiseptics such as povidone iodine, Dakin’s solution, acetic acid, hydrogen peroxide, chlorhexidine etc. on open wounds is not only cytotoxic to bacteria but also to WBCs and fibroblasts. This is because their primary mechanism of action is on cell walls, they cannot identify the type of the cell.

Cytokines

It refers to a collection of small protein molecules that are used to provide communication among cells of the inflammatory system. The best known of this group are interleukins. TNF α and IL 1 are cytokines involved in angiogenesis and collagen synthesis [5].

Growth Factors

These are proteins which are crucial for repair process. We will consider this in more details in another chapter.

Proteinases or Proteases

Proteinases are group of proteins involved in tissue repair. These are protein degrading enzymes that can be released by both inflammatory and connective tissue cells. They are crucial for degradation of foreign material, for cell movement promotion through tissue spaces and for distribution of various molecules in the extracellular space.

Many a times, non-healing is attributed to wrong dressings, but we must first take care of the main barriers to healing. If infection is not controlled, pressure not relieved and vascular deficiency not corrected, then the choice of dressing is not important.

Delayed healing process in diabetics may be because of excessive bacterial burden and possibly by the physiologically abnormal cells present in and around the wounds. It is thought that the diabetic process and the ulcer environment itself cause fibroblasts to age.

Dermal wounds in non diabetic patients heal by granulation tissue formation and contraction. In diabetic patients, wound closure is predominantly the result of granulation tissue formation and re-epithelization. Although simple epithelial repair in superficial wounds is less affected, the ability to form collagen in the repair of deeper wound is severely impaired. Fibroblast proliferation is impaired in diabetic ulcers. There is increased concentration of MMPs (Matrix Metalloproteases) and reduced concentration of TIMP-2 (tissue inhibitors of metaloproteases) in diabetic patients.

Advanced glycation end products accumulate in diabetes as a result of hyperglycemia leading to non enzymatic glycosylation of collagen. This process results in production of inflexible abnormal collagen which is prone to breakdown.

Trauma during any movement of foot may not only create a wound but keep it in a chronic inflammatory phase due to neuropathy. Motor neuropathy results in weakness and changes in foot structure which may continue to contribute to tissue injury. Autonomic neuropathy impairs the normal maintenance of skin integrity, vascular tone and skin blood supply, all of which can interfere with normal wound repair.

Delayed wound healing in diabetics is also due to vascular insufficiency, neuropathy and abnormal cell/inflammatory pathway. There are abnormalities of GF production also.

Wound may heal through the following ways:

1. Primary intention
2. Delayed Primary intention

3. Secondary intention
4. Skin Graft
5. Flap.

The Criteria for ideal dressing material are as follows (Turner's criteria)

1. It should be non-adherent to wound bed.
2. It should be impermeable to bacteria.
3. It should maintain moist wound environment.
4. It should be absorbent.
5. It should be non toxic, non allergenic.
6. It should require minimal change of dressings.
7. It should be cost-effective with long self-life.
8. It should be easy to apply and remove.

Classification of dressings

S. no	Name	Indication	Advantages	Disadvantages
1	Gauze-cotton dressing	Moist wound Types	Easily available cheap, good absorbing capacity	Sticks to the wound Painful during change Can damage epithelium Not truly occlusive Requires frequent change
2	Films (Polyurathane based or co- polyester with adhesive backing)	Superficial wounds and surgical sites	Occlusive dressing impermeable to bacteria	Nonabsorbent, hence not useful in exudative wound
3	Foams(polyurethane, gel film or silicone coated)	Exudative wounds and cavities	Form an 'autolytic' layer to remove debris	Need exudates to function, hence not suitable for dry wounds
4	Hydrocolloid (mixture of adhesive, absorbent and elastomeric ingredients, all have top film layer for water proofing)	Highly exudative wounds	Form an 'autolytic' layer to remove debris	Cannot be used in anaerobic infection/ dry wounds
5	Hydrogels(crosslinked polymer such as polyvinyl)	Dry and necrotic wounds	Moisture contributing	Can cause maceration of peri-wound skin. Very minimal absorptive capacity
6	Alginates (soft non woven fibers of brown sea weed)	Moderate to heavy exudation	Highly absorbent, useful for bleeding wounds	Secondary dressing required, risk of drying of wound if used in less exudating wound

Moisture Vapor Transmission Rate (MVTR)

Moisture vapor transmission rate also known as Water vapor transmission rate, is a measure of passage of water vapor through a substance.

Occlusive wound dressings provide patients with moist wound healing. It reduces pain and increases re-epithelization rate. The MVTR of these dressings remains constant even though wound exudate level varies from time to time and from wound to wound. An intelligent wound dressing would have the ability to automatically respond to wound exudate level by self adjusting its MVTR to maintain a constant moist wound environment. Such a dressing would prevent excessive moisturization and wound drying (desiccation).

Effect of moist wound environment on wound healing

- Less and prolonged inflammation,
- More rapid keratinocyte proliferation and migration,
- Earlier keratinocyte differentiation,
- Increased fibroblast proliferation,
- Increased collagen synthesis,
- Early wound contraction.

Biofilms

Biofilm is a complex issue in healing of chronic wounds. We will discuss biofilms in detail in other chapter.

Wound Measurements

It is advisable to take at least two dimensional measurements. Wound mapping and wound photography are also helpful. A reduction in wound volume by an average of 10–15% per week should be considered as chronic wound and treated accordingly [6]. If the wound does not heal by 50% in 4 weeks, then more aggressive approach is needed.



Measurement grid

The wound healing society recommends change of therapy and/or adding adjuvant therapies if the wound size reduction is less than 50% in 4 weeks time. This is because the longer the wound remains open, the greater is the risk of infection, deeper spread of infection, osteomyelitis and ultimately amputation [7].

Simple Dressings

Autoclaving is a simple measure which wound care professionals should know. Autoclave is a simple machine, scientifically designed to sterilize dressing materials and instruments to prevent contamination of the wound. Gauze and bandage should be sterilized with autoclaving or ETO (ethylene oxide).

Saline Gauze Dressing

This is a time-tested, age old method of dressing. Any wound which is healthy, non-infected with good granulation tissue requires only saline dressings; no antiseptic is required. In addition to saline gauze, emollient (non-adherent) dressing can be applied.

Film Dressing (Non Medicated)

Transparent film dressings are breathable materials in which the wound can be inspected. For superficial non-exudating wounds, this is a good dressing. It can also be applied when protection is needed for intact skin. For example: protection of bony prominences such as elbows and heels from friction and to protect and secure I.V. catheters. It can also be used to secure another dressing.

Transparent **film dressings** provide a moist, healing environment; promote autolytic debridement; protect the wound from mechanical trauma and bacterial invasion and act as a cover or as a synthetic skin. Because they are flexible, these **dressings** can conform to wounds located in awkward locations such as the elbow.

Paraffin Gauze Dressing

Paraffin gauze is a non-shedding, non-absorbent dressing and its semi transparency makes the observation of the wound site very easy. It is non-medicated, paraffin impregnated disposable sterile gauze. It is also available with antiseptic

impregnation. The gauze has interlocking threads which minimize fraying when the dressing is cut to shape. It is Ideal to use with antiseptics or other topical agents. Paraffin gauze has a low adhesion quality which makes it extremely comfortable to use on deep abrasions and open wounds. Special type of butter paper prevents loss of medicine. Open weave base fabric allows the wound to drain freely into an absorbent secondary dressing.

Composite Dressings

Composite wound dressings combine different materials in a single dressing. It works in a different way and provides many functions at a time. They can be used as a primary or secondary dressing. They are versatile and provide water proofing, provide a barrier for bacteria and other contaminant.

1. The bottom layer of adhesive or semiadhesive material which remains in contact with the wound and allows entry of exudates.
2. The middle layer is absorptive and may contain antiseptics. It absorbs exudates, keeps it within and helps to maintain moist wound environment.
3. The outer layer is a barrier layer. It restricts the entry of contaminants from outside and manages water vapor transmission.

Some dressings have adhesive boarder.

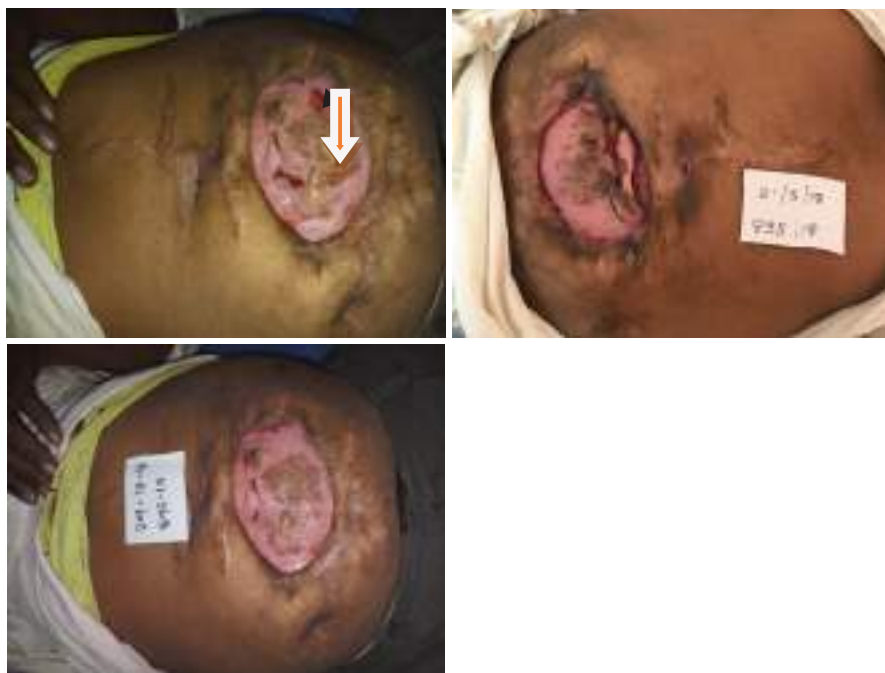
Multilayer composite dressing



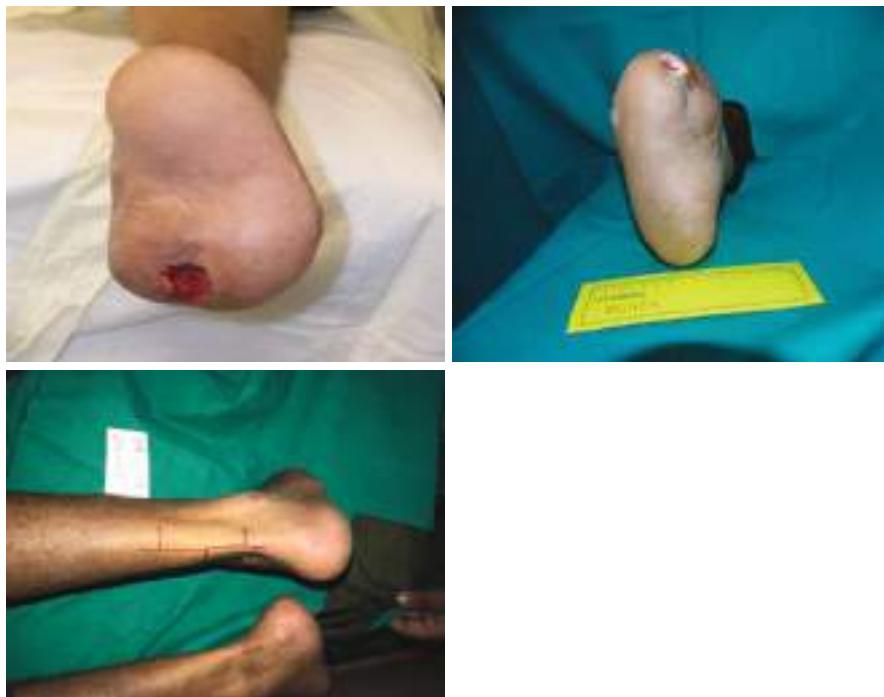Surgical Treatment for Wound Healing

Some of the wounds, especially on foot may need surgical intervention to heal. We will not discuss more in this book, but to innumerate, non healing forefoot ulcers don't heal unless tendoachilles or soleus tendon lengthening/gastroc-soleus recession or Keller's arthroplasty is done. Similarly toe tip ulcers may require corrective surgery for toe deformity. Some resistant to heal ulcers with callous margin can be excised and primarily closed for healing. Skin grafting and flap procedures are known modalities of treatment for ulcers to heal.

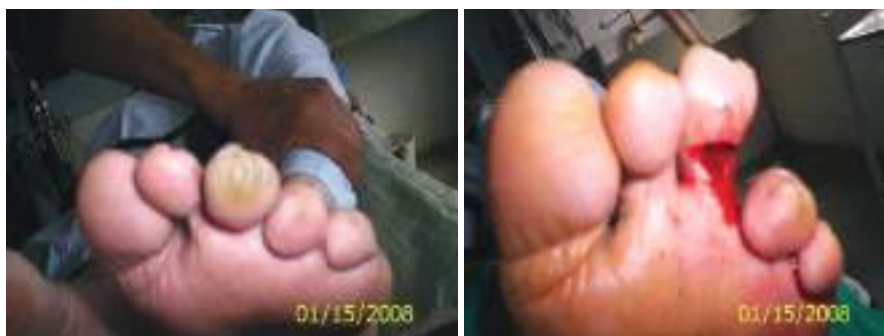One very important principle of healing is removal of pus, foreign body, implants, suture material. Whenever there is doubt of infection in any sutured wound, first thing to do is removal of some of the sutures. In orthopedic surgery many wounds are in the area of implants. If the bone has united, the ulcer would heal only after implant removal. If the bone has not united we need to give antibiotic as per culture sensitivity report till the bone union is strong.



{Infected mesh after incisional hernia surgery needs removal of mesh to heal the wound, but removal of mesh in this case was difficult as huge abdominal wall defect needed management. Gradual, piece meal removal of the mesh done which healed the wound}



Forefoot ulcer-requiring TA lengthening or gastrocsoleus recession



Toe deformity corrective surgery (flexor tenotomy)

References

1. Cohen IK. A brief history of wound healing. Yardley, PA: Oxford Clinical Communication Inc; 1998.
2. Veves A, et al. Chapter 3: The evolution of wound healing. In: The diabetic foot. 2nd ed. Totowa, NJ: Humana Press; 2006. p. 51.

3. Dwivedi D, et al. Evaluation of wound healing, anti-microbial and antioxidant potential of *Pongamia pinnata* in wistar rats. *J Tradit Complement Med*. 2017;7(1):79–85.
4. Mahmudi G, et al. The impact of turmeric cream on healing of caesarean scar. *West Indian Med J*. 2015;64(4):400.
5. Veves A, et al. Chapter 4: The wound healing process. In: *The diabetic foot*. 2nd ed. Totowa, NJ: Humana Press; 2006. p. 60.
6. Sheehan P, Jones P, Caselli A, Giurini J, Veves A. Percentage change in wound area of diabetic foot ulcers over a 4-week period is a robust predictor of complete healing in a 12-week prospective trial. *Diabetes Care*. 2003;26(6):1879–82.
7. Steed DL, Attinger C, Colaizzi T, et al. Guidelines for the treatment of diabetic ulcers. *Wound Repair Regen*. 2006;14:680–92.



Abstract

The process of wound healing is very complex. The reconstitution in lower animals has now progressed to repair in human beings and higher animals. The repair follows inflammation. Endothelial cells, fibroblast, platelets, epithelial cells, all are involved in the process of inflammation and repair. Diabetes has significant role in the process of delay in healing.

The exudates are essential for the process of healing and extreme of exudation, i.e. minimum of exudation and over exudation are pathological. In the process of healing the behaviour of epithelial and mesenchymal cells is unique.

Wound healing is a complex process which includes sequences of cellular and biochemical events to restore tissue integrity after injury [1]. Each of the phases of healing is controlled by biologically active substances called growth factors [2]. To treat a wound without having basic knowledge of the biological principles of wound repair is like trying to sail across the sea without the knowledge of direction. We need to summarize the process of healing before we think of dressings and local management of the wound. As such it is basic pathology; however limited details are included in this book.

• Reconstitution

It refers to the replacement of lost tissue or part by an exact replica complete in design to the last details. The surviving cells, which are differentiated cells, revert to primitive cell types (de-differentiate) and come to lie in an edematous stroma that resembles the primitive mesenchyme of the embryo. The cells in this mass, called the blastema, divide and differentiate in a coordinated manner so that the last tissue is accurately reproduced. Reconstitution is possible in lower animals; in human beings it is possible only in liver, kidney, and pancreatic tissue.

- **Regeneration**

In man and higher animals, reconstruction of lost tissue is done by the process of regeneration. Regeneration implies the complete restoration of pre-existing tissue architecture and all cellular elements in the absence of scar formation. It is the replacement of lost cells by cells of their own kind produced by survivor of the same kind. Regeneration involves a single type of cell and de-differentiation is absent here.

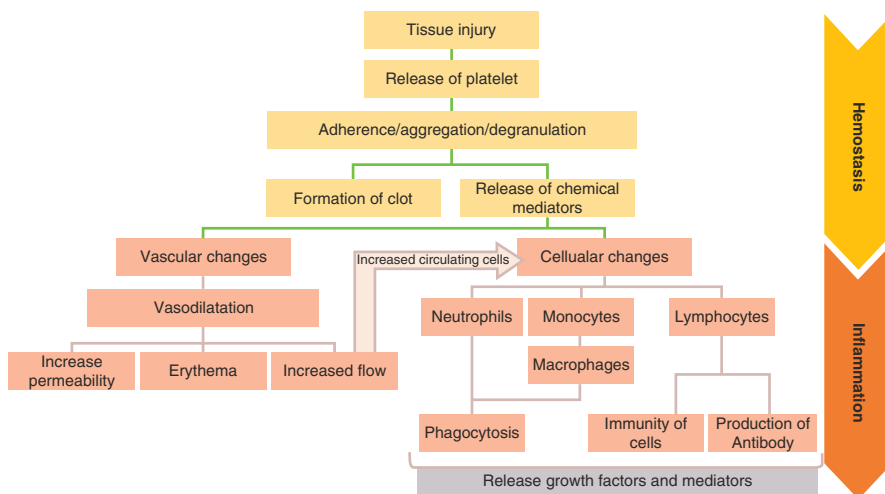
- **Repair**

Repair (to prepare again) is the replacement of lost tissue by cells and tissue of the same kind (regeneration) or more often by cells and tissue of different and a simpler kind.

- **Inflammation and repair**

As such the phenomenon of repair overlaps the phenomenon of inflammation. Inflammation is a response in which the participating cells are mainly phagocytes; in repair the cells are fibroblasts and endothelial cells.

Repair of Wounds of Skin



1. **Formation of clot or crust**—Immediately after any injury clotted blood and clotted lymph accumulate which holds the wound edges together. This serves as a mechanical barrier against bacteria from outside. The fibrin clot provides scaffolding of neutrophils, monocytes, fibroblasts and endothelial cells. Neutrophils are first to arrive in 24 h and prostaglandin release has effect on its arrival.
2. **Removal of debris**—Monocytes invade the clot and get differentiated into macrophages. Monocyte migration takes place in 48–96 h after injury. Macrophages

are activated by growth factor from platelets. They do phagocytosis and generate nitric oxide, oxygen and peroxide. Inflammation separates the slough from the living tissue. Neutrophils and macrophages gather on margin of slough and also invade the clot. Enzymes from these cells and from dead tissue cells soften the clot and the slough. Small amount of slough can be completely removed by enzymatic liquefaction and phagocytosis. These two steps constitute the lag phase of healing.

3. **Formation of granulation tissue**—It is made up of two processes:

(a) **Vascularization**

Endothelial cells invade, migrate and proliferate in the clot. Solid vascular sproutings invade the clot from all sides. Neighbouring buds anastomose or a vascular sprout may connect itself to a functioning capillary. There is capillary plexus formation in granulation tissue. Production of degradation enzyme plasminogen activator helps the capillaries to make its way in the matrix. Within a few hours of their formation, solid buds develop lumina and blood flows through them. This is called angiogenesis. Angiogenesis can be triggered by soluble factors-cytokines and Hagman's factor-factor 12.

(b) **Proliferation of fibroblasts**

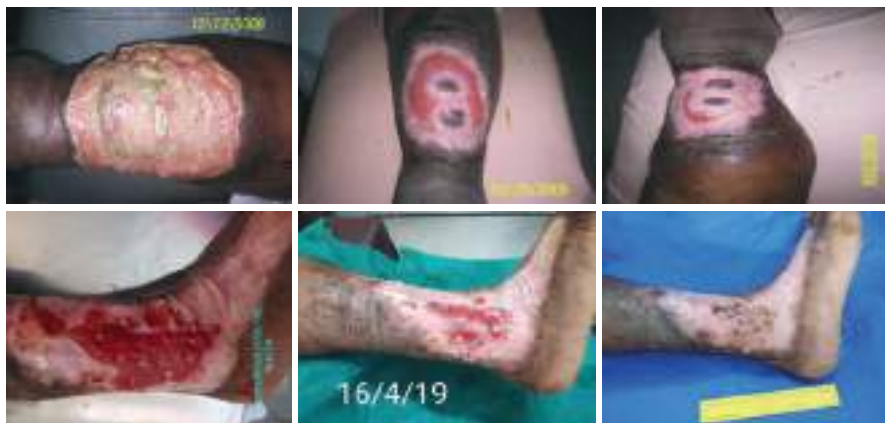This is the most important feature of the healing process. Fibroblasts proliferate simultaneously with endothelial cells and invade the clot at the same time as endothelial cells. Fibrin matrix is replaced by collagen rich new matrix. Fibroblasts produce and release proteoglycans and glycosaminoglycans. Once sufficient collagen matrix has been deposited in the wound, the fibroblasts stop producing collagen.

For the first couple of days the intercellular spaces are full of proteinous fluid. Later it becomes gelatinous and shows increasing quantities of mucopolysaccharides. The intercellular fibres are laid down in this wound fluid and the concentration of mucopolysaccharide starts declining. In the beginning the collagen fibers run parallel but soon their arrangement is remodeled to suit local mechanical stresses.

4. **Organization**—The clot is gradually replaced by newly formed capillaries and fibroblasts. This process is known as organization. The new tissue is known as granulation tissue because it has the appearance of pink granules protruding in the floor of the wound. Microscopically, these granules show newly formed capillaries, fibroblasts and leucocytes. The granulation tissue lacks in nerves so it is insensitive. It is also resistant to infection because of macrophages present in its interstices. As more and more collagen fibers are laid down, granulation tissue becomes less cellular and vascular. The conversion of granulation tissue into a fibrous scar tissue is known as cicatrization.

5. **Epithelization**—Epithelial cells (of stratum corneum and stratum granulosum) from the margin of the wound flatten, elongate and begin to migrate as a continuous sheet. Some workers have described the sheet as a homogenous syncytium with many dark nuclei. Amoeboid movements of epithelial cells and/or reduction

in the intensity of mutual adhesions of cells may be the underlying mechanism of migration of cells. The newly formed epithelium is only one or two layers thick; it becomes stratified & keratinized later. Stratification is produced by a fresh wave of mitotic activities in the regenerated epithelium. The re-epithelization represents a sequence of steps involving mobilization, migration, mitosis and cellular differentiation of epithelial cells.



These photographs show how from an island of epithelium, the cells can grow and cover the wound.

Additional Features of Wound Healing

Wound Contracture

It is the shrinkage of the area of the wound. It is due to the following reasons:

1. Drying of the wound.
2. Granulation tissue contraction
3. Contraction of dermis.

It is now believed that eosinophilic stellate cells found in early wound and called by some “modified fibroblasts” are actually myofibroblasts. These cells behave as plain muscle and generate the contracting force. Another theory suggests that the locomotion of all fibroblasts leads to reorganization of the matrix and therefore contraction.

Tensile Strength of the Wound

In the beginning (3–4 days in case of incised wound) a wound has a little tensile strength because the clot alone is holding the edges together. Thereafter (up

to 21 days) tensile strength increases rapidly as collagen deposition increases. By the eighth or tenth day, there is sufficient restoration of tensile strength and stitches can be removed.

Primary and Secondary Wound Healing

Primary healing is seen in sharp, incised wounds. The inflammatory reaction is mild. Macrophages quickly clear away the small amount of debris from second day onwards. Granulation tissue is seen involving the small clot and organizing it. In the meanwhile, the epithelium has begun to migrate and regeneration has commenced in the basal cells. Within about 48 h, epidermis covers the raw surface completely.

In secondary healing, there is more of inflammation, more of granulation tissue formation and more of scar formation.

Biochemistry of Wound Healing

- First Phase (or lag phase)—There is increase in hexosamine content of the wound fluid, rise in gamma globulin, proteins containing methionine, amino acids like glycine, leucine and proline. This means in this phase mucopolysaccharides and soluble protein precursors of collagen accumulate in the wound.
- Second Phase—In the second phase (collagen formation), cysteine containing proteins accumulate and the concentration of Hexosamine falls. Since the amino acid hydroxy proline is found exclusively in collagen, the hydroxyl proline content of a wound is taken as an index of the collagen content of the wound.

Control of Healing Process

Wound site contains several regulatory GFs (Growth Factor), each of which works in cooperation with others [3]. The surface of responsive cells has specific cell receptors for different growth factors. The details of growth factors will be discussed in other chapters.

Diabetes and Wound Healing

Autonomic neuropathy may cause alterations in circulation and diversion of nutritive flow, resulting in cutaneous ischemia [4]. Many diabetic patients have areas of low flow and hypoxia in their feet and ankles, even in the presence of palpable pulses. Contributing factors may be increased blood viscosity, platelet aggregation, excessive adherence of leukocytes to capillary endothelial cells, and accelerated capillary endothelial growth [5–7]. It is thought that the poor blood flow in diabetes is not only related to nitric oxide vascular changes but also to a lack of angiogenesis related to wound proteases, which destroy angiogenic growth factors. The

diabetic responses to local tissue stresses are thrombosis and necrosis as opposed to an inflammatory response in non diabetic patients [8].

Role of Exudate

Exudate formation is a normal phenomenon. Its quantity varies from minimal to excessive exudation. It contains nutrients, growth factors, high quantities of WBCs, it cleanses the wound, maintains moist wound environment and promotes epithelialization. Exudate is required for wound healing, if the ulcer dries out superficial cells die. Application of varieties of antiseptics locally increases wound exudation. Movement of surrounding joints, anemia and hypoproteinemia, infection, presence of foreign body in the wound and keeping the limb hanging have effect on exudation. Exudate management and maintaining moist wound environment is the principle of recent dressing materials and modalities of treatment.

Epithelial Mesenchymal Interaction in Healing

The skin as well as the intestines, liver, lungs and glandular tissues contain epithelial and mesenchymal cells. The epithelial cells firmly adhere to one another, forming layers in which the basoapical polarity can be observed. The mesenchymal cells are non-polarized and are capable of movement, as individual cells due to the loss of intercellular connections [9].

There is also role of keratinocyte fibroblast interaction in wound healing. Keratinocytes stimulate fibroblasts to synthesise growth factors which again stimulate keratinocyte proliferation. In this mechanism transforming growth factor β plays a major role. In the mid and late stage of wound healing the inter play of keratinocytes with fibroblasts changes the micro environment from inflammatory to granulation tissue stage.

Role of Vitamins and Nutrients in Healing

Animal studies have established a specific role for nutrients like vitamin A, B, C, trace elements (selenium, zinc, copper, manganese), and amino acids (arginine and glutamide)

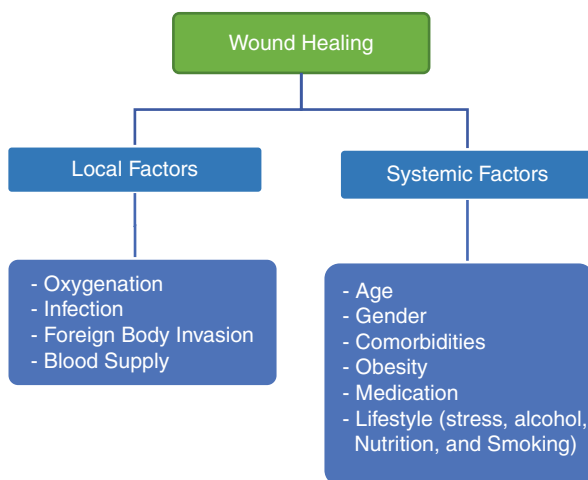
- Vitamin A: It is required for granulation tissue, synthesis of collagen, epithelialization and macrophage functioning.
- Vitamin E: It decreases inflammatory phase of wound healing and enhances immune function, decreases platelet aggregation.
- Vitamin B: This is a complex group of eight vitamins, they are required for immune system, white blood cell functioning and antibody production. They help in tensile strength of the wound.
- Vitamin K: It is essential for normal blood clotting. Its deficiency leads to prolonged inflammatory phase and bleeding wounds.

- Vitamin C: It is useful for absorption of iron and synthesis of collagen.
- Vitamin D: Cathelicidin, an antimicrobial peptide induced by vitamin D, promotes wound healing.
- Copper: It enhances wound tensile strength. It is required for immune function.
- Adequate calorie supplementation is essential in addition to macronutrients and micronutrients. The patients with wounds of large sizes are in catabolic state and their calorie and protein requirements are high.

Factors delaying wound healing

Temperature	<u>Wounds heal slowly in winter</u>
Age	Wounds heal slow in elderly
Radiation	Small doses of radiation stimulates healing, but more radiation delays wound healing
Vitamin A deficiency	Reduced granulation, macrophage function
Vit B deficiency	Reduced immune system and tensile strength of wound
Vit c deficiency	Prolonged first phase of wound healing, fragile capillaries, reduced tensile strength of the wound
Vit D deficiency	Reduced wound healing
Vit E deficiency	Increased inflammatory phase, increased platelet aggregation, reduced immune function
Vit K deficiency	Prolonged inflammatory phase, increased bleeding
Zinc deficiency	Delayed wound healing
Copper deficiency	Reduced tensile strength, reduced immunity
Iron deficiency	Reduced oxygenation to wound, delayed healing

Factors Influencing Healing of Wounds



1. **Age**—It is experienced that wound healing is better in youngsters and children but is slow or normal in old age.
2. **Temperature**—Wounds heal slowly in cold weather. Wounds of the abdomen heal quicker than wounds of the feet.
3. **Radiation Energy**—Whole body x-irradiation and whole body or local ultraviolet rays in small doses stimulate healing. Large doses of x-ray irradiation retard healing.
4. **Deficiency**—Deficiency of proteins and vitamin C delays healing. Protein deficiency prolongs the first phase. The wound of protein deficient experimental animal shows a low concentration of hexosamine and hydroxy proline. The administration of methionine reverses the chemical abnormalities and the normal rate of healing is resumed. Methionine is transformed into cysteine and then utilized. Thus deficiency of proteins is in fact deficiency of sulphur containing amino acids. Arginine as micronutrient is essential for collagen synthesis. Glutamine has a role in leukocyte apoptosis, superoxide production, antigen processing and phagocytosis, all these have role in wound healing.
 - **Iron Deficiency** decreases oxygen transportation to wound there by delays wound healing.
 - **Vitamin C Deficiency** produces prolongation of the first phase. The wound is edematous, the dead tissue is not quickly absorbed. The ground substance accumulates and lacks metachromasia. Capillaries are unduly fragile, fibroblasts lack orientation and the maturation of reticulin fibres into collagen fibres is held up. The wound lacks tensile strength and may break down.
 - **Zinc Deficiency** delays healing in experimental animals, zinc administration promotes healing. Zinc is an essential trace element in the human body and it serves as a co-factor in numerous transcription factors and enzyme systems. Zinc deficiency has been associated with delayed wound healing. Topical zinc is widely used in wound treatment.
 - **Hormones** like deoxycortisone and anabolic steroids like testosterone promote healing, thyroxine deficiency shows slowing of the healing process. Estrogen in large doses impairs the formation of granulation. Corticosteroids in large doses hamper capillary dilatation and permeability (anti inflammatory effect); delays the formation of granulation tissue and collagen. The tensile strength of the wound and wound contraction are reduced and healing is delayed.
5. **Local Factors**—Local factors that delay the wound healing are infection, movement of surrounding joints, diminished blood supply, presence of foreign body, dead tissue, suture material and talcum powder. Wrongly done scraping, very tight bandage especially in vascular insufficiency, decreased venous return, excessive use of irritant local medications, edema, all these factors also interfere in healing.

Wound hypoxia leads to reduced antimicrobial activity, reduced cellular metabolism and proliferation, reduced angiogenesis. Increase in oxygen supply

to wound increases collagen production and its tensile strength. Due to vascular disruption and high oxygen consumption by metabolically active cells, the micro environment of the early wound is depleted of oxygen and is quite hypoxic. Temporary hypoxia after injury triggers wound healing but prolonged or chronic hypoxia delays wound healing.

6. Systemic Factors

Stress results in the deregulation of immune system and thus delays healing. Sex hormone is also important as, compared to aged females, aged males have been shown to have delayed healing of acute wound. Hereditary healing disorder, jaundice, uremia, obesity, medication [glucocorticoids, NSAIDs, chemotherapeutic drugs], venous insufficiency, smoking (Nicotine probably interferes with oxygen supply by inducing tissue ischemia due to vasoconstrictive effect) [10], all these affect healing of wound. Poor cardiac function and hypoproteinemia also interfere in wound healing.

Comments

Pathophysiology of wound healing involves many chemicals and it is very complex. With evolution, repair by reconstitution is changed to regeneration with more of fibrosis. All the stages of wound healing require growth factors. Exudate is useful to a certain extent but excess of exudate is suggestive of infection and needs exudate control dressings. Wound healing science now focuses on matrix-metalloproteases. Diabetes affects the process of healing by means of excessive sugar in the blood, autonomic neuropathy, cutaneous ischemia, prolongation of inflammatory process of wound healing, and alteration in growth factors. The epithelisation is less affected but collagen function is greatly affected by glycosylation of proteins, so the scar is weak with less of elasticity. In diabetes because of neuropathy there is no pain and so patient cannot protect his/her ulcer. There is immune suppression as well as reduced mitotic activity found in diabetic patients.

References

1. Park JE, Barbul A. Understanding the role of immune regulation in wound healing. *Am J Surg.* 2004;187:11S–6S.
2. Steed DL. The role of growth factor in wound healing. *Surg Clin North Am.* 1997;77:575–86.
3. Brown CL, Manney LB, Griffin J, et al. Enhancement of wound healing by topical treatment with epidermal growth factor. *N Engl J Med.* 1984;321:76–9.
4. Edmonds ME, Blundell MP, Morris ME, Thomas EM, et al. Improved survival of the diabetic foot: the role of a specialized foot clinic. *Q J Med.* 1986;60(232):763–11.
5. Aagaens O, Moe H. Light and electron microscopic study of skin capillaries of diabetics. *Diabetes.* 1961;10:253–9.
6. Arenson DJ, Sherwood CF, Wilson RC. Neuropathy, angiopathy and sepsis in the diabetic foot: II. Angiography. *J Am Podiatry Assoc.* 1981;71(12):661–5.

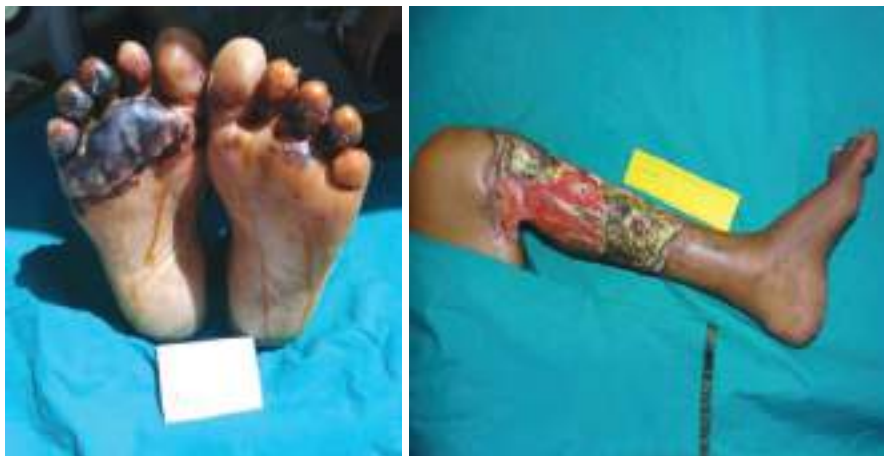7. McMillan DE, Breithaupt DL, Rosenau W, et al. Forearm skin capillaries of diabetic, potential diabetic and nondiabetic subjects: changes seen by light microscope. *Diabetes*. 1996;15(4):251–7, 19.
8. Joseph WS, Lefrock JL. The pathogenesis of diabetic foot infections: immunopathy, angiopathy, and neuropathy. *J Foot Surg*. 1987;26(1 suppl):S7–S11.
9. Friedman SL. Mechanisms of hepatic fibrogenesis. *Gastroenterology*. 2008;134:1655–69.
10. Deodhare SG. Y.M. Bhende's general pathology. 5th ed. Mumbai: Popular Prakashan; 1994.

Abstract

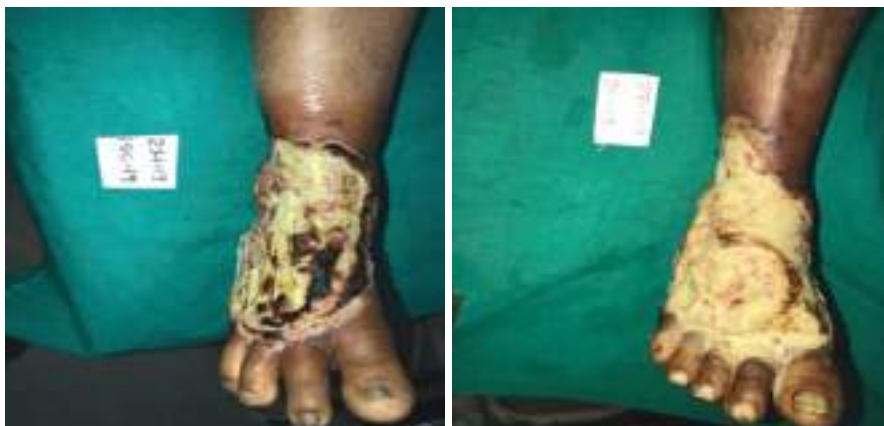Debridement plays a major role in wound management, it is a complete science. It requires expertise to know when to debride, how much to debride and when not to debride. Simple debridement with gauze and scoop is helped by advances in debridement technology like whirlpool, water pressure devices, water knife, ultra sound, laser, etc. Advances in dressing materials provides environment for better autolytic debridement. Maggot therapy is an age old biological debriding therapy.

Debridement is a basic procedure to help healing of wound. Debridement helps in removal of bacteria, to convert a chronic wound into an acute wound and lots of growth factors are thereby released in the wound. We remove debris, slough or necrotic tissue in debridement. This consists of fibrinous material, nucleo proteins, collagen and elastin. Debridement can be of two types, either only necrotic tissue is removed or even some part of viable tissue is also removed along with the nonviable tissue.

Dead necrotic tissue and hyper granulation tissue should be debrided and in chronic wounds, the biofilm also needs to be debrided. Besides, the cells at the wound edge develop a tendency to become senescent or they have decreased ability to perform DNA replication needed for process of healing [1]. They lose their ability to produce cytokines. Wounds are of three different types: **Black wounds** with dry black eschar which requires surgical debridement, **Yellow wounds** requires non surgical debridement and **Red wounds** don't require debridement.

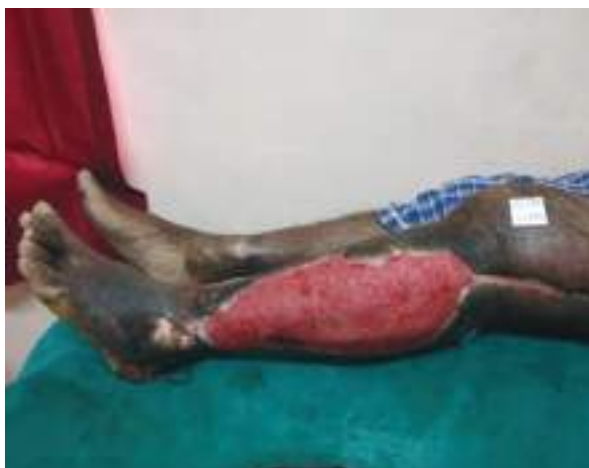

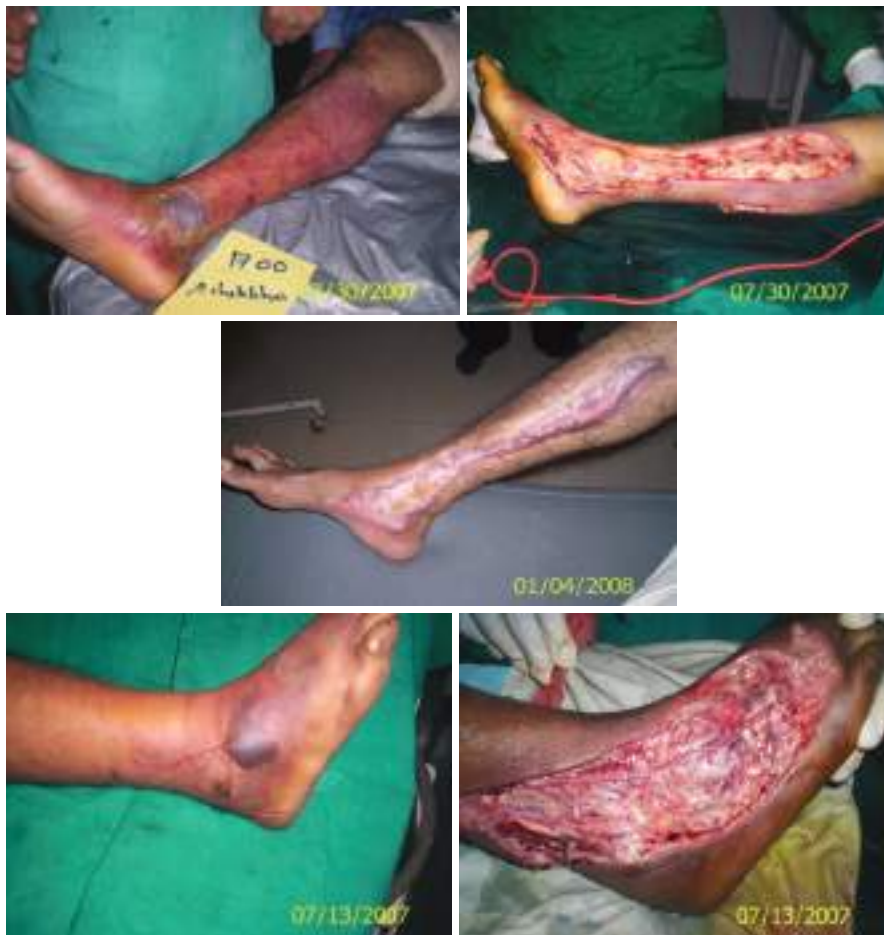Black wounds



Yellow wound

Red wound





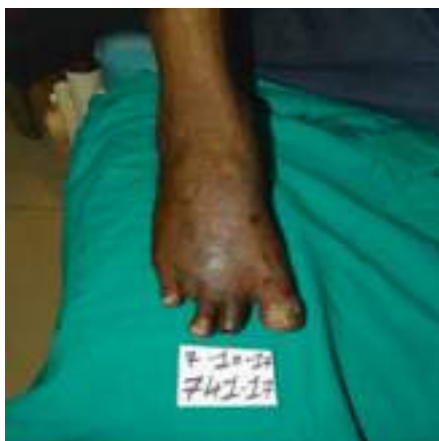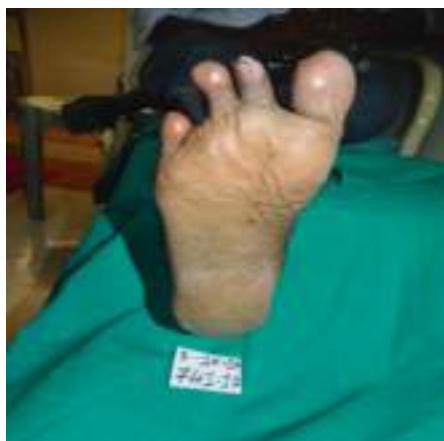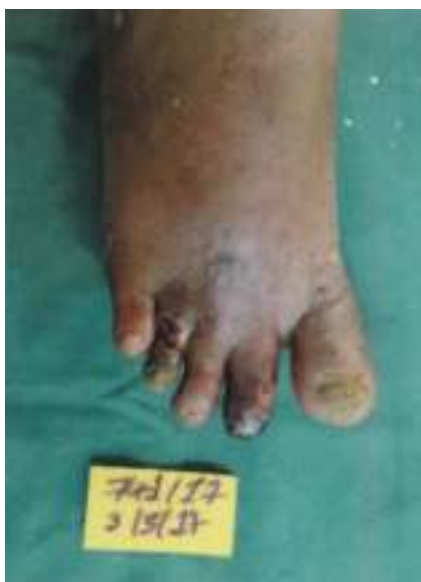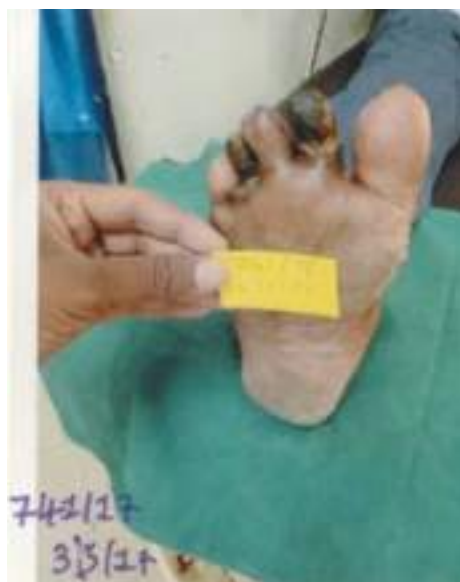Necrotising fascitis requires not only multiple incisions but exploration and excision of skin and subcutaneous tissue which is not bleeding. This is known as adequate debridement.

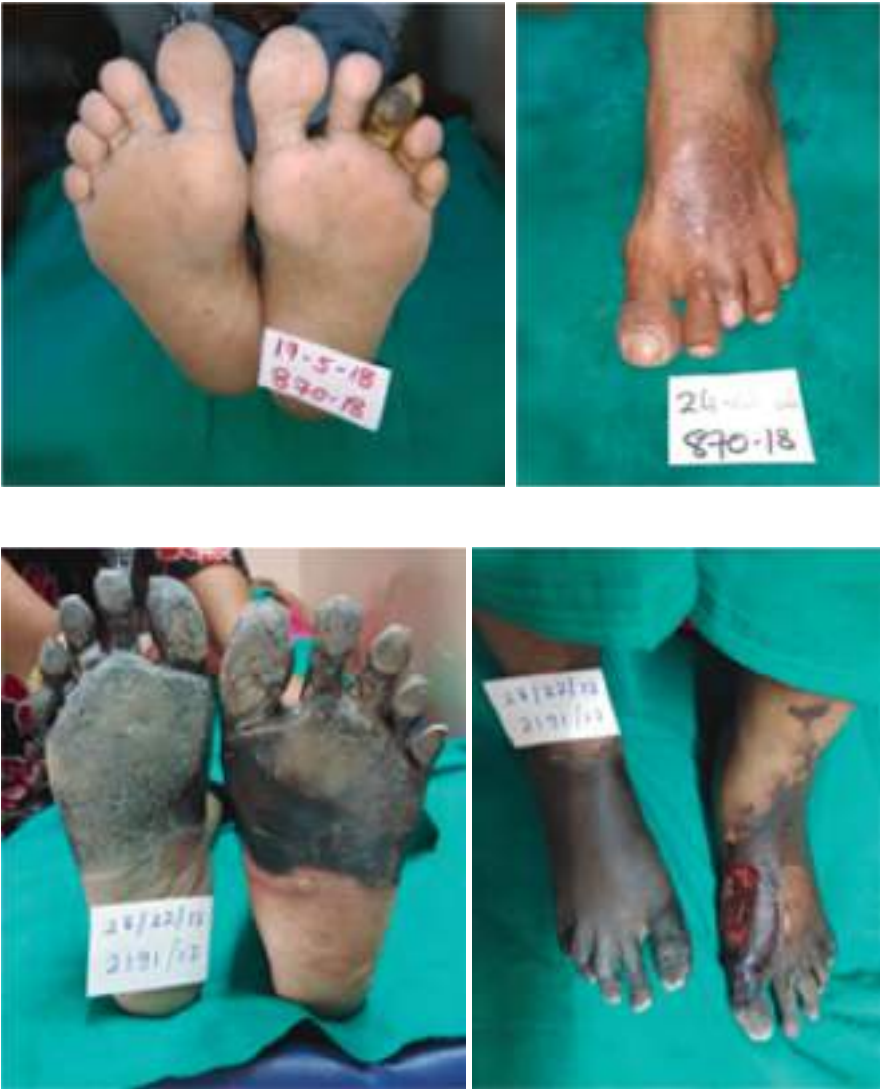Necrotic tissue, foreign material and bacteria in wound delay wound healing by producing and stimulating the promotion of abnormal metalloproteases such as collagenase and elastase. They prevent chemoattractants, growth factors and mitogens needed for healing. Bacteria inhibit healing by forming a biofilm for their own protection [2]. This biofilm is an extra cellular matrix that irreversibly binds to the wound bed and may cause resistance to therapeutic intervention.

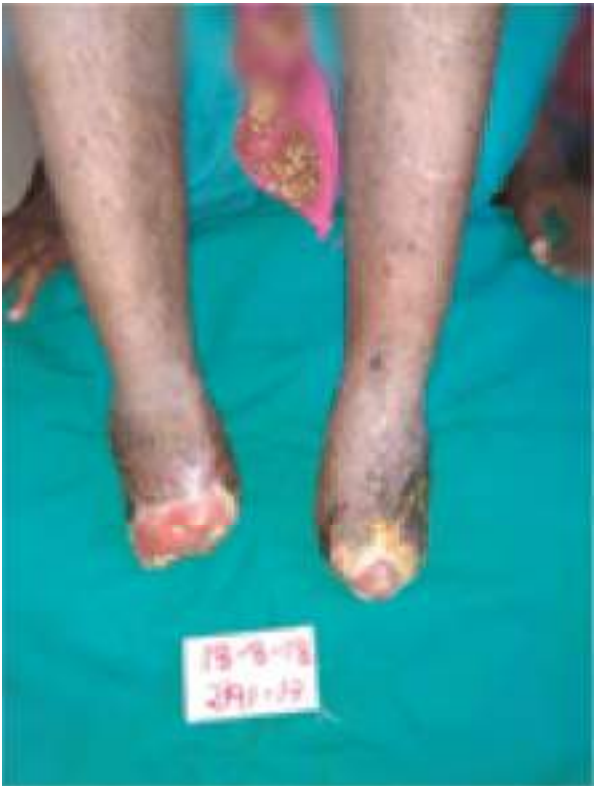The timing of debridement is decided by two factors, ischemia and infection. In gangrene in ischemic wound, the timing of revascularization and debridement is critical. In wet gangrene or abscess formation in ischemic limb, the wound should be debrided immediately, revascularization should be planned out afterwards. In dry gangrene in absence of infection, the limb should be revascularised first. If any gangrene is present in ischemic limb, after revascularization, we should closely observe for evidence of new tissue growth underneath the eschar. If there is evidence of new tissue growth, then we should observe the gangrene till it falls off or converts into

wet gangrene. If there is no evidence of new tissue growth or healing, then it should be operated. It takes a few days to four weeks for effect of revascularization of the foot after an endovascular procedure [3, 4].

Surgical debridement is indicated in the presence of restored circulation. Even when tissue perfusion appears adequate revascularization often provides the necessary substrate for wound healing. Some wounds, however, fail to heal [5]. The effectiveness and post revascularization improvement in circulation depends on which type of vascular procedure is performed. In surgical bypass, it is quicker as compared to endovascular procedure. To avoid debridement of potentially viable tissue during this time, debridement should be delayed. If dry gangrene becomes wet before the adequate revascularization, the gangrene should be debrided or operated.







Auto amputation with conservative treatment in PVD

Debridement is a procedure which should be done judiciously. Undue debridement may even traumatize the tissue. An inexperienced person may damage healthy epithelium and healthy granulation tissue.

Types of debridements

S. no.	Types	Sub types
1	Mechanical debridement	(a) Wet to dry (b) Hydrotherapy or whirlpool (c) Pulsed lavage (d) Jetforce/Largo/Florida (e) Ultra sonic therapy
2	Chemical debridement	(a) Enzymes (b) Dakin's solution (c) Eusole
3	Biological debridement	(a) Maggots therapy
4	Surgical debridement/sharp debridement	
5	Autolytic debridement	

Mechanical Debridement

Wet to Dry Dressing

Wet to dry dressing is a type of mechanical debridement. Wet to dry dressings have been the conventional treatment for debridement for decades. This method removes necrotic tissue and absorbs small amount of exudates but the exposed healthy tissue in wound might be damaged. It needs frequent change of dressings 2–3 times in a day. It is simple and inexpensive.

Whirlpool or Hydrotherapy

Hydrotherapy, or whirlpool, is one of the oldest adjuvant therapies still in use today. Although originally used by physical therapists in the treatment of pain it quickly found a place in wound management. Burns patients, in need of extensive debridement, were immersed in the Hubbard tank, a full body whirlpool. This quickly led to the development and institution of smaller extremity tanks

Patients with crush injuries, venous stasis, pyoderma gangrenosum, arterial insufficiency, animal bites and occasionally diabetes mellitus are often not neuropathic and therefore have very sensitive wounds. This makes dressing changes quite painful and psychologically distressing. The whirlpool allows the dressings to be soaked slowly and gently. Secondly the warmth of the water, generally 35.5–39 °C, promotes increased circulation in the wound surface

Functions of Whirlpool

Whirlpool was initially reserved as a method of debridement for patients suffering from burns. Today, whirlpool is used much more extensively and serves a variety of purposes, such as:

- It helps to remove debris and surface bacteria and contamination
- It decreases wound pain and fever
- It helps to remove dressing that have adhered to the wound bed

How to Use Whirlpool

There are two main types of whirlpool, immersion and showering. In immersion technique, the body part is kept in a chamber called Hubbard Tank. In showering technique, the affected area is positioned over the empty whirlpool receptacle and the wound is sprayed with water at a temperature of 92–98 °F. Usually 10–20 min of whirlpool therapy is required, but longer therapy is given if there is hardened necrotic tissue and shorter therapy is given if adherent tissue is soft or the wound bed is very fragile [6].

Whirlpool for foot debridement (Courtesy: Therapeuticmodalities-Accessphysiotherapy.mhmedical.com)



Use

It is used for removal of gross contaminants and toxic debris, diluting bacterial content, to increase local circulation. In painful wounds it helps to remove dressing without pain. It also helps to reduce body temperature, and to accelerate healing

Disadvantages

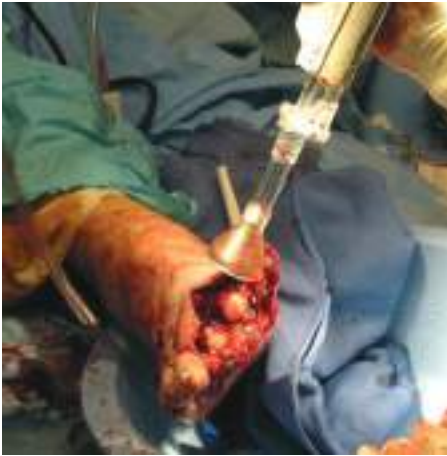Disadvantages include the possibility of wound overhydration and maceration of the periwound skin. There is also the risk of cross-contamination unless strict guidelines are followed for cleaning of the whirlpool tub and equipment. Whirlpool therapy is expensive in terms of personal time and costs associated with set up, cleaning and maintenance

Adverse Effects of Whirlpool

There is a possibility of *Pseudomonas aeruginosa* infection in treatment group, damage to granulation tissue, maceration of wound and surrounding tissue. Venous hypertension and vascular congestion are observed in venous ulcer patients [7, 8].

Pulsed Lavage or Pusatile Jet Lavage

It is a form of mechanical hydrotherapy that uses a pressurized, pulsed solution to irrigate and debride wounds of necrotic tissue. High pressure irrigation is irrigation of the necrotic wound with fluid at 8–10 pounds per square in. (psi) [9–11]. It can be done with 35 ml syringe and 19 k angiocatheter, but nowadays it is replaced by pulsed lavage. In most cases, suction is used with pulsed lavage to remove both wound debris and irrigation solution. The advantage of pulsed lavage over whirlpool is shorter treatment time, reduced cost and less stress to patients, and lower risk of cross contamination.



Pulsed lavage (Courtesy: medicalexpo.com)

Uses

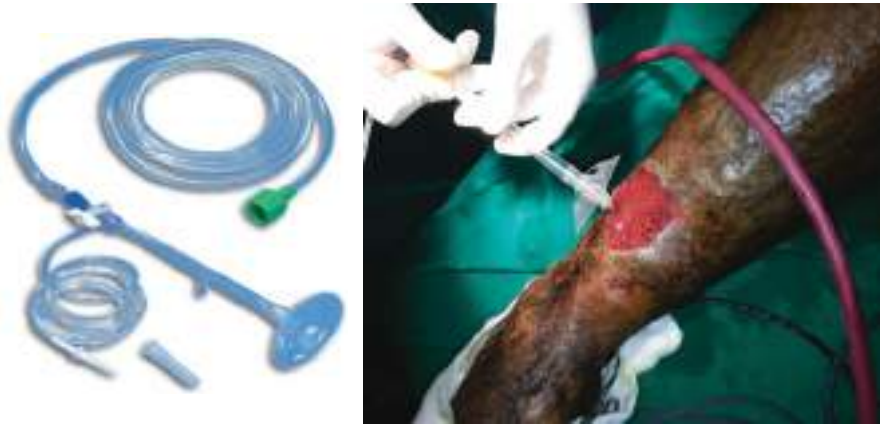Pulsed lavage is indicated for cleaning and debriding wounds due to PVD, venous stasis, diabetes, pressure sores, etc. [12].

Contraindications

It is not to be used near exposed arteries, tendons, nerves, capsules, cavities, fascial wounds recent grafts and on actively bleeding wounds. Care should be taken in insensate patients and in patients with tunneling wounds and in patients who are on anticoagulants. Pulsed lavage is not suitable for extensive wounds [13–15].

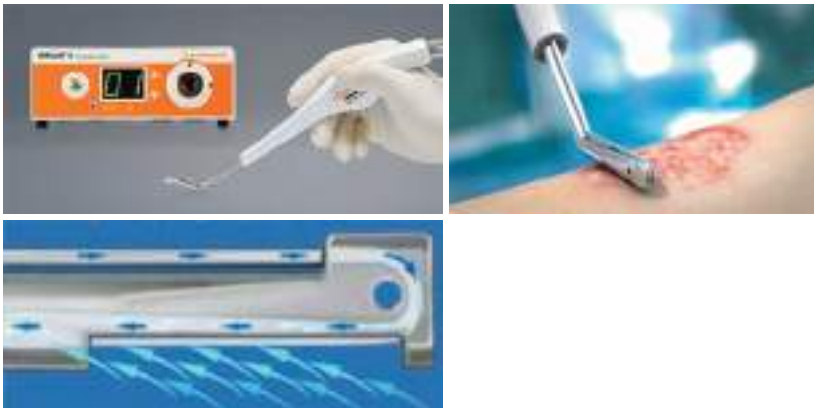Jetforce

Jetforce is a type of hydrotherapy in which disposable cannula, saline and oxygen is used (Israel). A triple nozzle device is unique, simple and most efficient. It uses a focused stream of water droplets mixed with oxygen. The jet stream creates desensitizing effect with minimal of pain. The micro drops created by jetforce are between 5 and 100 μm and are accelerated up to 200 m/s. Hence the pressure created on the wound is 15 PSI. Jet force is ideal for wounds which are difficult to debride.



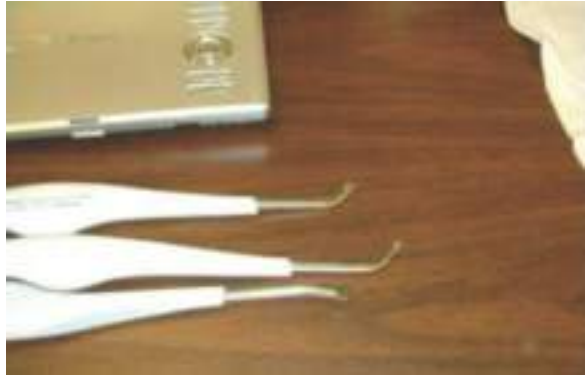Jetforce (Courtesy: parjournal.net)

Recently available is a hydrosurgical debrider that uses a water jet with up to 15,000 psi pressure to debride tissue. The ventury effect caused by this high pressure water jet sucks tissue into the stream of water, thus separating it from underlying tissue [16].



Varsajet

Probes of Versa Jet
(Courtesy: smith and
nephew.com)



Other devices: Versajet/Largo/Florida:

Ultrasonic Therapy

Ultrasonic debridement is discussed with ultrasonic wound therapy in other chapter.

Chemical Debriders

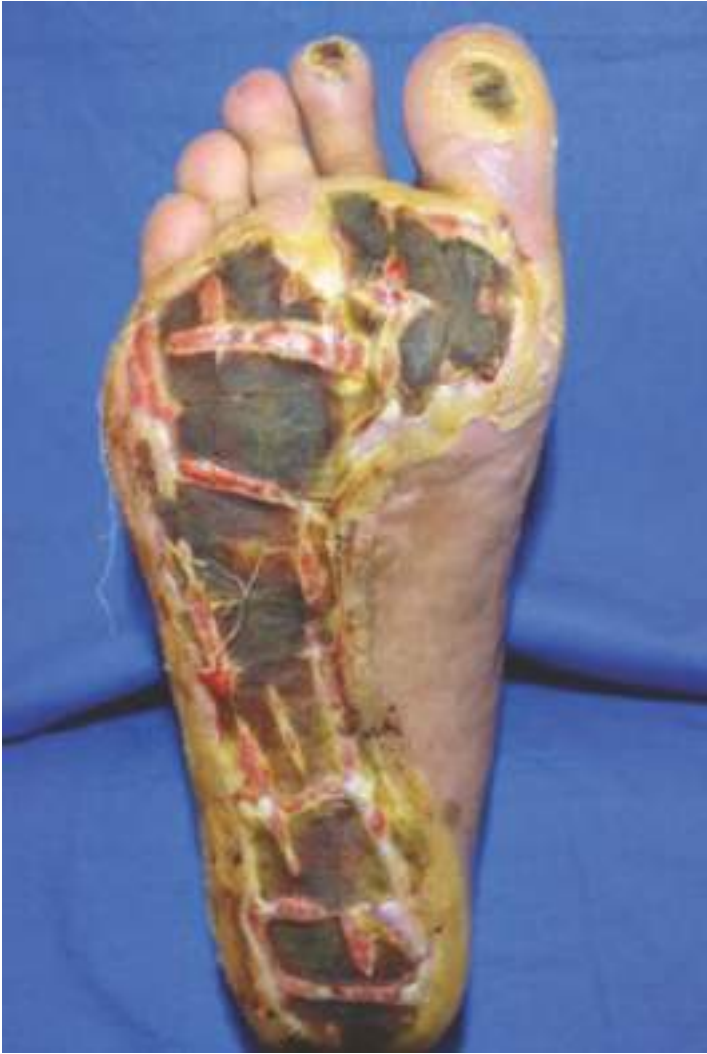Chemical debridement is done with the help of

1. Enzymes
2. Dakin's solution
3. Eusole

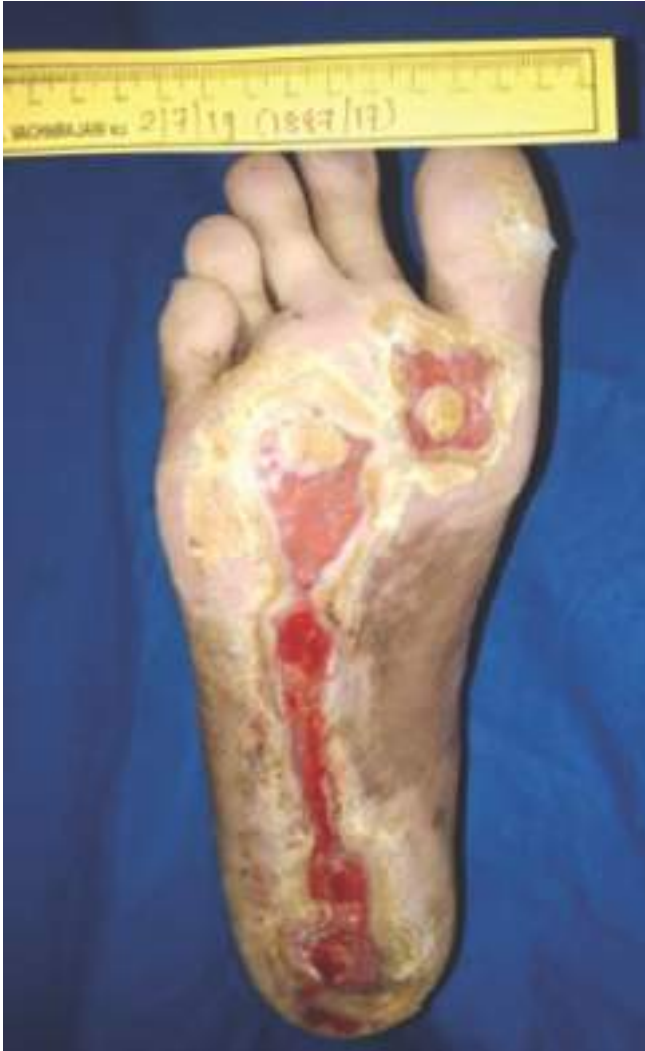Enzymes

There are many types of enzymes which work as chemical debrider. Commercially available enzymes include collagenase, papain/urea and fibrinolysin and deoxy-ribonuclease combination. Enzymatic debriders work on collagen, fibrin, elastin, nucleoprotein. Enzymes that act on necrotic tissue are proteolytics, fibrinolytics and collagenase.

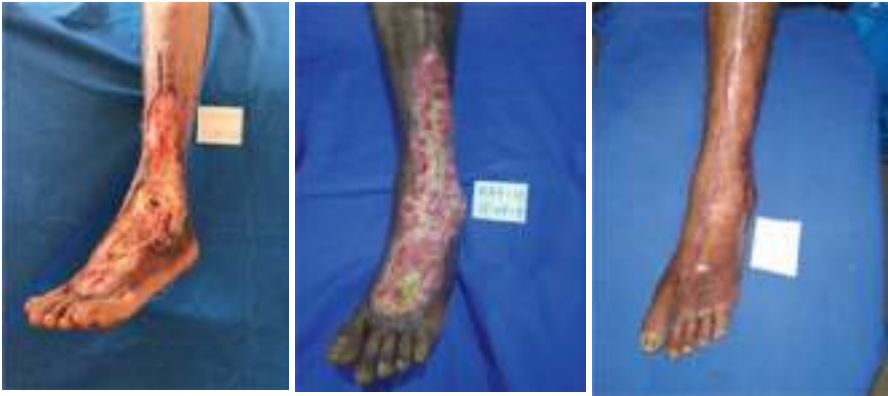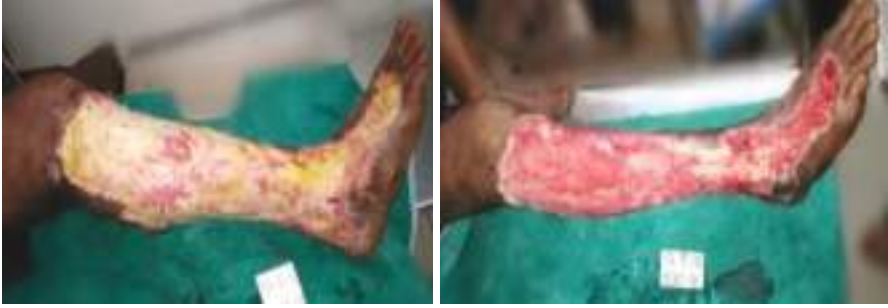
Enzymatic debriders work synergistically with endogenous enzymes. Enzymes do not affect a thick dry eschar which must be surgically excised.



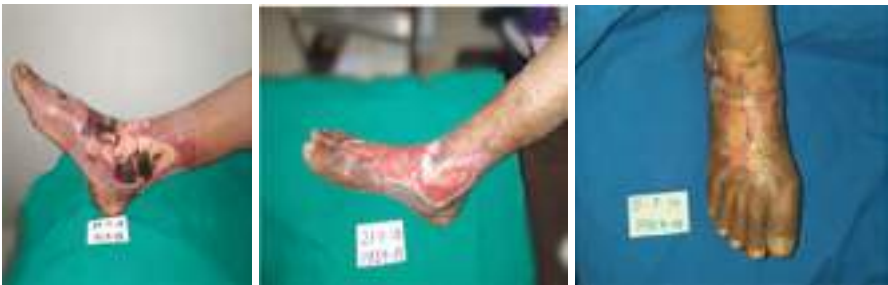Eschar should be crosshatched before applying chemical debrider. After cross hatching, eschar separation by chemical debridement and appearance of granulation tissue.



Chemical debrider disrupts or digests devitalized extracellular material present in the wound. Dry eschar should be cross hatched to allow the enzymatic debriders to penetrate below the eschar. Dressings may be changed at least 2 times in a day. If chemical debrider is used inadvertently sepsis gets exaggerated. Urea is a chemical that denatures non viable proteins which then become more susceptible to enzymatic debridement. Urea increases proteolytic effect of papain by disrupting the hydrogen bonds and reduces the strength of disulphide bridges. Hydrogen peroxide and heavy metals like silver, lead, mercury inactivate papain.



Chemical debrider can help to remove slough



Examples: Salutyl, Debridace, Elace, Santlyn.

Dakin's solution

Dakin's solution is a type of hypochlorite solution. It is made from bleach that has been diluted and treated to decrease irritation. Chlorine, the active ingredient is a strong antiseptic and kills most forms of bacteria and viruses.

It can be sprayed or applied on wounds. It can be applied once or twice a day. Surrounding healthy skin can be protected by petroleum jelly to prevent irritation.

Redness, irritation, swelling and pain are side effects. As a debriding agent it is non selective because of its cytotoxic effect. It can also be used before and after surgery to prevent surgical wound infections.

Eusole

Edinburgh university solution is antiseptic as well as debriding agent. It is an oxidizing agent and acts against bacteria and viruses. It needs to be prepared fresh daily. 1 litre of eusole is prepared by adding 12.5 g of chlorinated lime and 12.5 g of boric acid. After preparation solution needs to settle down and supernatant clear fluid is applied on the wound. If applied in more quantity, there may be maceration of the surrounding skin. Eusole needs to be prepared in the hospital as a fresh solution and difficult to standardize. Now super oxidized solutions are available in standard and uniform strength in the market. Therefore eusole is not regularly used.

Biological Debridement

Maggots Therapy

Myiasis is a condition caused by infestation by fly larvae which feed on and therefore destroy the dead and living tissue of a living host. But here we are considering the use of maggots in treatment of a wound. The fly is classified according to its preferred feeding habit.

- **Obligate parasite, it feeds on living tissue**
- **Facultative parasite, it feeds on decaying tissue**

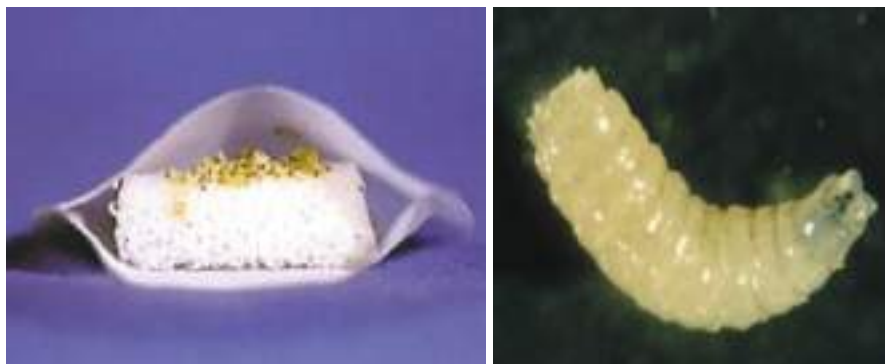Lucilia sericata is a member of the family Calliphoridae [17], they are facultative parasites so they are used in maggot therapy. These have been chosen for the following reasons.

1. They develop rapidly and therefore act quickly.
2. They do not invade the internal organs.
3. Easy to rear and sterilize.

The maggots do not lay eggs, but it is the adult fly which lays eggs.

Application

Maggots can directly be applied on the wound. It is also available in the form of a biobag prepared from gauze, which can be applied on wound. Maggots are generally left in place for three days by that time generally they are fully grown.



Courtesy:woundedekkars.nl

Maggots and biobag
(Courtesy:woundedekkars.
nl)



Maggots can be kept for a longer period also. They can be applied under a transparent dressing so that larval activity can be monitored without removing the primary dressing. In necrotic wounds, after the necrotic tissue is debrided, one can stop maggot therapy.

A small wound may require only one application, but large wounds with abundant necrotic tissue may require multiple applications. It is estimated that 30 maggots consume 1 gm of necrotic tissue and bacteria per day. After complete debridement in chronic or indolent ulcer, if maggots are applied they prevent further infection and may actually promote healing.

It takes about 10–14 days for a newly hatched maggot to complete its life cycle and turn into fly, so dressing needs to be changed every 3–4 days. The larvae like somewhat dry area to pupate, so they will attempt to leave the moist environment in order to do so.

Maggots require sufficient air to breathe, so airtight compression bandage is not advisable. After the maggots are applied on the wound, there is no necessity to moisten the wound daily. In first 24 hours young maggots are quite delicate and susceptible to desiccation, but when they grow, they become much more resistant to dehydration.

Usually maggot therapy is painless [18]. In some patients it may relieve pain because of infection control. In PVD (Peripheral Vascular Disease) patients on the second or third day, there may be more pain probably associated with change in pH. Normal activity can be done after application of maggots, care being taken not to keep the affected area very close to heat.

Maggots are not affected by the concurrent administration of most systemic antibiotics [19], but they don't survive well in patients receiving topical or systemic metronidazole. Maggots are not affected by x-ray also. Residue of some hydrogel dressings have adverse effect upon maggots development. There are no side effects of maggot therapy, but in ischemic leg ulcers, it may aggravate pain.

Mechanism of action

S. no.	How maggots work
1.	Chemical debridement
2.	Removal of bacteria
3.	Change in pH of the wound
4.	Release of growth factor like chemicals
5.	Ingests microorganisms

The main action is chemical debridement. The sterile larvae secrete proteolytic enzymes including collagenase and that breaks down necrotic tissue. It is also believed that larvae ingest micro organisms which are then destroyed. Maggots don't destroy healthy tissue because proteolytic enzymes produced by larvae are inactivated by enzyme inhibitors present in healthy tissue.

It is proved that bacteria are eliminated by maggot secretion in the wound. In a study by using live maggots added to a suspension of staphylococcus aureus, the result showed a gradual reduction of bacteria to nil. While the control group staphylococcal colony increased from 5 to 22 over the same time [20]. Published data also suggests that they are even effective against antibiotic-resistant strains such as methicillin-resistant staphylococcus aureus [21, 22].

It has been shown that bacteria which are not killed by maggots are ingested by feeding larvae and then they are killed as they pass through the insect's gut [23–25]. Wound pH changes from acidic to alkaline in presence of maggots. It is documented that bactericidal effect is due to raised wound pH.

It has also been demonstrated that maggots produce a natural growth factor that stimulates fibroblast growth and also secrete a natural antibiotic-like molecule that inhibits the growth of many microorganisms [26].

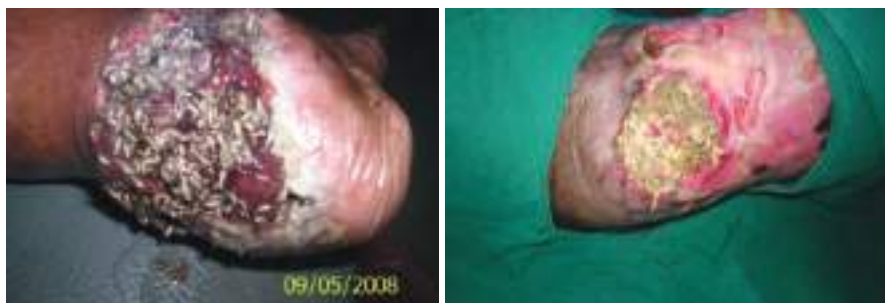Contra indication for Use of Maggot Therapy

Maggot therapy should not be used in fistula wounds, wounds connected to body cavity and internal organs, and rapidly advancing tissue necrosis.

Treatment of Maggots Infected Wound

Many patients come with maggots infected wounds. Here we need to remove maggots rather than applying maggots. For that we need to rinse the wound with warm, soapy water to wash away maggots on the surface. Then we should pour hydrogen peroxide and allow it to work for sometimes. This also kills maggots. Then we soak a gauze in turpentine oil and apply on the wound, this will draw out and kill maggots that are burrowed deeply into the wound.

Keep the turpentine soaked bandage on the wound up to 1 hour. This can be repeated till the maggots are totally cleaned. Maggots may take 2–3 days to get completely eradicated.



In addition to turpentine 50% dextrose and 2–5% oil extracts of betel leaf (piper betel) are also effective in killing larvae.

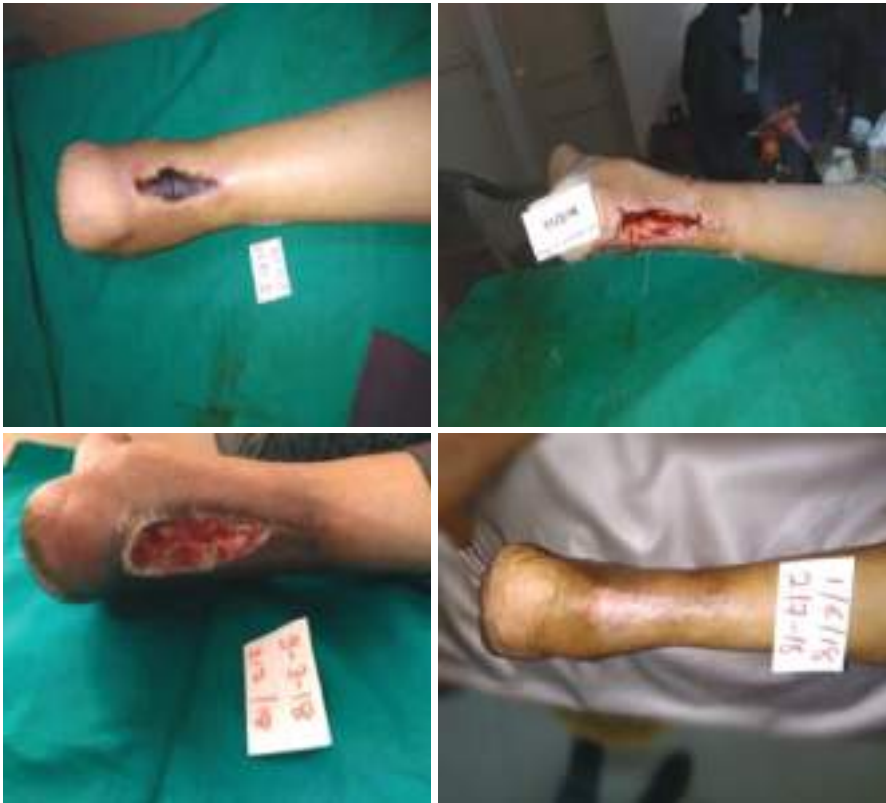Autolytic Debridement

This is as such a natural way of debridement. All moisturizing, absorbent, and hydrocolloid dressings help nature to perform autolytic debridement. Autogenous enzymes with phagocytic effects of macrophages clean the wound [27–29].

Bacteria in the wound also produce proteases such as hyaluronidase which causes clot lysis and debridement. Aged patients have decreased amount of endogenous proteases and so there is insufficient debridement. Autolytic debridement is relatively slow and painless. We should not rely upon autolytic debridement in infected wounds and anaerobic infections.

Surgical Debridement/Sharp Debridement

Surgical debridement is defined as extensive removal of tissue (bone/muscle) by a skilled surgeon in operation theater with or without anesthesia. “Shave therapy” is complete excision of ulcer with surrounding lypodermatosclerosis [30–33]. Debridement done at bed side or at patient’s home or in O.P.D. is called sharp debridement.



Sharp/surgical debridement for wound with eschar

Comments

In wound management debridement plays a crucial role. Debridement is a complete science. It requires expertise to know when to debride, how much to debride and when not to debride. Simple gauze, scoop and water pressure devices are good debriders. Surgical debridement requires surgical skill. Without assessing vascularity doing debridement is not justified. Vascularity plays a major role in deciding time and extent of debridement. Many a times proper surgical debridement is required before the chemical debrider can work. For instance, an adherent thick eschar should be cross hatched for chemical debriders to go under the eschar and work. Chemical debridement is useful in painful wounds where patient doesn't allow touching the wound.

Biofilm and its management

Biofilms are complex community of micro organisms embedded in an extracellular matrix of protein, lipids, and polysaccharides. This film is adherent to the wound or surface. The colonies contain bacteria as well as fungi.

In any chronic wound bacteria are thought to be floating and free, which is known as planktonic phenotype. Now it is thought that these organisms sometimes form a film known as a biofilm. These organisms are known as biofilm phenotype. The biofilm has multiple layers of organisms and they are capable of sending messages to each other by a process known as quantum sensing. They can alter phenotype and genotype through messages sent to each other. Gene modulation is also seen which can make organisms to live in oxygen deficient site and can also become dormant.

Over 60% of chronic wounds and 6% of acute wounds have biofilms, the biofilm decreases the drug penetrations. It also prevents elimination of infection and granulation tissue formation, maintains the inflammatory phase of wound healing and impairs migration and proliferation of keratinocytes, reducing oxygen supply to the wound.

In the early stage the organisms in the biofilms are biologically active and the attachment is reversible but if the biofilm is not destroyed in the first 24 h, the film becomes more permanently attached to the surface. The duration of the biofilm is very important, it becomes more and more resistant for removal if time goes on.

Biofilm protects the organisms by mechanical means and with a chemical barrier. The change of phenotype and genotype interferes with culture and sensitivity results. After debridement within 24 h biofilm can be reformed.

Clinically a biofilm is translucent, has some shiny patches of yellow-green substance. Biofilm can be identified by scanning electron microscopy, different molecular modalities and with the help of confocal microscopy.

Biofilm can be removed by debridement and/or vigorous cleaning and local antimicrobials also can prevent biofilm formation. Manuka honey is effective against

biofilm. Lactoferrin is a chelating protein. It destabilizes the cell wall of organisms in the biofilm. Lactoferrin and zylitol combination is effective against *Pseudomonas aeruginosa* biofilm. Octenidine dihydrochloride is also being tested for their effect on biofilms. Possibility is being explored for bacteriophages (viruses which can infect bacteria). Organisms in the biofilm are prevented from communicating with each other with the help of quantum sensing inhibitors.

References

1. Falanga V. Growth factors and chronic wounds: the need to understand the microenvironment. *J Dermatol*. 1992;19:667.
2. Edwards R, Harding KG. Bacteria and wound healing. *Curt Opin Inf Dis*. 2004;17:19.
3. Armstrong DA. Clinical care of diabetic foot. Chapter 7. 2005.
4. Caselli A, Latini V, Lapenna A, et al. Transcutaneous oxygen tension monitoring after successful revascularization in diabetic patients with ischemic foot ulcers. *Diabet Med*. 2005;22(4):460–5.
5. Wyss CR, Robertson C, Love SJ, et al. Relationship between transcutaneous oxygen tension, ankle blood pressure, and clinical outcome of vascular surgery in diabetic and nondiabetic patients. *Surgery*. 1987;101(1):56–62.
6. Haynes LJ, Brown MH, Handley BC. Comparison of Pulsavac and sterile whirlpool regarding the promotion of tissue granulation. *Phys Ther*. 1994;74:S4.
7. Tao H, Butler J, Luttrell T. The role of whirlpool in wound care. *J Am Coll Clin Wound Spec*. 2012;4(1):7–12.
8. Perry A, Potter P, Ostendorf W. *Clinical Nursing Skills and Techniques*. 8th ed. Elsevier Health Sciences; 2013.
9. Bohannon RW. Whirlpool versus whirlpool and rinse for removal of bacteria from a venous stasis ulcer. *J Am Phys Ther Assoc*. 1982;62:304–8.
10. Burke D, Ho C, Saucier M, Stewart G. Effects of hydrotherapy on pressure ulcer healing. *Am J Phys Med Rehabil*. 1998;77(5):394–8.
11. Gogia PP, Hurt BS, Zirn TT. Wound management with whirlpool and infrared cold laser treatment: a clinical report. *Phys Ther*. 1988;68:1239–42.
12. Luedtke-Hoffmann KA, Schafer DS. Pulsed lavage in wound cleansing. *Phys Ther*. 2000;80:292–300.
13. Hess CL, Howard MA, Attinger CE. A review of mechanical adjuncts in wound healing: hydrotherapy, ultrasound, negative pressure therapy, hyperbaric oxygen, and electrostimulation. *Ann Plastic Surg*. 2003;51(2):210–8.
14. Kloth LC, Feedar JA. Acceleration of wound healing with high voltage, monophasic, pulsed current. *Phys Ther*. 1988;68(4):503–8.
15. Gogia PP, Hurt BS, Zirn TT. Wound management with whirlpool and infrared cold laser treatment. *Phys Ther*. 1988;68(8):1239–42.
16. David G Armstrong. Clinical care of diabetic foot. Chapter 7. 2005.
17. Crosskey RW. Introduction to the Diptera. In: Lane RP, Crosskey RW, editors. *Medical insects and arachnids*. London: Chapman & Hall; 1995.
18. Evans H. A treatment of last resort. *Nurs Times*. 1997;93:62–64,65.
19. Sherman RA, Wyle FA, Thrupp L. Effects of seven antibiotics on the growth and development of *Phaenicia sericata* larvae. *J Med Entomol*. 1995;32:646–9.
20. Thomas S, Jones M. Maggots and the battle against MRSA. *Bridgend: The Surgical Material Testing Laboratory*; 2000.

21. Bexfield A, Nigam Y, Thomas S, Ratcliffe NA. Detection and partial characterisation of two antibacterial factors from the excretions/secretions of the medicinal maggot *Lucilia sericata* and their activity against methicillin-resistant *Staphylococcus aureus*. *Microbes Infect.* 2004;6:1297–304.
22. Armstrong J, Zhang L, McClellan AD. Axonal regeneration of descending and ascending spinal projection neurons in spinal cord-transected larval lamprey. *Exp Neurol.* 2003;180:156–66.
23. Lerch K, Linde HJ, Lehn N, Grifka J. Bacteria ingestion by blowfly larvae: an in vitro study. *Dermatology.* 2003;207:362–6.
24. Robinson W, Norwood VH. Destruction of pyogenic bacteria in the alimentary tract of surgical maggots implanted in infected wounds. *J Lab Clin Med.* 1934;19:581–6.
25. Mumcuoglu KY, Miller J, Mumcuoglu M, Friger M, Tarshis M. Destruction of bacteria in the digestive tract of the maggots of *Lucilia sericata*. *J Med Entomol.* 2001;38:161–6.
26. Prete P. Growth effects of *Phaenicia sericata* larval extracts on fibroblast: mechanism for wound healing by maggot therapy. *Life Sci.* 1997;60:505–10.
27. Sinclair RD, Ryan TJ. Types of chronic wounds: indications for enzymatic debridement. In: Westerhof W, Vanscheidt W, editors. *Proteolytic enzymes and wound healing*. Berlin: Springer Verlag; 1994. p. 7–21.
28. Himel H. Wound healing: focus on the chronic wound. *Wounds.* 1995;7(Suppl A):70A–7A.
29. Donati L. Surgical versus enzymatic debridement. In: Westerhof W, Vanscheidt W, editors. *Proteolytic enzymes and wound healing*. Berlin: Springer; 1994. p. 31–47.
30. Baharestani M. The clinical relevance of debridement. In: Baharestani M, Gottrup F, Vanscheidt W, editors. *The clinical relevance of debridement*. Berlin: Springer Verlag; 1999. p. 1–13.
31. Dealey C. *The care of wounds*. Oxford: Blackwell Scientific Publications; 1994.
32. Vowden KR, Vowden P. Wound debridement, Part 2: Sharp techniques. *J Wound Care.* 1999;8:291–4.
33. Doughty P. Principles of wound healing and wound management. In: Bryant RA, editor. *Acute and chronic wounds: nursing management*. St. Louis: Mosby Year book; 1992.

Abstract

Mercurochrome, acryflavin, chloroxylenol, chlorhexidine are no more used as antiseptics for dressings. Iodine preparations and silver preparations are routinely used dressing materials. Octenidine dihydrochloride, PHMB, and HOCl are good antiseptics available in the market. Antiseptics are available in liquid form, ointment and cream form, and in combination with foam and hydrocolloid dressings. Other than silver preparations, antiseptics need once or twice a day applications. Antiseptic should not be used in healthy and healing wounds.

An antiseptic is a substance which inhibits the growth and development of micro organisms. Routinely they are thought of as topical agents, for application to skin, mucus membrane and objects like furniture and instruments.

Commonly used antiseptics for cleaning of skin include chlorhexidine, iodine compounds, mercury compounds, alcohol and hydrogen peroxide. Chlorhexidine is very safe on mucous membrane, iodine in tincture form is highly effective but irritant.

Certain fungal infection of the wound does not respond to routine antiseptics. We need to treat them after histopathology and culture report.

Merbromin

It is available as 2% concentration dissolved in either ethyl alcohol or water. Merbromin is an orange mercury disodium salt. It is readily available in most countries but because of its mercury content no longer sold in Switzerland, Brazil, France, Germany, and USA.

Merbromin is synthesized by combining dibromofluorescein with mercuric acetate and sodium hydroxide or alternatively, through action of the mercuric acetate upon (or combining with) sodium dibromofluorescein. Because of its anionic character, it is chemically incompatible with acids, majority of alkaloid salts and most local anesthetics.

The best-known use of merbromin is as a topical antiseptic to treat minor wounds, burns, and scratches. It is also used in the antiseptics of the umbilical cord, neuropathic ulcers, and diabetic foot sores. When applied on a wound, it stains the wound and real color of granulation tissue is obscured.

Example: Mercurochrome, Merbromin, Mercurocol, Sodium mercurcescin, Asceptichrome,

Comments

It has been our experience that merbromin has very good effect on pseudomonas but it is nowadays not advisable to use this antiseptic. Clinical data is not available for its use and advantages in treating wounds. It is not advisable to use this antiseptic even in diabetic foot wounds.

Acriflavineum Chloride

It is in the form of orange or brown powder. It is a dye and stains the skin. It is derived from acridine. Commercial preparations are often mixture with proflavine. It was developed in 1912 by Paul EHRLICH, a German medical researcher who extensively used it during the first world war. Proflavine cream is an acridine derivative and acts as a slow-acting antiseptic. The acridine derivatives are bacteriostatic against many gram-positive bacteria, but less effective against gram-negative bacteria. Other acridine derivatives include acriflavine, but their use has been superseded by other antiseptics or suitable antibacterials. Antiseptic solutions such as proflavine and acriflavine, are used to cleanse or irrigate wounds, or are incorporated into dressings to allow for a longer contact time with the wound, giving a prolonged antibacterial effect.

Example: Acriflavin.

Comments

As acryflavineum chloride is bacteriostatic and standardized solutions are not available in the market, it is not advisable to use this antiseptic as a routine dressing material. It stains the wound yellow and original color of wound is not seen.

Chloroxylenol

Chloroxylenol, also known as para-chloro-meta-xylenol (**PCMX**), is an [antiseptic](#) and [disinfectant](#) which is used for [skin disinfection](#) and cleaning [surgical instruments](#) [1, 2]. It is also used within a number of household disinfectants and [wound cleaner](#). It is less effective than some other available agents. It is available as a liquid.

Side effects are generally few but can include skin irritation. It may be used after mixing with water or [alcohol](#). Chloroxylenol was first made in 1927. It is on the World Health Organization's list of essential medicines, the most effective and safe medicines needed in a [health system](#). It is sold in a number of formulations and under a number of brand names.

Preparations

It is available in a mixture of Chloroxylenol, pine oil, isopropanol, castor oil soap and water. It is most effective against gram positive bacteria. It works by disruption of the cell wall and stopping the function of enzymes. It is poisonous when swallowed and even when it is unintentionally breathed in. It comprises 4.8% dettol's total admixture and the rest made up of pine oil, isopropanol, castor oil, soap and water.

Chloroxylenol is also available in combination with Chloroxylenol, Benzocaine and Hydrocortisone, and chloroxylenol, hydrocortisone and pramoxine

Examples: Dettol, Zeasorb, Foille, Zolene HC.

Chlorhexidin

It is an antiseptic which is commercially available in combination with cetrimide. It is available as liquid, gel, wound wash, spray, dual action gel (with anesthetic gel). It is used to sterilize instruments and for skin preparation before surgery. It is also used as 1% and 3% solution for cleaning road side accidental wounds.

It is not effective in biofilms, but is effective in presence of blood and serum.

Example: Savlon

Comments

Patients use the concentrated solution available in market which is wrong. So many patients develop dermatitis and allergic reactions around the wound. Diluted solution should better be used to clean surgical sites or wounds rather than applying on a wound as a dressing material.

Hydrogen Peroxide

It is a chemical compound with the formula H_2O_2 . Hydrogen peroxide is the simplest peroxidase. It is unstable and slowly decomposes in the presence of base or a catalyst. Because of its instability, hydrogen peroxide is typically stored with a stabilizer in a weakly acidic solution. Hydrogen peroxide is found in biological systems including human body. Enzymes that use or decompose hydrogen peroxide are classified as [peroxidases](#). In its pure form it is pale blue, clear liquid. It is used as an oxidizer bleaching agent and as an antiseptic.

Hydrogen peroxide is formed in human and animals as a short-lived product in biochemical processes and is [toxic to cells](#). The toxicity is due to oxidation of [proteins](#), [membrane lipids](#) and [DNA](#) by the peroxide ions. The class of biological [enzymes](#) called SOD ([superoxide dismutase](#)) is developed in nearly all living cells as an important [antioxidant](#) agent. They promote the [disproportionation](#) of [superoxide](#) into [oxygen](#) and hydrogen peroxide, which is then rapidly decomposed by the enzyme [catalase](#) to oxygen and water.

H_2O_2 is available for wound cleaning and can be used for sterilization of various surfaces, including surgical tools and may be used as vapor for room sterilization.

It demonstrates broad spectrum efficacy against viruses, bacteria, yeasts, and bacterial spores. In general, greater activity is seen against gram positive and gram negative bacteria.

It is now thought to inhibit healing and to induce scarring because it destroys newly formed skin cells. Only a very low concentration of H_2O_2 can induce healing, and only if not repeatedly applied.

Chemistry of Hydrogen Peroxide

Hydrogen peroxide is most commonly available as a solution in water. For consumers, it is usually available from pharmacies at 3 and 6% w/v concentrations. The concentrations are sometimes described in terms of the volume of oxygen gas generated; one milliliter of a 20-volume solution generates twenty milliliters of oxygen gas when completely decomposed. For laboratory use, 30%w/v solutions are most common. Commercial grades from 70% w/v to 98%w/v are also available, but due to the potential of solutions of more than 68% w/v hydrogen peroxide to be converted entirely to steam and oxygen (with the temperature of the steam increasing as the concentration increases above 68%w/v) these grades are potentially far more hazardous and require special care in dedicated storage areas.

Hydrogen peroxide occurs in surface water, groundwater and in the [atmosphere](#). It forms upon illumination or natural [catalytic](#) action by substances contained in [water](#). Sea water contains 0.5–14 $\mu\text{g/L}$ of hydrogen peroxide, freshwater contains 1–30 $\mu\text{g/L}$ and air contains 0.1–1 parts per billion.

Comments

We need to restrict the use of hydrogen peroxide. It is thought that it is cytotoxic and affects the newly growing granulation and epithelium and fibroblast. Its basic use is debridement though it is antiseptic also. The nascent oxygen released creates a cleavage between healthy tissue and the slough. It is an excellent desloughing agent, but should be used only occasionally and not as a day to day dressing material. Especially in diabetic foot wounds it is not recommended to use it.

Benzoin Resin

It is a pungent solution of benzoin resin in ethanol. A similar preparation is available known as Fria's balsam. It is prepared by the maceration of a mixture of benzoin, aloe in the form of a moderately coarse powder, storax and tolu balsam in strong alcohol.

It is often applied to skin under adhesive bandage. It protects the skin from allergy to the adhesive and makes the bandage adhere together. It is also used by athletes for its reputation of toughening skin. Orthopedic surgeons often apply it under a cast, because it protects the skin and diminishes itching.

It can be applied to skin fissures, canker sores and fever blister as an antiseptic. It is also used in alternative medicine and is inhaled in steam as a treatment for various conditions including asthma, bronchitis and common cold but there is no medical evidence to support its use or effectiveness for these purposes.

It is used in the U.S. military to treat [blisters](#). A common treatment utilized by medics in the U.S. army is to drain the fluid from a blister and then inject enough compound tincture of benzoin into the void to glue the blister to the underlying skin, to serve as a local antiseptic, and to prevent further abrasion or loss of skin. It creates extreme burning sensation that will be experienced for several moments when the tincture is applied [\[3, 4\]](#).

Example: Tincture of benzoin.

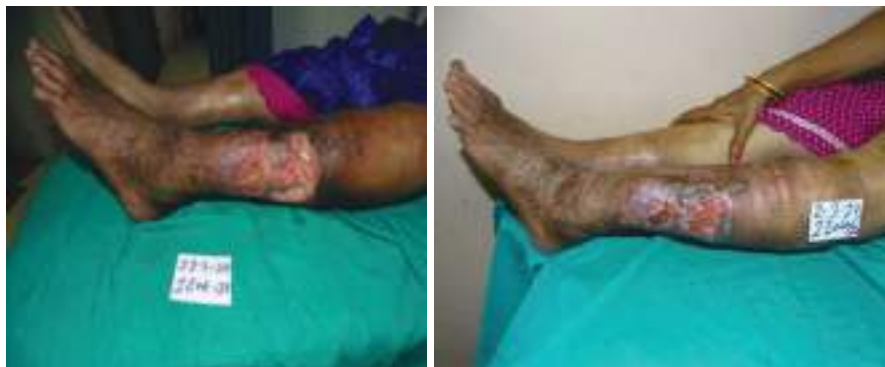Comments

As such tincture of benzoine is not used as a dressing material nowadays. It can be used to seal small stitched wound and on abrasions of recent origin. It is highly irritant and should not be applied on wounds. The description here is to complete the list of medicines which were and which can be used as dressing materials. I personally don't recommend to use it on wounds.

Iodine

Iodine is one of the oldest established antiseptics [5]. Iodine is available as povidone iodine and cadexomer iodine. The original iodine is not used nowadays due to its local pain, irritation and allergic properties. Povidone iodine is also known as iodo povidine. It is also known as the “Tamed” iodine and it was introduced 40 years ago [6]. Cadexomer iodine was introduced 25 years ago, it has a high absorptive capacity. Iodine is slowly released from it. Cadexomer preparation contains (in one gram) cadexomer iodine 500 mg (cadexomer 491 mg, iodine 9 mg) + poloxamer 407, polyethylene glycol 400, polyethylene glycol 4000. Cadexomer is available in paste form in different concentration.

Cadexomer iodine is non toxic to human fibroblasts and is economical. A review of cadexomer iodine in venous ulcer, it was found that it helped reduce the wound exudates with better healing than in controlled group [7]. A large study of leg ulcer (n = 153) found better healing with cadexomer iodine as compared to hydrocolloid and paraffin dressings [8]. There is a report of iodine induced hyperthyroidism in elderly patient [9]. Increased level of serum iodine is found in patient with topical iodine application in whom there is impaired renal function. Iodine takes 2 min contact time for release of free iodine and its antiseptic activity.



Cadexomer iodine dressing

Example: Cadomer, Iodosorb, Wokadine, Betadine.

Mechanism of Action

Iodine preparations are wide spectrum microbicidal, they oxidise cell constituents, iodinate proteins and inactivate them. Iodine has cytotoxicity, but cadexomer iodine is not harmful to human cells, this is because of slow release of iodine. Cadexomer iodine has also desloughing and moisturizing capacity. It has been studied in both

venous ulcers [10] and diabetic foot ulcers [11]. It is effective against gram positive and gram negative bacilli, fungi, tubercle bacilli, viruses and spores. It is available in granule form in an ointment from which iodine is gradually released. After the iodine is utilized color becomes white.

Povidone iodine is not effective against biofilms and is inactive in presence of blood and serum but cadexomer iodine works in both.

Caution in using iodine preparations

1. Toxicity may occur if applied in large quantity or for prolonged periods
2. It should be used with caution in renal impairment and thyroid disorder patients.
3. It should be used with caution in children and in serious extensive burns.
4. It should not be used for longer than 1 week, as it may cause metabolic acidosis.
5. Povidone iodine interacts with starch in the dressing and bandage becomes violet.
6. 10% iodine should not be used as it is toxic to fibroblasts, so for wound irrigation, it has to be diluted ten times with normal saline.

Comments


Since so many years iodine preparations are used for wound dressings. It is advisable to use 5% solution or still diluted solution for wound irrigation and dressing. The effect of iodine takes 2 min to work. Free iodine is released and then only it has antiseptic effect. The antiseptic effect lasts till it is moist when it is dried out it is not effective. The dressing needs to be changed every day. Iodine is also thought to be having cytotoxic effect against fibroblast. Cadexomer iodine has sustained effect, it also has absorptive capacity less frequent change of dressing is possible with cadexomer iodine. It is a drug of choice for venous stasis ulcer. In large wounds iodine preparation should not be used for a longer time.

Silver

Silver is a topical antiseptic and many forms of silver release products like films, foams, hydrocolloids and hydrofiber dressings are available. Use of silver on chronic wounds is reported even in seventeenth century [12].

Silver is available in dressings in different forms.

- (a) Elemental ions: - Silver metal, Nanocrystalline silver.
- (b) Inorganic compounds: -Silver Oxide, Silver phosphate, Silver chloride, Silver sulphate, Silver calcium sodium phosphate.
- (c) Organic complex: Silver alginate, Silver carboxy methyl cellulose.



Silver dressing (Courtesy: smith and nephew.com)

Elemental silver is a very small crystal that is about 10–100 nm in diameter.

In metallic form, silver is non reactive and cannot kill bacteria. To become bactericidal, silver atoms must lose an electron and become positively charged silver ions.

Mechanism of Action

Silver ions are highly reactive and affect multiple sites within the bacterial cells. Silver reduces bacterial adhesions and destabilizes biofilm matrix, kills bacteria within the matrix, and also increases the susceptibility of bacteria to antibiotics and kills bacteria by damage to cell wall, cell membranes, respiratory enzymes and ribonucleoproteins. It is effective against yeast, fungi, viruses, and MRSA and VRSA [13]. The basic mechanism of action of silver is as follows:

- (a) It interferes with electron transportation
- (b) It binds to bacterial DNA
- (c) It has effect on cell membrane interaction causing structural damage.

Silver has an anti inflammatory effect as well as neovascularization effect. Only a small quantity of silver presented at wound site is required for antimicrobial effect, the remaining binds to proteins in wound debris and very little is systemically absorbed.

Silver also has the capacity to suppress inflammatory cytokines and induce death of inflammatory cells and need wound moisture for releasing the active silver ions [14]. Silver dressings have an important role in treatment of exudative wounds, but their value is not determined in the presence of slough and necrosis.

Even if absorbed systemically, silver is excreted via biliary route in faeces. Some is also excreted in urine. It is not absorbed in the central or peripheral nervous system. The total amount of silver in dressings varies considerably. The amount of

silver delivered in the wound does not correlate with the amount of silver content in the dressing. In some laboratory experiments, very low concentrations (e.g. 1 part per million (1 ppm)) of silver ions have been shown to be effective against bacteria. It is difficult to judge how silver content and availability of silver at wound site can be correlated.

Elemental silver ionizes even in air, but ionizes more readily when exposed to an aqueous environment. Slow release of silver is advisable to avoid bolus dosing and minimize systemic toxicity. It is suggested that for surface wound, a sustained release silver dressing is more useful than iodine which is rapidly inactivated.

Silver component of a dressing may be in the following different ways:

- (a) As a coating on one or both the surfaces of a dressing (elemental or nanocrystalline).
- (b) In the form of liquid or cream for direct application over the wound.
- (c) Within the structure of a dressing (foam, silver alginate).
- (d) As a combination of above.

Silver on the Surface

The nanocrystalline coating of silver kills a broad spectrum of bacteria in as little as 30 min. It works against 150 pathogens up to 3–5 days. The dressing contains three layers, absorbent layer (nylon or polyester non woven core) is covered by silver coated low adherent polyethylene net.

Example: Acticoat.

Cream or Liquid Preparations

Silver in the form of silversulfadiazine (1% w/w) chlorhexidine gluconate (0.2% w/w) and recombinant human epidermal growth factor (10mcg) is available as a cream. This is a fusion of biological and chemical dressing material. Silver is also available in the concentration of 0.02% in collagen base and ionic silver nitrate gel in the concentration of 0.2%.

Liquid silver is available as patented wound management solution containing silver nitrate, menthol, glycerol, tween 20 (as a surfactant and detergent). In this solution, silver works as an antimicrobial agent and preservative, glycerol provides hygroscopic/hydrogel properties, menthol is pain reliever, odor fighter and enhances the penetration of silver. This is required to be used in the dose of 1 ml/1 cm² of the wound. The bottle should be used within 28 days after opening the bottle. Liquid silver is non toxic, non cytotoxic, nonstaining. It prevents maceration and eliminates bad odor.

Example: Slvrigen, Kolasil, Ionsil, Silver stream.

Silver Within the Structure of a Dressing

In many foam dressings, silver is included. Silver is also available in a combination of hydrocolloid, calcium alginate.

Examples: Biatain Ag, Mepilex Ag, Melgisorb Ag.

A silver releasing foam dressing was evaluated for the treatment of DFUs and found to be safe and better for healing [15]. Similarly in a prospective multicenter RCT (randomized control trial) silver containing hydro fiber dressing gave significantly greater reduction in depth as compared to calcium alginate treated ulcers [16].

Contraindications of Silver Dressings

Silver containing dressings are not to be used in patients undergoing MRI examination. Silver Sulfadiazine is not to be used in patients with G6PD deficiency. It should not be used in clean surgical wounds, not to be used in low risk of infections like donor site, closed surgical wounds, chronic wounds, patients sensitive to silver. It should not be combined with enzymatic debriders. During pregnancy or lactation it should be used with caution.

Comments

Silver is a good dressing material, it requires less frequent change of dressings, may be up to 7 days. There are plenty of commercially available preparations. The effect depends upon the availability of silver molecules. My experience of using liquid formulation of silver is excellent. We should reserve the silver dressing for infected wounds rather than wasting it for clean operated wounds.

Octenidine Dihydrochloride (0.05% W/V)

Octenidine dihydrochloride is a cationic surfactant, derived from pyridine. It is active against gram positive and gram negative bacteria. Since 1987, it has been used as an antiseptic, in concentration of 0.1–2%. It is a substitute for chlorhexidine. Octenidine preparations are less expensive than chlorhexidine and no resistance is observed. They may contain an antiseptic phenoxy methanol. Octenidine requires less concentration than chlorhexidine to kill common bacteria. It inactivates pathogens in one minute and one time application has protection for 24 h.

It is also effective against biofilms and considered to be superior to silver colloid and mupirocin.

It does not get absorbed through skin, mucus membrane and woundbed and does not pass the placental barrier.

Examples: Zotobac liquid and gel, Neocide gel.

Polyhexamethylene Biguanide 1% v/v (0.2% PHMB)

It is a broad spectrum, new generation antiseptic, also known as polyhexanide. It is a polymer, effective against pseudomonas, methicillin-resistant *Staphylococcus aureus* (MRSA), yeast, vancomycin-resistant enterococci, klebsiella. PHMB is

also used in swimming pools and hot tubs. PHMB impregnated gauze dressings are useful for reducing contamination of wounds by bacterial pathogens. Similar agent known as polyaminopropyl biguanide (PAPB) is less effective as compared to PHMB. PAPB is available as 0.1% solution as well as cream. It is marketed with betaine surfactant with glycerol and hydroxyl ethyl cellulose. It is antiseptic as well as moisturizer.

It is effective against biofilms and also effective in presence of blood and serum. It is not toxic and stays in place for up to 3 days. It is used as an antimicrobial agent by contact lens industry for many years.

PHMB should not be used on CNS or meninges, middle and inner ear, and eyes.

Examples: Nemipore, Prontosan, Milsept.

Hypochlorous Acid and Sodium Hypochlorite

Hypochlorous acid (HOCL) is a weak acid that forms when chlorine dissolves in water. It is a clear solution. In our body HOCL is produced intracellularly in response to phagocytosis of pathogens by neutrophils and plays an important role in the destruction of pathogens [17, 18].

Sodium hypochlorite (NaOCl) is composed of sodium cation (Na⁺) and a hypochlorite anion (OCl⁻). It may also be reviewed as a sodium salt of hypochlorous acid. When dissolved in water, it is commonly known as bleach or liquid bleach.

Sodium hypochlorite is practically and chemically distinct from chlorine, but may be converted into chlorine by addition of acid.

It eliminates the unpleasant odors. It kills 99.99% of all relevant pathogens just within 30 s. It is effective against viruses, spores, fungi, gram positive and gram negative bacteria. Vegetative bacteria are more sensitive to HOCL than endospore forming bacteria and fungi. It has also good bactericidal action on MRSA and VREF (Vancomycin Resistant *E. Faecium*). It is also effective against biofilms to a certain extent [19].

It has effect of reducing inflammation, thereby increasing blood flow to the tissue. The mechanism of action is disruption of cell wall and osmolysis and bursting of cells. Normal cells are not damaged.

It can remain in the wound and does not need removal. It also can be applied on exposed joints, cartilage, tendons, inner ear and even the abdominal viscera. It is hypoallergic and no resistance is found.

It has a quick odor control action, and can be used at donor and recipient site. It is also compatible with silver dressing, hernia meshes, enzymatic debriders and growth factors. It can be used in all stages of wound healing as monotherapy or comprehensive therapy.

It is available in the concentration of 0.006% and 0.003% HOCL mixed with 99.97% oxidized water.

Example: Microdacyn spray and gel, Oxum spray.

Tetrachlorodecaoxide (TCDC) 0.002%

It penetrates the tissue and stimulates phagocytosis. It also increases oxygen tension in hypoxic situation and activates myofibroblasts for wound contraction. It is advisable to use it twice a day.

It can also be given intra venous. It is used in the treatment of radiation cystitis, diabetic foot ulcers and wound healing. In addition tetrachlorodecaoxide is tried in pancreatic cancer also.

Example: Oxoferin.

Local Antibiotics

Fusidic acid, gentamicin, vancomycin, tobramycin...etc. are some of the antibiotics which are used for dressings. Mupirocine is derived from *Pseudomonas fluorescens* and is a topical antibiotic. It is available in combination with Metronidazole and sucralfat. But due to fear of developing resistance of organisms, it is not advisable to use them as a routine. Neomycin sulfate, polymyxin B sulfate and bacitracin zinc are also locally effective antibiotics. They are reported to be safe and effective topical agents for preventing infection in minor skin trauma. Bacitracin A is commonly used as 20% bacitracin zinc in petrolatum. Bacitracin is a poly peptide derived from *Bacillus Subtilis*. All these are antibiotics and available in the market with the name of neosporin. It is recommended for burns, scratches, cuts and minor skin infection. It is most effective when the affected area is cleaned before the ointment is applied. These local antibiotics are not recommended for children under the age of 2 years. Symptoms of an allergic reaction may include hives, rashes, and problems with breathing, itchy skin, swelling, redness of the skin, development of a burning sensation or chest tightness. With the availability of newer antiseptics, we rarely use this as a local application.

Antibiotic Beads

To provide adequate and long term local antibiotics, there are beads prepared from different materials mixed with antibiotics. Commonly used antibiotics are gentamicin, tobramycin, vancomycin and rifampicin.

There are two main types of carrier materials used, bio degradable (absorbable) and non bio degradable (non absorbable). PMMA (poly methyl methacrylate) is bone cement and is non absorbable. Metal beads are also non absorbable. Calcium sulphate and poly lactic acid beads are absorbable [20, 21].

The most commonly used bone cement is polymethylmethacrylate (PMMA), consisting of a powdered polymer mixed with a liquid monomer to form a solid structure. Currently, there are five antibiotic-laden PMMA bone cement products that are approved by the U.S. Food and Drug Administration (FDA). These

five products include Simplex P, which contains 1 g tobramycin [22] (Stryker Howmedica Osteonics, Mahwah, NJ); Palacos G, which contains 0.85 g gentamicin [23] (Zimmer, Warsaw, IN); SmartSet GHV and SmartSet MHV, which contain 1 g gentamicin (Depuy Orthopaedics, Inc., Warsaw, IN), and the Prostalac prosthesis (DePuy Orthopaedics, Inc.). Premixed antibiotic PMMA beads are available and widely used in Europe under the name Septopal (Biomet Merck, Dordrecht, The Netherlands) and popularized by Klemm but are not currently approved in the United States.

Antibiotic beads



The biodegradable substances have been divided into three main categories as described by McLaren: **proteins, bone graft materials and substitutes, and synthetic polymers**. Grouped within proteins are a variety of substances derived from biologic tissues including collagen, gelatin, thrombin, and autologous blood clot. These tissue substrates, of which collagen has been studied most extensively, provide scaffolding that can be used to contain the chosen antibiotic. Conflicting reports exist as to the efficacy of antibiotic-impregnated collagen in the treatment of osteomyelitis. It was demonstrated that gentamicin with collagen substrate reduced bacterial colony counts in experimental animal osteomyelitis more significantly than did gentamicin in PMMA. Bone graft materials and substitutes are available in the form of complexes of reconstituted collagen and de-mineralized bone particles. Synthetic biodegradable polymers like PLA, PGA, PDLA, and PLGA show better slow release of antibiotics.

Comments

It is not the dressing but the knowledge of wound which matters. Saline dressing serves the purpose for healing healthy non infected ulcers. Merbromin, Acryflavinum, are not used now a days as a dressing material because standard therapeutic concentrations are not available in the market and better antiseptics and healing agents are available in the market.

There are newer antiseptics available like octenidine, PHMB, Tetra chlorodeca-oxide, etc. which can sometimes be used with equally good results. It is the right dressing at right time which is more important than individual dressing material.

For bone infection and joint infection, antibiotic beads have changed the scenario. The antibiotic beads work for a very long time at the infected bone site. This helps to reduce use of systemic antibiotics and high concentrations of antibiotics are available at infection site.

References

1. Digison MB. A review of anti-septic agents for pre-operative skin preparation. *Plast Surg Nurs*. 2007;27(4):185–9.
2. Ascenzi JM. Chloroxenol: an old-new antimicrobial. In: *Handbook of disinfectants and antiseptics*. New York: M. Dekker; 1996. ISBN [978-0-8247-9524-5](#). [Archived](#).
3. British Pharmacopoeia. Compound benzoin tincture. [United States Pharmacopeia](#), USP29-NF24; 2006.
4. Wascher RA, Barcia PJ. Tincture of benzoin: clinical and microbiological implications of reusable containers. *Mil Med*. 1996;161(3):143–5.. [PMID 8637641](#)
5. Lawrence JC. The use of iodine as an antiseptics agent. *J Wound Care*. 1998;7:421–15.
6. Higgins DG. POvidone iodine: the tamed iodine. *Chemist Druggist*. 1975;30:274–5.
7. Bianchi J. Cadexomer iodine in the treatment of venous leg ulcers: what is the evidence. *J Wound Care*. 2001;10:225–9.
8. Hansson C, Cadexomer Iodine Study Group. The effect of cadexomer iodine paste in the treatment of venous leg ulcers compared with hydrocolloid dressing and paraffin gauze dressing. *Int J Dermatol*. 1998;37:390–6.
9. Michanek A, Hansson C, Berg G, Maneskold Claes A. Iodine induced hyperthyroidism after cadexomer iodine treatment of leg ulcers. *Lakartidningen*. 1998;9:5755–6.
10. Holloway GA, Johansen KH, Barnes RW, Pierce GE. Multicenter trial of cadexomer iodine to treat venous stasis ulcers. *West J Med*. 1989;15:35–8.
11. Apelqvist J, Rangnarsen Tennvall G. Cavity Foot ulcers in diabetic patients: a comparative study of cadexomer iodine and standard treatment. An economic analysis alongside a clinical trial. *Acta Dermatol Venereol*. 1996;76:231–5.
12. Klasen HJ. Historical review of the use of silver in the treatment of burns, 1: early use. *Burns*. 2000;26:117–30.
13. Dowsett C. The use of silver based dressings in wound care. *Nurs Stand*. 2004;19:56–60.
14. Lansdown ABG, Williams A, Chandler S, Benfield S. Silver absorption and antibacterial efficacy of silver dressings. *J Wound Care*. 2005;14:155–60.
15. Rayman G, Rayman A, Baker NR, et al. Sustained silver dressing in treatment of diabetic foot ulcers. *Br J Nurs*. 2005;14:109–14.
16. Jude EB, Apelqvist J, Spraul M, et al. Prospective randomized controlled study of hydrofiber dressing containing ionic silver or calcium alginate dressings non ischemic diabetic foot ulcers. *Diabet Med*. 2007;24:280–8.

17. Landa-Solis C, Gonzalez-Espinosa D, Guzman-soriano B, Snyder M, Reyes-Teran G, Torres K, Gutierrez AA. Microcyn: a novel super-oxidised water with neutral pH and disinfectant activity. *J Hosp Infect.* 2005;61:291–9.
18. Stewart PS, Rayner J, Roe F, Rees WM. Biofilm penetration and disinfection efficacy of alkaline hypo-chlorite and chlorosulfamates. *J Appl Microbiol.* 2001;91:525–32.
19. Tanaka H, Hirakata Y, Kaku M, Yoshida R, Takemura H, Mizukane R, Ishida K, Tomono K, Koga H, Kohno S, et al. Antimicrobial activity of super oxidized water. *J Hosp Infect.* 1996;34:43–9.
20. McLaren AC. Alternative materials to acrylic bone cement for delivery of depot antibiotics in orthopaedic infections. *Clin Orthop Relat Res.* 2004;427:101–6.
21. Mendel V, Simanowski HJ, Scholz HC, Heymann H. Therapy with gentamicin-PMMA beads, gentamicin-collagen sponge, and cefazolin for experimental osteomyelitis due to *Staphylococcus aureus* in rats. *Arch Orthop Trauma Surg.* 2005;125:363–8.
22. Nelson CL, McLaren SG, Skinner RA, et al. The treatment of experimental osteomyelitis by surgical debridement and the implantation of calcium sulfate tobramycin pellets. *J Orthop Res.* 2002;20:643–7.
23. Silverman LD, Lukashova L, Herman OT, Lane JM, Boskey AL. Release of gentamicin from a tricalcium phosphate bone implant. *J Orthop Res.* 2007;25:23–9.

Absorbent Dressings

5

Abstract

Management of exudates is a complex issue. The latest wound management consultants give emphasis on moist wound environment. Over exudation can better be managed by absorbent dressings. It serves two purposes, removal of excessive exudation and at the same time maintaining moist wound environment. Absorbent dressings also help in autolytic debridement process. Alginates are absorbent as well as hemostatic agents. Addition of antiseptics improves healing process and reduces frequency of dressings.

Some wounds are wet wounds with lots of exudates. For the comfort of the patients, management of exudation plays a vital role. Absorbent dressings are meant for exudate absorption, and for maintaining moist wound environment. With the help of absorbent dressings, frequency of dressing can be reduced. Absorbent dressing also plays a role of helping nature to do autolytic debridement. They can also be combined with antiseptics like silver and PHMB.

Absorbent dressings are available as self-adhesive dressing and non-adhesive dressing. To certain extent even gauze cotton pad dressing also serves the purpose of absorptive dressings.

S.No.	Types of dressings	Examples
1.	Foam dressing	Allvyn, Biatain, Mepilex Tielle, Cutinova, Liofoam, UrgoTul Lite
2.	Cotton and acrylic fiber dressing	Melolin
3.	Hydrocolloid dressing	Duo DERM, CGF, CGF border, CGF extra thin
4.	Alginate dressing	Calgisorb, Kaltostat, Sorbalgan, Melgisorb
5.	Hydrofiber dressing	Aqua cell hydrofibre, Aquacel Ag+ ribbon, Acquacel Ag+ extra thin
6.	Ceramic wound dressing	Cerdac

Foam Dressings

Foam dressings were developed as an alternative to hydrocolloids in 1970.

Chemistry

Foam dressings are made from urethane or some other polymer. They are of adhesive or non-adhesive types. The absorptive capacity of a foam dressing depends on the size of open cells generated during manufacturing. Foam dressings have air bubbles. Usually inner surface of the foam is covered by a thin urethane film. These dressings may also contain surfactants, glycerin or super absorbents [1]. They are also available as skin friendly hydrocolloid adhesive. The outer layer may be water proof or hydrophobic.

Sizes/Shapes

Foam dressings are available in different sizes and shapes. Specialized shapes are available for heel and sacral area pressure sores.

Self-adhesive silver foam dressing



Mechanism of Action

Foam dressings have superior permeability (moisture water transmission). The foam absorbs water and locks it in the dressing material (the fluid cannot go back to the wound) still maintaining moist wound environment. The urethane film also provides a seal for the bacteria.

Chronic wound fluid may have chemicals harmful to cells and provisional matrix [2]. Foam dressings imbibe the wound fluid and keep it away from the wound.

These dressings are not occlusive, they allow loss of moisture by transpiration through the back of the dressing by a capillary action. Different foam dressings have different moisture vapor transmission.

Covering the dressing by hosiery, footwear or an orthotic support may reduce the MVTR (Moisture vapor transmission rate) and it changes the ability of dressing to manage the exudates.

Pressure reduction is not the work of foam dressings. In a comparative study of 111 patients it was demonstrated that a hydrocellular foam heel dressing was superior to Soffban in preventing pressure ulcer on heel.

Some foam dressings are available in the following forms.

- (a) Top breathable film which transpires excess fluid and forms water proof barrier.
- (b) Middle layer of hydro cellular foam which retains fluid for moist wound environment.
- (c) Wound contact layer which absorbs fluid from the wound bed.

Uses

These dressings can be used as a primary dressing or secondary dressing. They can be used with hydrogels, alginates and topical antiseptics. They can also be used in infected wounds, wounds with hyper granulation tissues, venous ulcers, pressure sores. Dressings can be left in place for up to 7 days except sacral area where dressing can be left for a shorter period.

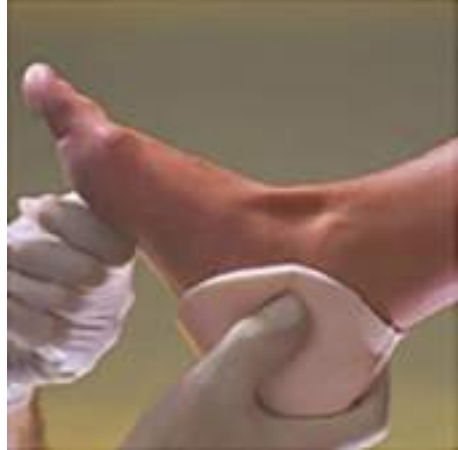Limitations

Wound may dry out if there is no or a little exudate. Maceration of the surrounding skin is seen if dressing becomes saturated with exudates. It is not suitable for third degree burns, sinus tracts or wounds with dry eschar. Dried foam may damage epidermis at the time of removal.

Examples: Allevyn, Biatain, Mepilex, Tielle, Cutinova, Liofoam....., etc.

Self-adhesive foam dressing





Heel pad for dressings in heel wounds

Some foam dressings have adhesive layer which dissolves in water, so it is more skin friendly and it is easy to remove after saline application (e.g. Tielle).

Cotton and Acrylic Fiber Dressing

It consists of a highly absorbent cotton and acrylic fibre pad which is heat bonded on one side to a very thin perforated polyester film. The film side of the dressing is placed next to the wound.


Features of Three Layers

- (a) Low adherent perforated film (poly ethylene terephthalate).
- (b) Highly absorbent cotton/acrylic pad.
- (c) Hydrophobic backing layer.

Uses

- (a) Post-operative and casualty use.
- (b) Clean and sutured wound.
- (c) Abrasions and laceration.
- (d) Minor burns.
- (e) Mild exudating wounds.

Cotton acrylic fiber
dressing



Example: Melolin

Hydrocolloid Dressings

Till 1970, it was believed that wound should be allowed to breathe [3, 4]. The wound healing research with hydrocolloid dressings proved that sometimes atmospheric oxygen harms or delays the healing process. Hydrocolloid dressings are completely air tight and do not allow the transport of oxygen or other gases [1].



Chemistry

Hydrocolloids are formulations of elastomeric adhesives (polyisobutylene) and gelling agents. The most common absorbent ingredient carboxy methyl cellulose (CMC) is a hydrocolloid. Some contain pectin. Hydrocolloid dressings have top film layer for water proofing.

Mechanism of Action

The fluid absorption takes place by swelling of particles and enlargement of the structure. The exudate absorption by most hydrocolloid dressings results in the formation of yellow or light brown gelatinous mass that remains covering the wound on dressing removal. That should not be confused with pus.

There may be a characteristic odor because of decomposition of hydrocolloid and gelatin.

Hydrocolloid dressing has been reported to increase epidermal healing by above 40% [5]. It absorbs exudates by 20 times the weight of the pad. It facilitates autolytic debridement, promotes granulation tissue, epithelialization and even increases collagen synthesis.

The wound environment under hydrocolloid dressing is acidic (PH 5.00) and has been shown to inhibit the growth of *Pseudomonas aeruginosa*, *Staphylococcus aureus* [6]. Although hydrocolloid dressings are absorbent, the rate of absorption is less than gauze or foam dressings.

To prevent malodor to come out from the wound, some hydrocolloid dressings are available as self-adhesive dressings.

Uses

It can be used over skin graft area and post-operative wounds and also for all exudative wounds. Hydrocolloid dressings are particularly useful when autolytic debridement is desirable [7].

Contraindications

It should not be used in wounds suspected to be having anaerobic infection. Less exudating wound should not be dressed with hydrocolloid dressing otherwise it dries out and there is superficial cellular death.

Examples: Duo DERM CGF, Duo DERM CGF Border, Duo DERM CGF Extra thin, Comfeel, Nemisorb.

Alginate Dressings

These dressings were first discovered by sailors in 1880. Alginate dressings are developed from naturally occurring polysaccharides found in certain species of brown seaweed harvested from western Scotland and west coast of Ireland. Alginic acid was first extracted from sea weed in 1881 by Stein Ford, and calcium alginates are available in dressing format since 1984. Alginates are more absorbent than hydrocolloids.

Calcium Alginate dressing



Chemistry

Alginic acid is a polymer of mannuronic acid and guluronic acid molecule. Alginates which are high in mannuronic acid readily exchange Ca^{+} ions for Na^{+} ions. The fiber dressings which are high in guluronic acid form stronger gel that keeps their shapes, making removal in one piece possible.

Alginates are biodegradable and will gradually dissolve with moisture with time. Alginates are also available in combination with hydrocolloid and silver.

Mechanism of Action

Alginate dressing absorbs wound exudate by ion exchange mechanism, where sodium ions in the exudates are exchanged for calcium ions in the dressing material.

Calcium alginate helps in the production of human fibroblasts, activate macrophages to produce TNF alpha. It reduces the production of human micro vascular endothelial cells and keratinocytes. Alginates are not painful at dressing change and can reduce healing time as compared to other types of dressings. Alginates have haemostatic and bacteriostatic properties [8]. Calcium ions released in the wound activate platelets and some clotting factors promoting haemostasis. Addition of topical sucralfate paste or 1:1000 concentration of adrenalin can be useful as a haemostatic agent.

Uses

Alginates are highly absorbent and get converted into gel quickly. It can absorb 20 times the weight of the pad. It is used for exudating wounds and malodorous wounds.

Limitations

In dry and ischemic wound, the fiber dries out and gets adhered to wound bed. If used incorrectly, alginates can form a plug restricting the exit of exudates [9–11].

Examples: Calgisorb, Kaltostat, Sorbalgan, Melgisorb.

Hydrofibre Dressing

Hydrofibres are fibres of CMC (Carboxy Methyl Cellulose) which is an absorptive ingredient used in hydrocolloids. Hydrofibres have 2–3 times greater absorptive capacity than alginates [12].

Hydrofibre dressing retains 68–70% of *Staphylococcus aureus* and *P. aeruginosa* compared to 7–12% and 32.41% respectively for alginate dressing [13]. Combination of hydrofibre with ionic silver provides better antimicrobial activity even for MRSA and VRE (Vancomycin Resistant Enterococci) within 30 min of exposure to dressings. High water content promotes rapid autolysis.

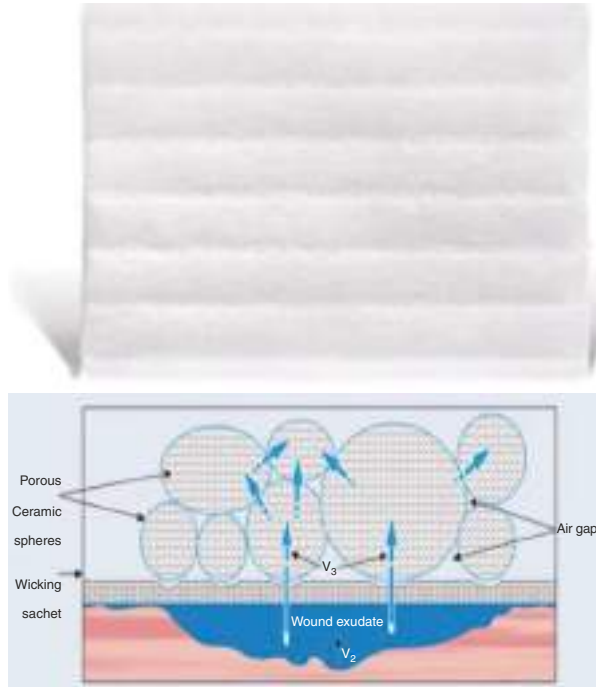
Examples: Aqua cell hydrofibre.

Ceramic Wound Dressing

Ceramic wound dressing is a different type of dressing where microporous ceramic granules are packed in a sachet [14]. The granules are packed in different sizes, and in a material where air access to wound is possible. Bio inert aluminium oxide is used to produce ceramic granules. The sachet is applied on the wound and it absorbs wound fluid. It can be kept in position till it is fully saturated.

There is no chemical reaction. It is simply absorption of exudates and so there is no allergic reaction observed. The colony forming bacteria are removed from the wound so indirectly there is antiseptic effect as well.

Ceramic wound dressing



Example: Cerdak.

Comments

Absorbent dressings are excellent dressings for exudate management, autolytic debridement, moisture regulation and even for healthy healing ulcers. It reduces frequency of dressings and comfort of the patients. Addition of antiseptics works as icing on the cake. Hydrocolloids are not used in diabetic wounds and precautions should be taken not to be used in less exudating wounds and wounds with anaerobic infection. Alginates have haemostatic as well as absorptive capacity so post debridement application is advantageous. Routine gauze cotton pad dressings are gold standard for majority of the patients. Selective use of advanced dressing material is advisable. Absorbent dressing can be associated with local antiseptics and can be used along with vacuum therapy.

References

1. Veves A, et al. The diabetic foot. 2nd ed. Totowa, NJ: Humana Press; 2006. p. 316, Chapter 16.
2. Tomic-Canic M, Agren MS, Alvarez OM. Epidermal repair and the chronic wound. In: The epidermis in wound healing. Boca Raton, FL: CRC Press; 2004. p. 25–7.
3. Alvarez OM, Heftom JM, Eaglstein WE. Healing wound: occlusion or exposure. *Infect Surg.* 1984;3:173–81.
4. Jones V, Grey JE, Harding KG. Wound dressings. *BMJ.* 2006;332(7544):777–80. ncbi.nlm.nih.gov. This is the ninth in a series of 12 **articles** ... Sodium carboxymethylcellulose, gelatin, pectin, elastomers, and adhesives are bonded to a carrier of semipermeable film or a **foam** sheet to produce a flat, occlusive, adhesive **dressing** that ... Hydrocolloid **dressings** (including hydrofibres)
5. Klasen HJ. A historical review of the use of silver in the treatment of burns. II. Renewed interest for silver. *Burns.* 2000;26:131–8.
6. Varghese MC, Balin AK, Carter M, et al. Local environment of chronic wounds under synthetic dressings. *Arch Dermatol.* 1986;122:52–7.
7. Burton CS. Management of chronic and problem lower extremity wounds. *Dermatol Clin.* 1993;11:767–73.
8. Thomas S. Alginate dressings in surgery and wound management part 3. *J Wound Care.* 2000;9:163–6.
9. Foster AVM, Greenhill MT, Edmonds ME. Comparing two dressings in the treatment of diabetic foot ulcers. *J Wound Care.* 1994;3:224–8.
10. Lawrence IG, Lear JT, Burden AC. Alginate dressings and the diabetic foot ulcer. *Pract Diabetes Int.* 1997;14:61–2.
11. Jones V. Alginate dressings and diabetic foot lesions. *Diabet Foot.* 1999;2:8–14.
12. Ovington LG. The well dressed wound: an overview of dressing types. *Wounds.* 1998;10:1A–11A.
13. Newman GR, Walker M, Hobot JA, Bowler PG. Visualization of bacterial sequestration and bacterial activity within hydrating hydrofiber wound dressing. *Biomaterials.* 2006;27(7):1129–39.
14. Weller C, Sussman G. Wound dressings update. *J Pharm Pract Res.* 2006;36(4):318–24.

Abstract

Wound heals better in moist environment. Moist gauze dressing and glycerin magnesium sulphate dressings are used since years. Gauze dressings dry out early and needs change 2-3 times in a day. All absorbent dressings maintain moist wound environment but dressings like hydrogel and glycerin magnesium sulphate provide direct moisture to the wound.

Moisturisers are the dressing materials which provide moisture to wound and help autolytic debridement process [1]. Autolytic debridement is the lysis of necrotic tissue by human WBCs and enzymes which enter the wound site during the normal inflammatory process. By maintaining moist wound environment, proteolytic, fibrinolytic and collagenolytic enzymes released in the wound digests the devitalized tissue in the wound. The moist wound environment helps neutrophils and macrophages to do phagocytosis, if the wound gets dried and dessicated, this process stops. The debridement in presence of moist wound environment by body's own mechanism is called autolytic debridement. Advanced dressing materials help to maintain moist wound environment. This advance has led to the development of many moisture-retentive dressings that promote “moist wound healing” [2, 3]. Moist wound environment promotes re-epithelialization and so reduces scar formation, it also allows delivery of antimicrobials, analgesics and bioactive molecules.

Examples:

- (a) Glycerine magnesium sulphate.
- (b) Hydrogels.
- (c) Alginate moist.
- (d) Silver ion moist dressing.
- (e) Foam.
- (f) Hydrocolloid.

Glycerine Magnesium Sulphate

This is commonly known as glycerine magsulf and it is a debrider. It provides a moist wound environment and helps in autolytic debridement.

Hydrogel

Hydrogel is formed from a hydrophilic polymer such as polyvinylpyrrolidone [4]. It has high water content and allows high rate of evaporation. Natural hydrogels are gradually replaced by synthetic hydrogels in last 20 years. The synthetic hydrogel have long service life, high capacity of water absorption and high gel strength.

Classification of hydrogels as per physical structure and chemical composition is as follows

(a) Amorphous (Non Crystalline)

In amorphous hydrogel the hydrophilic polymer has not been cross linked and therefore remains in a gel like state. Several amorphous hydrogels contain additives such as collagen, calcium alginate, or CMC in order to be more absorptive.

(b) Semi crystalline (a complex mixture of amorphous and crystalline phases).

(c) Crystalline.

- Hydrogels are packed in tubes, spray bottles or foil packets. Hydrogels are also available in the form of a sheet, impregnated gauze form.
- Because of the soothing property, hydrogels are used in painful wounds and thermal injuries. It can cool the skin by 5 °C [5, 6].
- Hydrogel is also available in combination with hydrocolloid as dressing.
- Biocellular wound dressings are similar to hydrogel (not true hydrogel). Bio cellulose is made from purified bacterial cellulose that can deliver and absorb moisture.

Some hydrogel does not contain propylene glycol which is commonly used in other hydrogels. Hydrogel without propylene glycol can be used prior to larva therapy. Some hydrogel contains purified water, sodium carboxy methyl cellulose and calcium alginate.

Alginate moist dressing, silver ion moist dressing, foam and hydrocolloid dressings are absorbent dressings but also work as a moisturizing dressing.

Examples: Duoderm gel, Intrasite gel, Purilone gel.

Comments

Wound heals better in moist wound environment. Moist gauze dressing and glycerine magnesium sulphate dressings are used since years. Moist gauze dressings dry out early and need change of dressing three times a day. All absorbent dressings

maintain moist wound environment but certain dressings like hydrogel and glycerine magnesium sulphate are exclusively made for providing moisture to the wound. Absorbent dressings are described in other part of the book.

References

1. Kannon GA, et al. Moist wound healing with occlusive dressings. *Dermatol Surg.* 1995;21(7):583–90.
2. Helfman T, Ovington L, Falanga V. Occlusive dressings and wound healing. *Clin Dermatol.* 1994;12(1):121–7.
3. Ovington LG. The evolution of wound management: ancient origins and advances of the past 20 years. *Home Health Nurse.* 2002;20(10):652–6.. the diabetic foot page no 308
4. Veves A, et al. Chapter 16: Local care of diabetic foot ulcers. In: *The diabetic foot.* 2nd ed. Totowa, NJ: Humana Press; 2006. p. 317.
5. Alvarez OM, Rozint J, Wiseman D. Moist environment for healing: matching the dressing to the wound. *Wounds.* 1989;1(1):35–50.
6. Alvarez OM. Pharmacological and environmental modulation of wound healing. In: *Connective tissue disease. Molecular pathology of the extracellular matrix.* New York: Marcel Dekker; 1987. p. 367–84.

Abstract

(A) Collagen dressings:

Process of healing requires collagen. Human body has 29 different types of collagen. Collagen dressings are available in the form of powder, cream, and sheet or wafers. Collagen is extracted from rat tendon, bovine skin or pig intestine. Collagen is also available in combinations with alginates, metronidazole, mupirocin, gentamycin and silver sulphadiazine. Collagen dressing should not be used in presence of infection and necrotic tissue. It is not a debriding agent or an antiseptic.

(B) Honey and sugar paste dressings:

Honey is used as a dressing material since 4000 years. It is derived from many floral sources. Manuka honey and pasture honey are two main types honey used for dressing. Similarly sugar paste is also tried by many as dressing material. Honey proves better than sugar paste. The effect is deodorizing, reduces inflammation, edema and exudates, it has some anti-bacterial effect as well.

(C) pH modulating dressings:

Usually the pH of exudates is alkaline. The pH of skin secretion is slightly acidic. By making change in pH, the environment for organism changes, this might add to antiseptic effect. The effect of MMPs reduces with the reduction of pH. In chronic wounds there is high level of MMPs. It is thought that reducing the pH from 8 to 4 reduces MMP activity by 80%. Hydrocolloid and certain other dressings have ability to change pH to acidic.

(D) Hyaluronic acid:

It is a natural component of extra cellular matrix; it controls water retention and ionic and molecular diffusion. HA facilitates the growth and movement of fibroblast. It is available as cream, sponge, fibers, and threads. It is also used as a scaffold for fibroblast and keratinocyte culture.

(E) Hemoglobin spray:

Hemoglobin spray is prepared from pig hemoglobin. It is thought to supply oxygen to the wound. It is available in the form of a spray.

(F) Dressings to control malodor:

Many diabetic and non-diabetic wounds are foul smelling because of necrosis and gas forming organisms. Both aerobic and anaerobic bacteria produce offensive odor. If dressings are kept for a longer time, it also smells bad. Maggots infected wounds have a special odor. In addition to frequent change of dressings, charcoal powder, metronidazole gel, some foam dressings and alginate dressings can tackle the malodor.

(G) Local insulin treatment:

Senior surgeons used local insulin injections and dressing for wound healing. It is thought to increase the rate of growth of fibroblast and thereby assist in wound healing.

Collagen Dressings

There are 29 different types of collagens found in human body. Type I, II, and III are the main types of collagens found in the tissues. Collagen dressings are usually prepared from type I bovine or avian collagen.

Rat tendon, bovine skin or pig intestine are used to extract collagen. Recently products from fish are also available for collagen dressing. After purification, it is lyophilized and a sheet or wafer is formed. Even hybrid collagen is available where collagen matrix is covered by silicone layer.

The bio stability of collagen can be improved by addition of silica. This bio stability reduces the dressing frequency. Collagen is available in the form of collagen sheets, collagen matrix composites (with collagen types I, II and III), collagen with calcium alginate or oxidized cellulose and cryopreserved human acellular dermis. It is also available in combination with metronidazole, mupirocin, gentamycin, and silver sulphadiazine. Bovine collagen is also available with oxidized regenerated cellulose (PROMOGRAN).

Some fish skin (tilapia fish) is considered to be having collagen and omega 3 fatty acid which helps in healing of chronic wounds.

Mechanism of Action

Matrix metalloproteases (MMPs) are responsible for chronicity of wounds. MMPs are deactivated or inhibited by several collagen dressings. Collagen is thought to provide a scaffold for cells involved in repair process [1]. Collagen in the dressing may provide a substrate for the proteolytic enzymes present in chronic wounds and spares the normal matrix destruction [2]. Some advanced dressings with collagen

provide scaffold and may reduce chronic inflammatory stage of the wound by binding to excess proteolytic enzymes (MMPs) responsible for degradation and increases formation of new collagen and granulation tissue.

Clinical Application

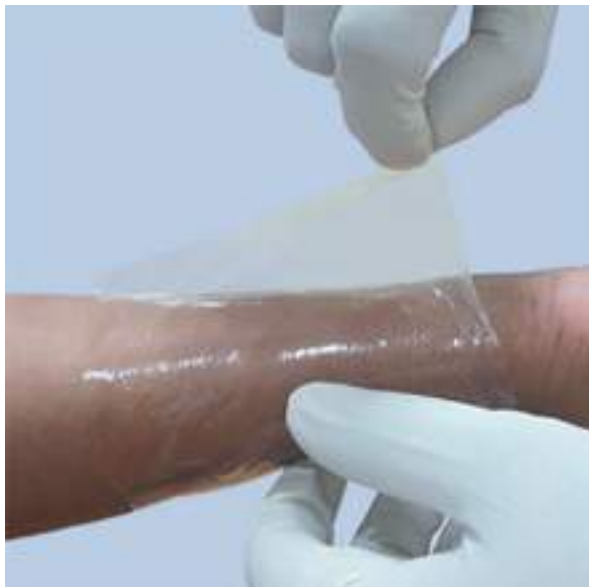Collagen powder



Collagen sponge dressing



Collagen sheet dressing



Collagen dressings should be used on a wound without necrotic tissue. The collagen dressing of bovine origin should not be used if a patient is sensitive to products of bovine origin.

Trial

In one study ulcers receiving treatment with oxidised regenerated cellulose (promogran) had better healing (45%) as compared to (33%) in those receiving standard care [3].

Examples: Co mupimet granules, Collofibre mm, Collaheal, Promogran, Sore treat, Bio-seal MM, Xenoderm-WT.

Comments

Collagen dressing should be used in chronic and exudating wounds. In presence of infection and necrotic tissue, it should not be used. It is neither a debriding agent nor an antiseptic. Collagen with local antibiotic dressing is available for mild infected wounds. For rightly selected healing ulcers, collagen dressing may be changed every 4–5 days. When collagen sheet is applied, it should not be scraped out at the time of dressing change.

Honey Dressings and Sugar Paste Dressings

Honey is used as a dressing material for over 4000 years. Dr. Peter Mohan, associate professor of biochemistry and director of the honey research unit of the University of Waikato, New Zealand, has pioneering research on honey in wound management. Edwin Smith (almost 1700 years B.C.) described the topical use of honey in different types of wounds [4].

Honey is derived from many floral sources. Two main types of honey are manuka honey and pasture honey. Manuka honey is derived from particular floral sources in New Zealand and Australia. Manuka tree (it is a tree of tea family) honey is much better than mixed flora honey.

Mechanism of Action

Honey has antimicrobial properties and provides moist wound environment. It has deodorizing effect and reduces inflammation, edema and exudates [5]. Glucose oxidase enzyme in honey enables release of hydrogen peroxide. There is subsequently release of oxygen which is responsible for antibacterial effect. The antibacterial effect of honey is also due to high osmolarity of sugar content and presence of some phytochemicals of some plant species [6, 7].

Antibacterial effect of manuka honey is double than that of pasture honey. This assists monocytes and macrophages to function better in damaged tissue where oxygen supply is often poor. Monocytes and macrophages require enhanced glucose uptake and glycolysis for better functioning. Honey provides substrates for glycolysis there helping monocytes and macrophages.

Clinical Use

Medical grade honey is marketed as impregnated dressing and actual honey. There are new hydroactive range of honey dressings which are available as an ointment, hydrogel coated mesh and semi permeable wound dressings. Other ingredients in the ointment include lanolin, sun flower oil, cod liver oil, calendula and vitamin C and E. Recently one local application is available in the market with combinations of aloe vera, karanj oil, cow ghee, honey and turmeric extract.

In a study of 900 patients with partial thickness burns of less than 40% of the body surface, the mean wound healing time in honey treated subjects was 9 days compared to 13.5 days in control group. In another study of 100 patients of honey dressings, healing was found better as compared to silver sulfadiazine dressings [8].

Example: Algivon (alginate with manuka honey), WH5 (GUFIC).

Sugar Paste

Many clinical studies were done on sugar paste in 1980s. Majority of the studies had comparison with chlorinated lime and boric acid solution, and with povidone iodine dressing [9].

Thick sugar paste is highly viscous and is made up of caster and icing sugars mixed with polyethylene glycol and hydrogen peroxide. Hydrogen peroxide is usually detrimental to wound healing, but in this case it performs a different function. The peroxide is added to the paste when it is prepared to reduce the bacterial contamination of the raw sugar. Oxygen is released during the process of chemical combination, destroying any bacteria and leaving a residue of water. Therefore hydrogen peroxide is not left in the sugar paste and, consequently, it is not toxic.

On contact with the wound, sugar paste rapidly liquefies, does debridement and helps in granulation tissue formation. The osmotic effect of sugar inhibits bacterial reproduction. It draws out exudate and tissue fluid resulting in increased osmotic pressure. For its effect it is required to be applied twice daily.

Seal and Middleton [10] revealed that sugar paste was non-toxic and reduced the odor caused by anaerobic bacteria. Archer et al. [11] showed that it resulted in the formation of granulation tissue and epithelialization at a rate similar to that in wounds kept moist with a film dressing [12].

The evidence suggests that sugar paste dressings are most effective on sloughy, infected wounds [9–11, 13].

Comments

Honey appears to be more effective than sugar in reducing bacterial contamination and promoting wound healing, and slightly less painful than sugar paste during dressing changes. But more clinical research and larger trials are required to prove or disprove its efficacy in comparison to other modalities of treatment.

Hyaluronic Acid (HA)

Hyaluronic acid is a natural component of extracellular matrix that creates a hydrophilic environment, controls water retention and ionic and molecular diffusion. It plays an important role in the process of tissue repair. It has unique hydration capacity. It is a carbohydrate and it is also known as hyaluronan.

Function

In the early inflammatory phase of wound healing, wounded tissue is abundant in hyaluronic acid. It acts as a promoter in early inflammation, enhances cellular infiltration. It is abundant in granulation tissue and matrix. A variety of cell functions that are essential for tissue repair are attributed to inflammation which needs to be

moderated. Initial granulation tissue is highly inflammatory. Stabilization of granulation tissue can be achieved by moderating inflammation. Hyaluronic acid functions as an important moderator. It serves as an integral part of extracellular matrix of basal keratinocytes. Hyaluronic acid has crucial function of epithelialization process. In normal skin, HA is found in high concentration in basal layer of epidermis.

Hyaluronic acid is a polysaccharide that facilitates the growth and movement of fibroblasts, but is unstable when applied to tissue. When esterified as in Hyaff, it becomes more stable and produces a hydrophilic gel in contact with wound exudates, that covers the wound. This creates an HA-rich tissue interface that promotes granulation and healing.

Hyaff is a derivatives of hyaluronic acid which is naturally present in body tissue and is associated with tissue repair [14]. This is a novel hyaluronan based biomaterial composed of a benzyl ester of hyaluronic acid (produced by esterification of hyaluronic acid with benzyl alcohol) following degradation, it releases high concentration of HA into the wound. It is available as sponge, fibers, threads, and microfibers. Hyaff is biodegradable and bioabsorbable and is also used as a scaffold for autologous fibroblast and culture expanded autologous grafts containing keratinocytes. A study of 36 patients of diabetic foot also showed improved healing with Hyaff dressing [15].

Clinical studies have shown that Hyaff is not toxic, it is non-mutagenic, non-hemolytic and non-irritant.

Example: Biozel, Hyalofill, Healoderm.

Comments

Hyaluronic acid is present in all body fluids mainly tears and synovial fluids. For medicinal use, hyaluronic acid is made by bacteria in laboratory. Hyaluronic acid is used as a lip filler in plastic surgery, for healing of wounds and for osteoarthritis. Looking to its mechanism of action, it can very well be used in non-infected healing wounds.

Dressings to Control Malodor

There are some wounds which smell foul. Malodor is usually by both aerobic and anaerobic bacteria. It is because of tissue necrosis and gas liberated during the process. Offensive smell is sometimes because of malodorous volatile fatty acids [16]. Cadaverine and putrescine are diamines released after tissue necrosis. They are aromatic diamines. The word putrefaction has come from the word putricin.

Bacteria like *Proteus*, *Pseudomonas* and *Klebsiella* can also produce offensive odors.

Malodorous wounds are often poly microbial and may contain both anaerobes and aerobes, and the level and type of bacteria present will affect the wound environment. It includes bacteroids such as *Bacteroides fragilis*, *Prevotella*, *Fusobacterium nucleatum*, *Clostridium perfringens* and anaerobic cocci.

Proteus infection gives odor of ammonia; pseudomonas infection has characteristic sweet odor.

Charcoal Dressing



Charcoal powder

Charcoal dressings alone or in combination with silver can be effective deodorizer. The first successful use of charcoal cloth to treat fungating breast cancer, gangrene, and post-operative colostomy management to reduce odor was reported by Butcher et al. 1976. Charcoal also has got the capacity to absorb bacterial spores. Bad odor may be managed by charcoal filter applied to the wound.

Metronidazole Dressing

Metronidazole gel is usually effective within 2 days for control of odor [17–20]. Sometime it may take up to 30 days. It is very effective against anaerobic organisms. It is available in combination with iodine, mupirocin and collagen powder.

Example: Anabact, Metrogel, Zyomet gel.

Comments

Malodor is very common in diabetic wounds and also in wounds where dressing is kept for a longer time. Changing the dressing daily may reduce the odor. Wound irrigation with normal saline, application of metronidazole cream, foam dressings, alginate dressings help to reduce bad odor. Bad odor is a sign of infection and proper antibiotics and dressing materials should be used till it disappears. Maggots give special odor which is sometimes diagnostic of presence of maggots. That odor will go only after removal of maggots. In four layered bandage for venous stasis ulcers, on opening the dressing it usually smells bad, but it is a normal finding. In

spite of modifications in dressings, if bad odor does not disappear then we need to consider change of antibiotics.

Maggots, honey dressings, and chlorinated dressings of Eusol also to a certain extent help to reduce the malodor of the wound.

Hemoglobin Spray

Chronic wounds have many hurdles for healing. Presence of infection, slough, excessive exudation, etc. prolongs healing time. Low level of oxygen is a factor responsible for poor healing especially in peripheral vascular disease [21]. Hemoglobin spray was found to be useful for local oxygen delivery before even 50 years. Recent study in 5 wounds with local hemoglobin spray has given promising results [22].

Hemoglobin spray is available in liquid form and is prepared from pig hemoglobin. It is applied with the aim of supplying oxygen to the wound [23–25]. It is thought to be useful in chronic wounds, venous ulcers, diabetic foot wounds, pressure ulcers, etc. It is thought that it oxygenates the wounds and there is clinical evidence of better healing in many clinical trials but it is not used by many with doubtful expectancy.

Haemoglobin spray is applied after thorough debridement. No necrotic tissue should be there at the time of application. The wound is secondarily dressed with breathable dressing. It is advisable to change the dressing every 3 days.

Comments

Haemoglobin spray is supposed to supply more oxygen at the wound site. Wound should be washed and debrided before application of haemoglobin spray. No clinical data is available for its advantage over other dressing materials. Its safety is not proved in pregnant women.

Example: Granulox spray.

pH Modulating Dressings

We usually don't measure the pH of wound fluid. It is easy to measure pH of wound exudate with the help of strips available to measure urine pH [26]. Our skin has a pH of below 6, this is with the help of secretions of skin glands. Acidic pH of skin protects our skin [27]. Majority of chronic wounds have alkaline pH. Bacteria which can grow in alkaline medium may not survive in acidic medium. The concept of changing pH of wound fluid may help to eradicate infection. The application of pH modulating wound dressings can be a promising treatment option to promote healing.

The effect of MMPs is reduced with reduction of pH. Increase in MMPs in chronic wounds is thought to be responsible for delayed healing. It is thought that reducing

the pH from 8 to 4 reduces MMP activity by 80%. Baby soaps are available with pH 5.5, which can be used to wash a wound. Polyhydrated, ionogen-coated, polymer mesh dressing, and protease modulating collagen cellulose dressing is thought to reduce pH and thereby assist in healing [28, 29]. The sodium carboxymethyl cellulose hydrofiber and manuka honey dressing also reduce the pH [30]. In a 2D cell migration assay, the application of hydrogels (0.0 to 1.5% acrylic acid) resulted in complete wound healing. The hydrogels with 0.25 acrylic acid is tested on human skin wounds, increasing keratinocyte ingrowth into the wound is noted in 3D by approximately 164%.

Examples: Manuka honey, CMC, Hydrocolloid dressings.

Comments

It is not a routine to measure the pH of wound fluid. If we start measuring the pH of wound fluid and start modifying dressings accordingly, we might require less quantities of antibiotics and infection can be eradicated faster. The pH of human skin secretions is acidic and that pH is important to maintain skin integrity and resistance to infections. The soaps available in the market are having pH more than 8, except baby soaps which has pH of 5.5. The wound environment under hydrocolloid dressing is acidic (PH 5.00) and has been shown to inhibit the growth of *Pseudomonas aeruginosa* and *Staphylococcus aureus*. Regular use of baby soap to wash wounds before dressing can help process of healing.

Local Insulin Treatment

Insulin is known to help healing of wounds. Many studies are done which shows good effects of insulin on wound healing [31–33]. Different types of local insulin preparations were used in twentieth century to control local hyperglycemia of wound and surrounding tissues. The main purpose of study is to correlate local insulin and its relation to IGF.

Many senior surgeons claim that injection of insulin locally and local application of insulin give excellent results in diabetic as well as non-diabetic patients. Routine cleaning and debridement of the wound is to be done as usual 4 units of human soluble insulin is mixed with 1 mL of normal saline. This is sufficient for 10 cm² ulcer. The solution thus prepared is injected around the ulcer and in the bed of the ulcer. Some solution is poured on a piece of gauze piece and used as a primary dressing. It is advisable to do this dressing twice a day. IGF has many similarities with insulin hormone. Like IGF, in vivo studies local insulin is known to stimulate the proliferation, migration and extracellular matrix excretion by keratinocytes, endothelial cells, fibroblasts and even formation of granulation tissue [34]. Frequent blood sugar monitoring is required. More clinical research is required to authenticate its routine use in wound healing.

Comments

Insulin is thought to increase the rate of growth of fibroblasts thereby helping the wound to heal. As such the dose of local insulin is very less so chances of systemic effect is very negligible. But it is still required to monitor regular blood sugar levels. Insulin works as a growth hormone. There are better local applications available, so clinical trials are not done on local insulin therapy. But more trials are required to prove its role in diabetic and non-diabetic patients.

References

1. Leipziger LS, Glushko V, DiBernardo B, Shafaie F, Noble J, Alvarez OM. Dermal wound repair: role of collagen matrix implants and synthetic polymer dressings. *J Am Acad Dermatol*. 1985;12(2):409–19.
2. Tomic Canic M, Agren MS, Alvarez OM. Epidermal repair and the chronic wound. In: Rovee DT, Maibach H, editors. *The epidermis in wound healing*. Boca Raton, FL: CRC Press; 2004. p. 25–57.
3. Veves A, Sheehan P, Pham HT, et al. A randomized controlled trial of promogran (a collagen/oxidized regenerated cellulose dressing) vs standard treatment in the management of diabetic foot ulcers. *Arch Surg*. 2002;137:822–7.
4. Udawadia TE. Ghee and honey dressing for infected wounds. *Indian J Surg*. 2011;73(4):278–83. Published online 2011 Apr 6. <https://doi.org/10.1007/s12262-011-0240-7>.
5. Molan PC. Reintroducing honey in the management of wounds and ulcers- theory and practice. *Ostomy Wound Manage*. 2002;48:28–40.
6. Molan PC. Potential of honey in the treatment of wounds and burns. *Am J Clin Dermatol*. 2001;2:13–9.
7. Molan PC, Betts JA. Clinical usage of honey as a wound dressing: an update. *J Wound Care*. 2004;13:353–6.
8. Allen KL, Hutchinson G, Molan PC. The potential for using honey to treat wounds infected with MRSA and VRE. Paper presented at: the first world wound healing congress; 2000;20:878–889. Melbourne, Australia; Paper presented on 10th–13th September 2000 and is online.
9. Gordon H, Middleton K, et al. Sugar and wound healing. *Lancet*. 1985;326:663–4.
10. Seal DV, Middleton K. Healing of cavity wounds with sugar. *Lancet*. 1991;338:571–2.
11. Archer H, Middleton K, et al. Toxicity of topical sugar. *Lancet*. 1987;1:1485–6.
12. Mphande AN, Killowe C, Phalira S, Jones HW, Harrison WJ. Effects of honey and sugar dressings on wound healing. *J Wound Care*. 2007;16(7):317–9.
13. Biswas A, Bharara M, Hurst C, Gruessner R, Armstrong D, Rilo H. Use of sugar on the healing of diabetic ulcers: a review. *J Diabetes Sci Technol*. 2010;4(5):1139–45.
14. Edmonds M, Foster A. Hyalofill: a new product for chronic wound management. *Diabet Foot*. 2000;3:19–30.
15. Vazquez JR, Short B, Findflow AH. Outcomes of hyaluronan therapy in diabetic foot wounds. *Diabetes Res Clin Pract*. 2003;59:123–7.
16. Ashford RF, Plant GT, Maher J, Pickering D, Coe MA, Drury A, et al. Metronidazole in smelly tumours. *Lancet*. 1980;1(8173):874–5.
17. Clark J. Metronidazole gel in managing malodorous fungating wounds. *Br J Nurs*. 2002;11(Suppl 6):S54–60.
18. Moody M. Metrotop: a topical antimicrobial agent for malodorous wounds. *Br J Nurs*. 1998;7(5):286–9.

19. Sparrow G, Minton M, Rubens RD, Simmons NA, Aubrey C. Metronidazole in smelly tumours. *Lancet*. 1980;1(8179):1185.
20. Williams K, Griffiths E. Malodorous wounds: causes and treatment. *Nurs Resid Care*. 1999;1(5):276–85.
21. Sen C. Wound healing essentials: let there be oxygen. *Wound Repair Regen*. 2009;17(1):1–18.
22. Petri M, Stoffels I, Jose J, et al. Photoacoustic imaging of real-time oxygen changes in chronic leg ulcers after topical application of a haemoglobin spray: a pilot study. *J Wound Care*. 2016;25(2):87, 89–91.
23. Scholander PF. Oxygen transport through hemoglobin solutions. *Science*. 1960;131:585–90.
24. Schreml S, Szeimies RM, et al. Oxygen in acute and chronic wound healing. *Br J Dermatol*. 2010;163(2):257–68.
25. Hunt SD, Elg F. Clinical effectiveness of hemoglobin spray (Granulox®) as adjunctive therapy in the treatment of chronic diabetic foot ulcers. *Diabet Foot Ankle*. 2016;8(1):33101.
26. Greener B, Hughes AA, Bannister NP, Douglass J. Proteases and pH in chronic wounds. *J Wound Care*. 2005;14(2):59–61.
27. Sharpe JR, Harris KL, Jubin K, et al. The effect of pH in modulating skin cell behaviour. *Br J Dermatol*. 2009;161(3):671–3.
28. Dissemmond J, Witthoff M, Brauns TC, et al. pH values in chronic wounds. Evaluation during modern wound therapy. *Hautarzt*. 2003;54(10):959–65.
29. Cullen B, Smith R, McCulloch E, et al. Original research articles mechanism of action of PROMOGRAN, a protease modulating matrix, for the treatment of diabetic foot ulcers. *Wound Repair Regen*. 2002;16–25.
30. Gethin GT, Cowman S, Conroy RM. The impact of manuka honey dressings on the surface pH of chronic wounds. *Int Wound J*. 2008;5(2):185–94.
31. Zhang XJ, Wu X, Wolf SE, Hawkins HK, Chinkes DL, Wolfe RR. Local insulin-zinc injection accelerates skin donor site wound healing. *J Surg Res*. 2007;142:90–6. <https://doi.org/10.1016/j.jss.2006.10.034>.
32. Liu Y, Zhang X, Zhang Z, Fang PY, Xu WS. Effects of topical application of insulin on the wound healing in scalded rats. *Zhonghua Shao Shang Za Zhi*. 2004;20:98–101.
33. Liu Y, Zhang X, Zhang Z, Xu WS. The influence of topical application of insulin on the formation of basement membrane in scalded rats. *Zhonghua Shao Shang Za Zhi*. 2005;21:445–7.
34. Schramm JC, Dinh T, Veves A. Microvascular change in the diabetic foot. *Int J Low Extrem Wounds*. 2006;5:149–59. <https://doi.org/10.1177/1534734606292281>.

Other Modalities of Treatment

8

Abstract

(a) **Local oxygen therapy:**

Molecular oxygen is essential during the process of inflammation and repair. Local oxygen therapy increases growth factor expression, increases angiogenesis. Local oxygen therapy is not HBOT. Air tight bag and oxygen are the only requirements. It is also available in portable model and in-hospital delivery device. More clinical trials require to prove its efficacy.

(b) **Ozone therapy:**

Ozone is a colorless, pungent odor gas. It is an oxidizing agent and is used in medical condition since nineteenth century. It has disinfecting, oxidizing, and deodorizing properties. It also can decolorize. It is used locally with an airtight bag for wound healing. It is used in diabetic foot wounds, ischemic wounds and necrotizing fasciitis. For other conditions it is administered per rectally and intravenously.

(c) **Hyper baric oxygen therapy:**

2–2.5 ATA (atmosphere absolute) pressure is used in hyper baric oxygen therapy.

This therapy results in arterial oxygen tension to around 2000 mmHg and that in tissues of around 400 mmHg. The therapy is given for 90–120 min per day. It is much better than local oxygen therapy. It is best used for post revascularization residual ischemia and PVD with non-operable disease.

(d) **NPWT:**

For removal of exudates, to reduce toxic material and bacterial load, to increase neovascularization and to reduce wound edema, NPWT is an excellent therapy. –125 to –75 mmHg pressure is used in NPWT. A specialized type of foam or sponge is used. Drug delivery and oxygen delivery devices are available in new generation NPWT devices. It is contraindicated in malignancy, fistula, and over exposed blood vessels and nerves.

(e) Electric therapy & Ultrasonic therapy for wound debridement and healing:

Though less utilized, electric therapy is useful for chronic wounds. Normal human skin is found to produce steady electrical potential. On injury to skin endogenous electrical current is produced. Electric therapy decreases bacterial infection, increases local perfusion, accelerates wound healing. It is not a form of radiation or heating, but it uses an electromagnetic field with the aim of stimulating healing.

Ultrasound remains a controversial modality in wound management. Electrical waves are converted in to sound waves. Ultrasound is used for debridement. The process is known as cavitation. Vapor bubbles are formed near the surface and bubbles then collapse and disrupt the necrotic tissue. Ultrasound also has vasodilation effect which assists in healing. Low –frequency non-contact airborne ultrasound therapy is thought to be very effective in neuropathic diabetic foot ulcers.

(f) Extracorporeal shock wave therapy:

Extracorporeal shockwave therapy is very well known for urinary stone disease, but a few wound management surgeons use this therapy for wound healing also. Its role is for granulation tissue formation, re-epithelialization and vascular perfusion. There is recruitment of mesenchymal stem cells, anti-inflammatory as well as antimicrobial effect. The therapy is given once or twice weekly. 100–1000 shocks are given at 0.1 mj/mm².

(g) Compression therapy and devices.

Wounds of the extremity heal better if there is no edema or swelling. Elevation of the limb, pressure bandage helps wounds to heal. Two layer and four layer compression bandages, inelastic bandages, elastic stockings and pneumatic compression devices are useful for healing process. These are especially useful in venous stasis ulcers.

(h) Low level laser therapy:

Carbon dioxide laser is used as a debriding device for diabetic foot wounds. Low level laser therapy is used for wound healing where it stimulates metabolic process, activates macrophages and increases microcirculation.

Local Oxygen Therapy

Molecular oxygen is essential during different stages of inflammation and repair. Local oxygen therapy is aimed to correct low oxygen levels in chronic wounds. Local oxygen therapy increases growth factor expression especially that of vascular endothelial growth factor (VEGF). This in turn increases angiogenesis. Hyperbaric oxygen therapy (HBOT) is still better than local oxygen therapy.

There are so many devices available for local oxygen delivery. In local oxygen delivery devices, the pressure of oxygen is around 1.004–1.013 ATA. There is local diffusion of oxygen in superficial wound tissues. Increased oxygenation is

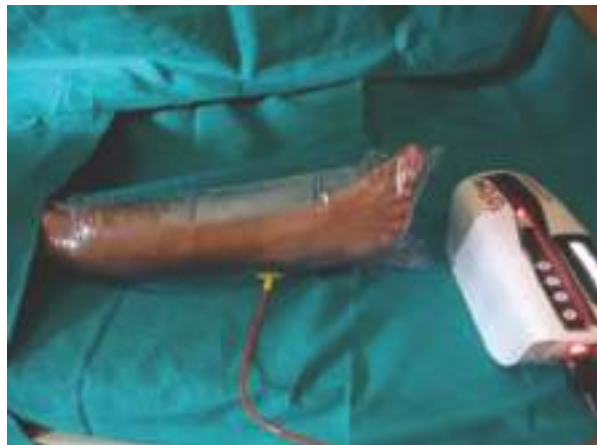thought to promote cell motility, extracellular matrix deposition, and angiogenesis [1, 2].

One portable device extracts oxygen from the air and delivers it through a thin tube to the oxygen delivery system, which is in direct contact with the wound surface. The continuous supply of oxygen ensures an oxygen rich environment around the wound area [3, 4]. The process is silent with no sensation of movement with a continuous flow of pure humidified oxygen. Patient can be maintained ambulatory with this type of oxygen delivery system. There are other devices like sleeve device where the limb is kept in an air tight sleeve where oxygen is circulated at a constant pressure [5].

Courtesy:Natrox wound
care .com



Local oxygen therapy,
sleeve device



Oxygen therapy is usually given 90 min per day and the treatment may be continued for 8–12 weeks. Wound has to be kept debrided and moist for local oxygen delivery. Some investigators consider it useful, but the benefits of topical oxygen are disputed. Topical oxygen therapy is not HBOT.

Indications

1. Diabetic and venous ulcers,
2. Gangrenous lesions,
3. Ischemic ulcers,
4. Before and after limb revascularization,
5. Anaerobic infection,
6. Frost bite

Examples: Natrox, Hyper-Box Topical Wound Oxygen System, Epiflow, TwO₂/O₃.

Comments

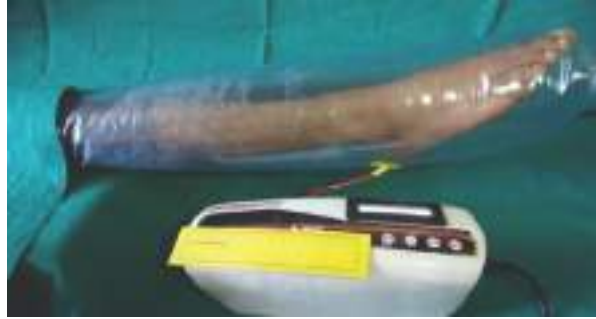Local oxygen therapy looks fancy, but experience says that it is not very effective. It cannot replace hyperbaric oxygen therapy. The effect that is observed may be because of moist wound environment it maintains rather than oxygen effect. It has not got universal acceptance, which implies that the results are not promising. The portable oxygen delivery device is also costly. It needs more comparative trials with hyperbaric oxygen therapy.

Ozone Therapy

Ozone is a colorless pungent odor gas made up of three oxygen atoms. It is a tri-atomic allotrope of oxygen. It is an oxidizing agent and is used in medical conditions since nineteenth century [6]. It has a very short half-life and remains active for 30 min in water and gets converted in to oxygen very fast.

It is a form of alternative medicine that increases the amount of oxygen in the body through the introduction of ozone. Various techniques have been suggested with benefits in cancer, AIDS and multiple sclerosis.

Local ozone therapy



Mechanism of Action

Ozone disinfects, oxidizes, deodorizes and decolorizes. It is a very strong oxidant and 3000 times more powerful disinfectant than chlorine.

Technique

The technique of giving peripheral ozone therapy is called bagging. The wound is exposed to ozone for up to two hours in an air tight bag. Ozone reach water or vegetable oil can also be applied on wound. It is a toxic gas and its safety is still not proved. The persons giving ozone therapy use three different routes for treatment with ozone, intra venous infusion with saline, per rectal therapy, direct in joints. For ulcers it is direct local application with an air tight bag.

Indications

1. Diabetic foot wound [7–9].
2. Ischemic wound.
3. Necrotising fasciitis.

Comments

Ozone therapy looks promising. As compared to hyperbaric oxygen therapy, it is economical. Results of HBOT are far better than ozone therapy. Ozone is a toxic gas so care should be taken to prevent hazardous outcome. Still more clinical trials are required.

Safe level for ozone is 0.1 ppm [0.2 mg/m³]. More than 5 ppm is dangerous to health and life.

Toxicity of Ozone

1. It can damage lungs.
2. Sometimes there is shortness of breath.
3. Some patients have symptoms of asthma.

Examples: $2\text{W}\text{O}_2/\text{O}_3$.

Hyper Baric Oxygen Therapy (HBOT)

Hyperbaric oxygen therapy is a very old therapy and is used since 1993 [10]. HBOT can be defined as a short term high dose oxygen inhalation diffusion therapy. Oxygen is administered through normal breathing at a pressure more than one atmosphere absolute (ATA). Usually 2–2.5 ATA pressure is used. At sea level, the air above the ground exerts total pressure of 760 mm of Hg on the earth surface. This is called 1 ATA. By increasing pressure and oxygen concentration there is increase in PO_2 and thereby additional oxygen molecules are dissolved in the patient's blood. It is estimated that 100% oxygen with HBOT can result in arterial oxygen tension more than 2000 mm Hg and oxygen tension in tissues of around 400 mmHg. HBOT treatment is given for 90–120 min. In 1962, the first hyperbaric chamber was created by British Physician, Henshaw. He named it Domicilium.

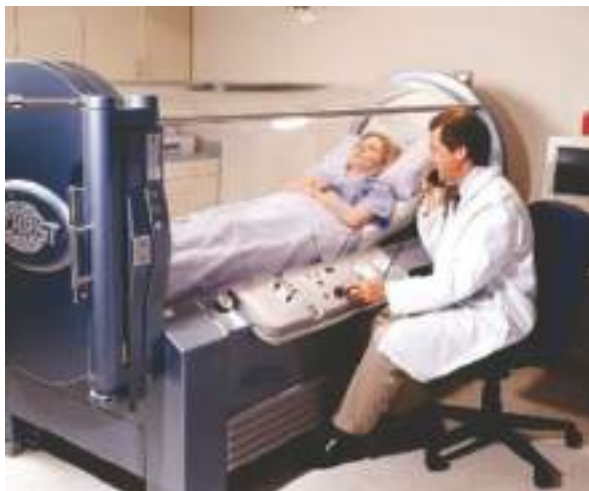Many decades ago mountain climbers noticed the inability of wound to heal and deep sea divers noted that their wounds healed fast when they were diving, this brought general appreciation of the importance of barometric pressure and oxygen in healing.

Indications

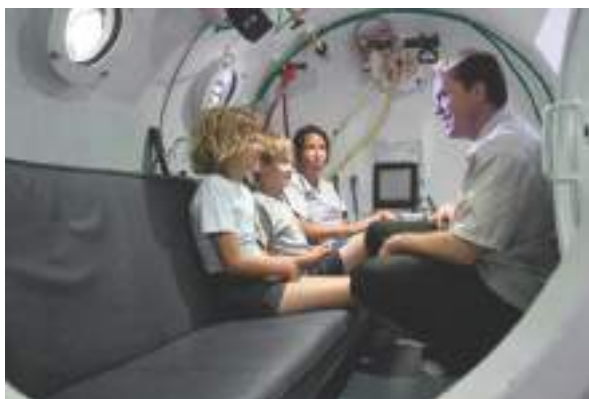It is observed that HBO may be beneficial as an adjunctive therapy for chronic non healing diabetic wounds [11].

Hyperbaric oxygen therapy is also useful in decompression sickness, air embolism, carbon monoxide poisoning [12–15], clostridial myonecrosis, crush injury, in patients of ischaemic ulcers, post endovascular interventions, in failures of any vascular interventions, traumatic ischemia [16–18], necrotizing fasciitis [19–21], gas gangrene and anaerobic infections, refractory osteomyelitis [22–26], radiation damage to soft tissue and hard tissue [27–32], compromised skin grafts or flaps and burns [33–35].

Monoplace chamber.
Courtesy: indiamart.com



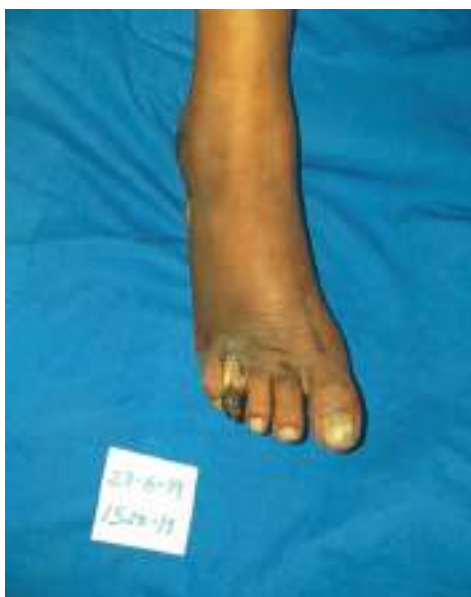Multiplace chamber.
Courtesy: Epidemicanswers.org



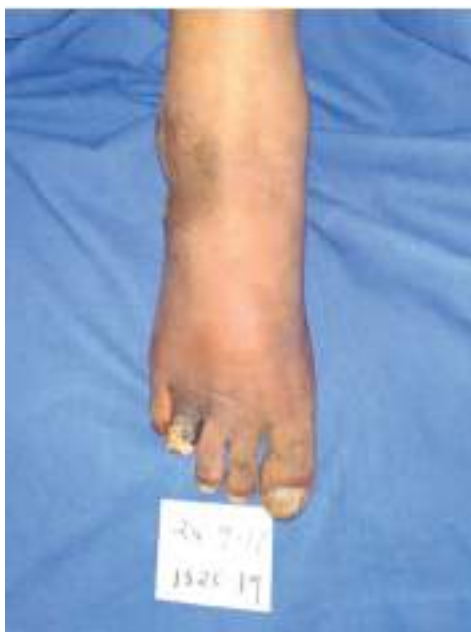Mechanism

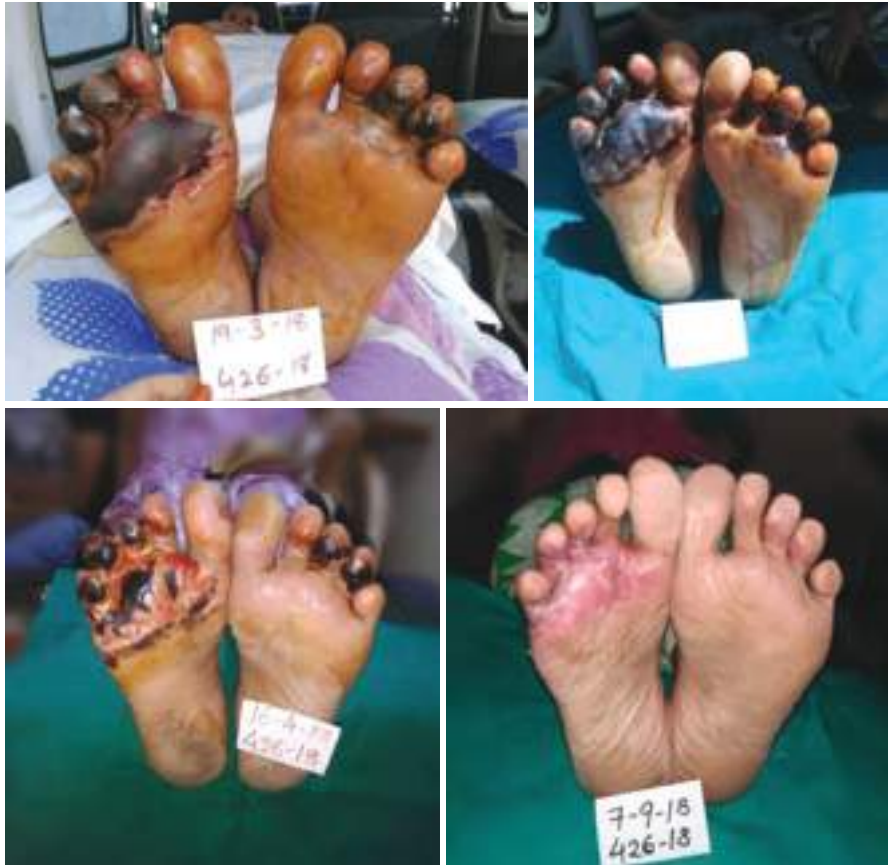HBOT increases the capacity of blood to carry and deliver oxygen to tissues. Microcirculation is also improved by increased erythrocyte flexibility caused by HBO.

Ischemic wound before HBOT



The wound after HBOT therapy





Result of HBOT therapy

During air breathing at normal atmospheric pressure, haemoglobin is saturated to about 97% when leaving the pulmonary circulation from lungs and only 3 ml of oxygen is dissolved in blood per liter. If 100% oxygen is inhaled, 15 ml oxygen gets dissolved in blood per liter. With HBOT at 2.5 ATA, almost 60 ml of oxygen is dissolved in each liter of blood. Oxygen in soluble form in blood can more easily reach physically obstructed areas where red cells cannot reach.

Leukocytes kill bacteria most effectively when supplied with abundant oxygen. Phagocytosis stimulates almost 25 fold increase in oxygen consumption known as respiratory burst. Doctor and colleagues have shown rapid sterilization of diabetic wounds using HBO [36] .

Hyperbaric oxygen therapy is followed by peripheral vessel constriction, but in ischaemic tissues it causes vasodilation.

Topical application of oxygen is not hyperbaric therapy and has shown no significant effect on wound healing.

Hyperbaric Therapy Chamber

There are two types of hyperbaric chambers.

- (a) Monoplace chamber –In this chamber one patient can be accommodated.
- (b) Multiplace chamber –In this chamber more than one patients can be accommodated at a time.

Side Effects

Usually there is no side effect of HBOT. CNS side effects are rarely seen at pressure below 2 ATA. Risk of oxygen convulsions significantly increases when pressure exceeds 3 ATA. Grand mal seizures are possibly related with interference with gamma amino butyric acid (GABA) metabolism [37–39]. Usually oxygen pressure is maintained below 2.8 ATA. Oxygen seizures occur in 1 in 10,000–12,000 treatments [40]. They are self-limiting and treated by cessation of oxygen therapy. Barotrauma to ears or sinuses, pneumothorax are sometimes reported. Pulmonary complications are rare (1 in 15,000 treatments)

Applied Science

In human tissues, inter capillary distance varies. In muscle, it is very short distance; in tendons, fascia and subcutaneous tissues it is more. In diabetic microvascular disease capillary function is declined and distance between the capillaries is increased.

HBOT reduces tissue hypoxia by oxygen diffusion to a longer distance away from the capillaries.

In 1960, Boerema and Colleagues showed that the life can be maintained in pigs in the absence of erythrocytes using HBOT.

Comments

Hyperbaric oxygen therapy is a very useful therapy for post revascularization residual ischemia of limbs. If revascularization is not possible, if patient does not agree, if revascularization fails then it is a very useful therapy, though the cost and duration of treatment is a problem. Local oxygen therapy and ozone therapy are tried but there is no proved evidence of its positive results. Hyperbaric wound therapy should not be advised without doing adequate surgical intervention, debridement and revascularization.

Negative Pressure Wound Therapy: (NPWT)

It was a difficult task to do frequent dressings in badly exuding wounds. The idea of applying vacuum gave more comfort to patients with such wounds. It was a novel idea to remove the exudates with the help of a suction machine.

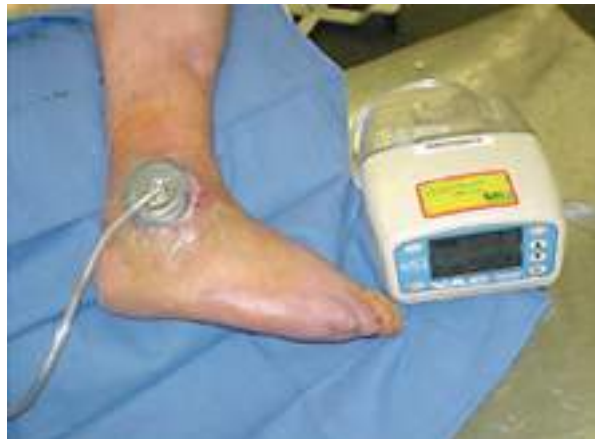There is bad smell and spoiling of bed sheets and clothes in some exuding wounds. Negative pressure wound therapy is intended to remove discomfort of the patient and to reduce frequency of change of dressings [41].

Negative Pressure Wound Therapy unit applies gentle negative pressure to the wound through a tube and foam or sponge. These are applied to the wound over a dressing and sealed in place with a plastic film to create vacuum. The sponge is replaced every 2–3 days. Exudate from the wound is sucked along the tube to a disposable collecting chamber.

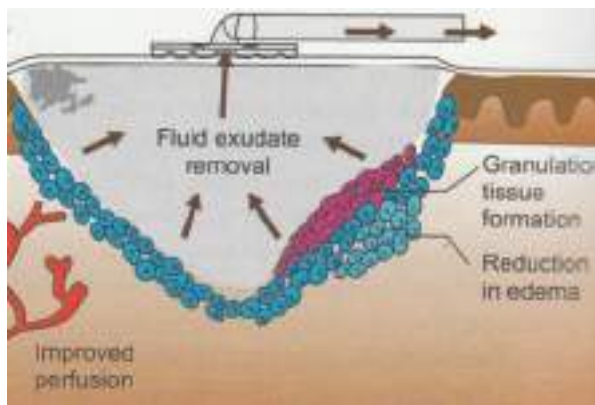
Equipment

1. Specialized foam dressing: Multiple types of foams are available. Commonly used foam is reticulated open cell foam, which is hydrophobic and porous. Silver foams are also available. The porosity of the foam is usually between 100 and 600 μm .
2. Plastic tubing.
3. Canister.
4. Computerized treatment unit.

Negative pressure
wound therapy



Mechanism of action



Mechanism

Negative pressure improves the local blood supply and stimulates granulation (Banwell and TEOT 2003) [42, 43]. The sponge size reduces by 80% when machine is started after the dressing is done. Granulation tissue is better formed over bone and tendon with the help of NPWT. It is thought that there is reversal of tissue lymphatic flow with NPWT, so lymphatic spread of infection is also reduced to a certain extent. It also reduces bacterial colonization, diminishes edema and interstitial fluid [44, 45]. NPWT stretches the cells and increases cell proliferation. It also causes tissue hypoxia around the wound edge which increases the expression of VEGF [vascular endothelial growth factor], which in turn increases angiogenesis.

Instillation tube is added to the therapy unit in new versions of vacuum therapy machine to facilitate the application of topical antibiotics. The instillation materials used are normal saline, biguanides, and hypochlorous acid solution. The newer machines have both irrigation suction device.

There is some modification available, that is regulated oxygen-negative pressure therapy [RO-NPT]. Oxygen is delivered along with vacuum to prevent anaerobic infection.

Uses

Negative Pressure Wound Therapy was first time approved by US FDA in 1995. In Diabetic foot wound the application of continuous negative pressure of -125 to -75 mm of Hg has been found useful in promoting healing [46–48]. It can be used in non-diabetic wounds, pressure sores, traumatic wounds, infected surgical wounds, and in wounds where bone is exposed. Incisional NPWT is also used by many in orthopaedic and general surgical operations with excellent results. In transmetatarsal

amputations it can be used with good results. NPWT is also used for dressings after skin grafting.

Advantages

- (a) It is safe and painless for wound.
- (b) It does efficient cleaning of the wound.
- (c) It reduces frequency of painful dressings.
- (d) It reduces hospital stay.
- (e) It has advantage of better control of infection with local delivery of antiseptics.
- (f) It prevents secondary infection in the ward.

Contra Indications

Malignancy, untreated osteomyelitis, enteric/non-enteric and unexplored fistula, necrotic tissue with eschar, exposed blood vessels and nerves and anastomotic sites are contraindications for use of negative pressure wound therapy.

Examples: Pico, KCI.

Comments

Selection of dressing material and different therapies is very important. Wounds with unstable ankle, wounds with very poor circulation, very large wounds and very dry wounds are not the right candidates for applying NPWT. It should be remembered that principles of managing a wound does not change with availability of NPWT machine, meaning there by, when joint is exposed, when tendons are seen in ulcer bed the principle of immobilization should not be forgotten otherwise disappointing result will be there with NPWT.

It is very costly and definitive surgical therapy is always the priority. NPWT is not the substitute for revascularization, mechanical debridement and surgical debridement. Vacuum therapy is useful in badly exudating wounds and borderline ischemic wounds. Availability of therapy machine is not the indication to use.

Electric Therapy

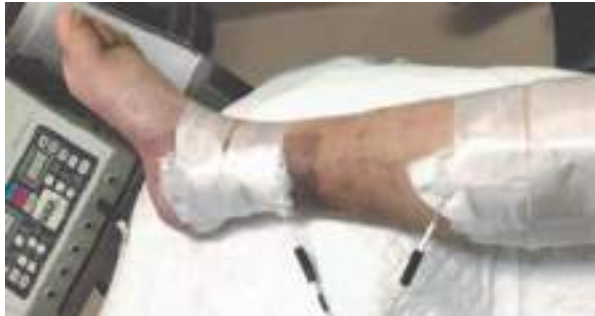Electric therapy is the use of electric energy for medical purposes. Electric therapy is used in medical conditions like neurological diseases and wound healing. So many alternative medical devices are given the name of electric therapy. In ancient times electric therapy was used to treat pain and improve blood circulation. In eighteenth century an electrotherapist John Wesley, used electrical stimulation in

suspected angina patients, in headache and feet pain. Currently encouraging results are observed in wound healing with electric therapy.

Normal human skin is found to produce steady electrical potential. On injury to epithelium, endogenous electrical current is produced. This wound induced electrical field regulates cell division. Electric therapy machine works by enhancing wound induced electrical fields [49].

Electrical stimulation may offer a unique treatment option to heal complicated and recalcitrant wounds, improve flap and graft survival, and even improve surgery results. Electrical stimulation has been suggested to reduce infection, improve cellular immunity, increase perfusion, and accelerate wound healing.

Electric therapy apparatus.
(Courtesy: [semanticscholar.org](https://www.semanticscholar.org))



- Electrical stimulation is delivered through a machine which has two conductive electrodes, the cathode and the anode. It is not a form of radiation or heating, but uses an electromagnetic field with the aim of stimulating healing. One electrode is applied on the wound with wet gauze and the other near the wound on healthy skin. It is given five times in a week for up to 30 min per day.

Effects of Electrical Stimulation

Electrical stimulation is believed to restart or accelerate wound healing by imitating the natural electrical current that occurs in injured skin. Electrical stimulation decreases the doubling time of fibroblasts and endothelial cells in culture. Electrical stimulation applied to injured tissue increases the migration of neutrophils and macrophages and stimulates fibroblasts. It also reduces pain, improves local circulation and reduces edema.

Effect of electrical stimulation on wound healing

- It modifies endogenous bioelectricity
 - It activates inflammatory cells
 - It attracts connective tissue cells
 - It stimulates cell replication
 - It improves cell biosynthesis
 - It inhibits infectious microorganisms
-

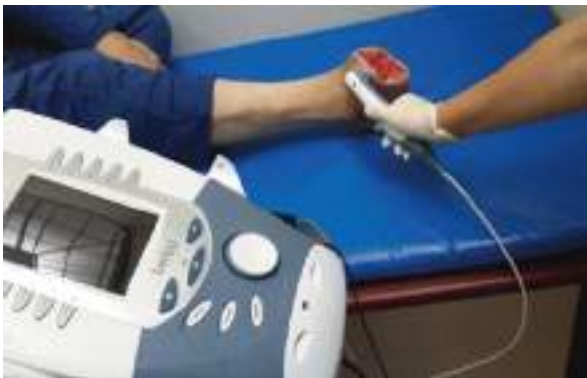Indications of Electric Therapy

Electric therapy is indicated in venous ulcers [50], pressure ulcers [51–53], diabetic foot ulcers [54], vasculitic ulcers and ischaemic ulcers. Other than wound management, electric therapy is used in medical science for relief of pain and stiffness of joints, to prevent muscle atrophy, relieve edema of lymphatic origin, stimulate retina in cases of retinitis pigmentosa.

Ultrasonic Therapy for Wound Debridement and Healing

Ultrasound remains a controversial modality in wound care. It transmits thermal and non-thermal waves through tissue by converting electrical waves into sound waves. This is not a mechanical or surgical modality, it is included in this segment because its role is for debridement and wound healing.

Ultrasonic therapy uses acoustic energy to remove devitalized tissue from the wound bed and to promote wound healing. Limited evidence suggests that non-contact, low hertz frequency ultrasonic therapy promotes wound healing when used in conjunction with standard wound therapy. It removes particulate matter and reduces bacterial counts. There is hardly any blood loss. Low-Frequency noncontact Airborne Ultrasound Therapy is a known therapeutic modality to treat neuropathic diabetic foot ulcers. It is known modality of treatment for infected as well as non infected diabetic foot ulcers. Indian study by Ashu Rastogi and Anil Bhansali, more than 50% reduction in wound area was observed in 97.1% as compared to 73.1% in control group (International journal of lower extremity wounds 2019, vol.18(1) 81–88).



Ultrasonic therapy. (Courtesy: sicmedi.com)

Mechanism of Action

Ultrasonic debridement works by the mechanism known as cavitation. Saline is used as a transfer medium and there is expansion and collapse of the air bubbles.

This causes cavitation, fragmentation and erosion of dead tissues. Another theory is suggestive of antiseptic effect of ultrasound and conversion of chronic wounds into acute wounds. It also stimulates healing of the wound by promoting cell division, angiogenesis, release of growth factors and ultimately stimulation of collagen synthesis [55].

Ultrasonic therapy has some good effect on wound healing. The effects are both thermal and nonthermal. The ultrasonic machine provides ultrasonic waves of both 1 mHz and 3 mHz frequency. 3 mHz is preferred for dermal wound healing purpose and 1 Mhz is used for deep lacerations or periwound skin [56, 57]. Duration of treatment is 2 min for each area and for a total duration of 5–10 min.

The aim is to produce a thermal effect for vasodilation and increased tissue oxygen levels. The ultrasound probe head should be 1.5 or 2 times the size of the area to be treated. Aqueous medium is applied to the transducer and is moved in a slow circular motion around the treated area.

Ultrasound can debride biofilm very well. It is an assistant to sharp debridement.

Precautions and Contraindications

It is contraindicated in malignancies, acute infection, ischemic areas and vascular disease and DVT. It should not be used near electronic implants or prosthesis and during pregnancy. It is contraindicated over eyes, genital areas, abdominal area and exposed neural tissue.

- It should be avoided in case of thrombo-embolic diseases.
- It should be avoided in patients with pacemaker.
- Precautions should be taken with sensory impairment.
- Ultrasound should be terminated if there is increased pain.
- Like electric therapy and laser therapy, ultraviolet therapy is also given for chronic wounds with good effects [58].

Comments

Electrical stimulation is a good adjunctive therapy. The therapy has no known adverse effects. The therapy is safe and easy to use. It decreases bacterial infection, increases local perfusion, and accelerates wound healing. Electrical stimulation offers a unique treatment option to heal complicated and recalcitrant wounds, improves flap and graft survival, and even improves surgery results. This is an approach that can be applied in the operating room and used throughout the recovery process. Electrical stimulation is a simple, inexpensive intervention to improve surgical wound healing. More clinical trials are needed to help understand the dosing, timing, and type of electrical stimulation to be used.

Besides accelerating the healing speed of open wounds, low frequency ultrasound is an effective early treatment for suspected deep-tissue injuries. In vitro and

in vivo studies have shown therapeutic efficacies of US techniques in different wounds. However, there is not an exact dose-response for clinical applications of US treatments in different wounds. Considering the promising therapeutic effects of US techniques on the treatment of different wounds, one can expect that US will be a new standard for early treatment of some kinds of wounds. However, to reach such a standard treatment, further studies are required to shed light on the exact mechanism of action and also to provide exact dose response of therapeutic ultra sound.

Extracorporeal Shock Wave Therapy: (ESWT)

Extracorporeal shock wave therapy is well known in urinary stone disease since many years. Its role in wound management is a recent understanding.

Method: It is an outdoor procedure. The wound is debrided thoroughly. The therapy is usually given weekly or two weekly for three to four sittings. The wound size is measured and accordingly treatment is planned. Usual application is 100–1000 shocks/cm² at 0.1 mJ/mm². The wound dressing is done with moisture retentive material.

Mechanism of Action

Extracorporeal Shock Wave Therapy acts through mechano-transduction which produces benefit through complex biological pathways. This therapy is thought to be having acceleration of healing in chronic wounds [59]. Potential mechanisms, include initial neovascularization with ensuing durable and functional angiogenesis. Furthermore, recruitment of mesenchymal stem cells, stimulated cell proliferation and differentiation, and anti-inflammatory and antimicrobial effects are observed.

Several experimental and clinical studies show efficacy for extracorporeal shock wave therapy as means to accelerate tissue repair and regeneration in various wounds [60, 61].

ESWT can be used as an adjuvant therapy for healing chronic and acute soft tissue wounds [62–64]. Substantial supporting clinical evidence confirms ESWT utility and the range of positive results, such as completed wound closure and re-epithelialization, enhanced tissue granulation, reduced necrotic fibrin tissue, improved blood perfusion and angiogenesis, reduced period of total wound treatment, and decreased necessity of antibiotic treatment.

In a clinical trial, ESWT was found to be better than HBOT [65].

Comments

Extracorporeal shockwave therapy is very well known for urinary stone disease. Its role in wound management is known by only a few wound management consultants. It has a role in better granulation tissue formation, re-epithelialization, and vascular perfusion. It requires more clinical trials.

Compression Bandage and Devices

Venous stasis ulcer is difficult ulcer to treat. The original open surgical procedure is indicated in patients with many tortuous veins. Endovenous procedure is a gold standard treatment at present. In venous stasis ulcers, post thrombotic leg ulcers and in patients refusing endovenous surgery, whatever we apply does not work. It requires mechanical assistance in the form of varicose vein stockings or two layer or four layer compression bandage [66] or pneumatic lymphatic compression device [67]. Varicose vein stockings have more of preventive role rather than therapeutic role to heal venous stasis ulcer. The ulcer would respond to required types of local dressing materials only if mechanical assistance is given. In this case four layer compression bandage is an assistant to dressing material.

Four layer compression bandages deliver around 40 mmHg pressure at the ankle which gradually reduces to 17 mmHg at the knee. The pressure is maintained for a period of one week and capacity to absorb exudates is sufficient for keeping the dressing for 7 days [68].

The characteristic of compression bandage is decided by static stiffness index (SSI). SSI is defined as the difference between working pressure and pressure at rest. This has got relevance in treatment of venous ulcers and lymphoedema. Previously only four layer bandages were available but now 2 layer compression bandages are also available.

Self-care **inelastic compression** is a latest compression therapy for venous stasis and lymphoedema. It is comfortable to use, patients themselves can apply. Even when the swelling reduces patient can re adjust the amount of compression.

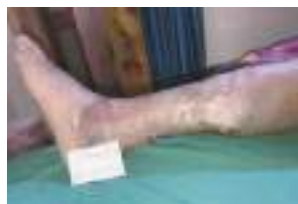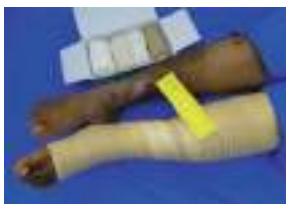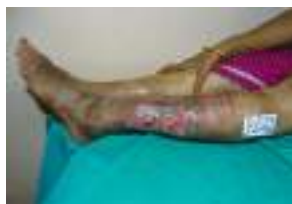Pneumatic compression device is another revolutionary treatment in compression therapy. It can be self-applied and underlying wound can easily be managed. It does not sleep or wrinkle and compression can very well be maintained with reduction in swelling [69–72].

All venous ulcer patients have more or less allergic skin problem along with ulceration. Zinc oxide paste bandage is useful to control eczema and it helps in ulcer healing.

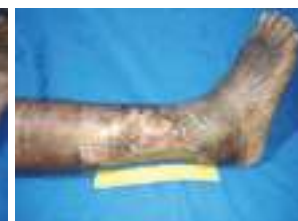
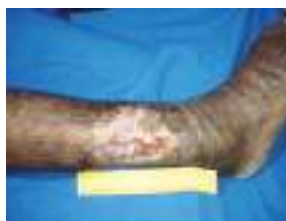
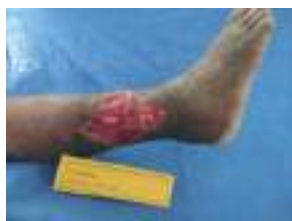Indications

1. Venous stasis ulcer
2. Post thrombotic ulcer
3. Failure of endovenous procedure
4. Lymphoedema
5. Any post-operative residual limb edema



4 Layer bandage:

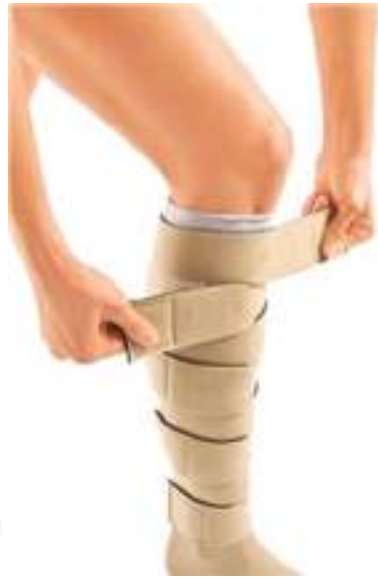
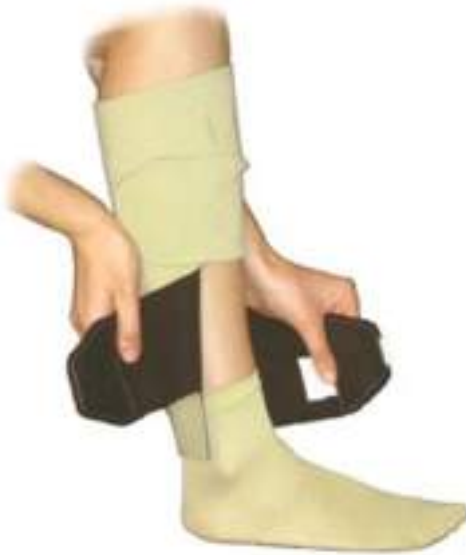
Result of four layer compression bandage

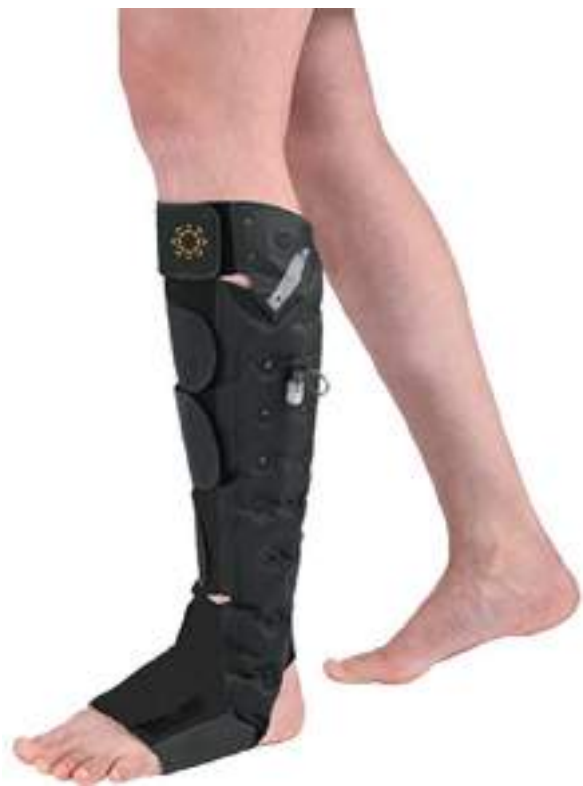Zinc Bandage to Be Applied
Before Four Layer
Compression Bandage.



2 Layer Bandage (KOB)



Inelastic Compression



Aero Wrap Compression
Mechanism of action of compression therapy [73]

Sr. No.	Category	Physiological effect	Potential direct and indirect benefits
1.	Hemodynamic	↓ Venous stasis ↑ Flow velocity in deep veins ↑ Fibrinolysis	↓ Venous pressure
		↑ Blood volume flow ↑ Endothelial shear stress ↓ A-V pressure gradient	↑ Venous emptying ↓ Stasis ↓ Edema ↑ Arterial inflow
		↑ Shear stress/on endothelial strain cells	↑ Fibrinolysis ↑ Vasodilation ↓ Thrombosis
2.	Fibrinolytic	↑ Fibrinolytic activity	↑ Endogenous fibrinolytic activity
		↓ tPA (tissue plasminogen activator) antigen ↑ tPA activity ↓ PAI (plasminogen activator inhibitor) -1 antigen ↓ PAI-1 activity ↓ FVIIa (factor 7 a) levels ↑ TFPI (tissue factor pathway inhibitor) levels	↑ Thrombosis ↓ Intravascular coagulation ↓ Hypercoagulability

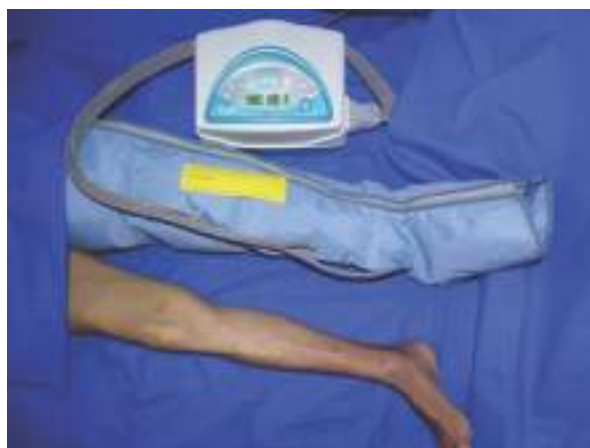Sr. No.	Category	Physiological effect	Potential direct and indirect benefits
3.	Tissue oxygen tension	\uparrow TcPO ₂ levels \downarrow Interstitial fluid volume \downarrow Venous stasis	\uparrow Oxygen diffusion barrier \downarrow Leg edema \uparrow Skin temperature
4.	Edema	\downarrow Arteriovenous shunting \downarrow Edema	\uparrow Capillary perfusion

Edema of the limb increases the intra vascular pressure and thereby reduces skin oxygen tension. Compression therapy reduces interstitial fluid volume and venous stasis. TcPO₂ is more in normal individuals as compared to that in patients with edema and venous stasis. This is the understanding how compression therapy and four layer bandage help for healing of leg wounds.

Lymphatic Compression Device

For extremity wounds with edema lymphatic compression device is a logical answer [74]. For venous stasis ulcers lymphatic compression therapy would add to the effect of four layer compression bandage. The machine is applied for 1 h a day with a pressure of 80–200 mm of Hg as per the tolerance and comfort of patient. In venous and lymphatic diseases the compression device pushes lymph and blood from below upwards (toes to thigh) and in peripheral arterial disease the same device can push more blood by sequential compression from thigh to toes.

Sequential Compression Therapy



Examples:

Velfour (DMP), 4-LB (dynamic techno medicals), Roselastic 530 (KOB), In elastic compression (CIRCAID), Aero wrap (SunScientific).

Comments

Wounds of extremities heal better if there is no edema and swelling of the extremity. Elevation and rest of the extremity does majority of the work. In venous stasis and lymphatic stasis elasto crepe bandage, elastic compression stockings help in reducing edema and thereby healing the wounds. Four layer compression bandage proves better in healing of venous stasis ulcer. Multiple small ulcers with lymphorrhoea can better be treated with sequential compression therapy machine. Venous stasis ulcers are also benefited with pneumatic compression device as well as four layer compression bandages.

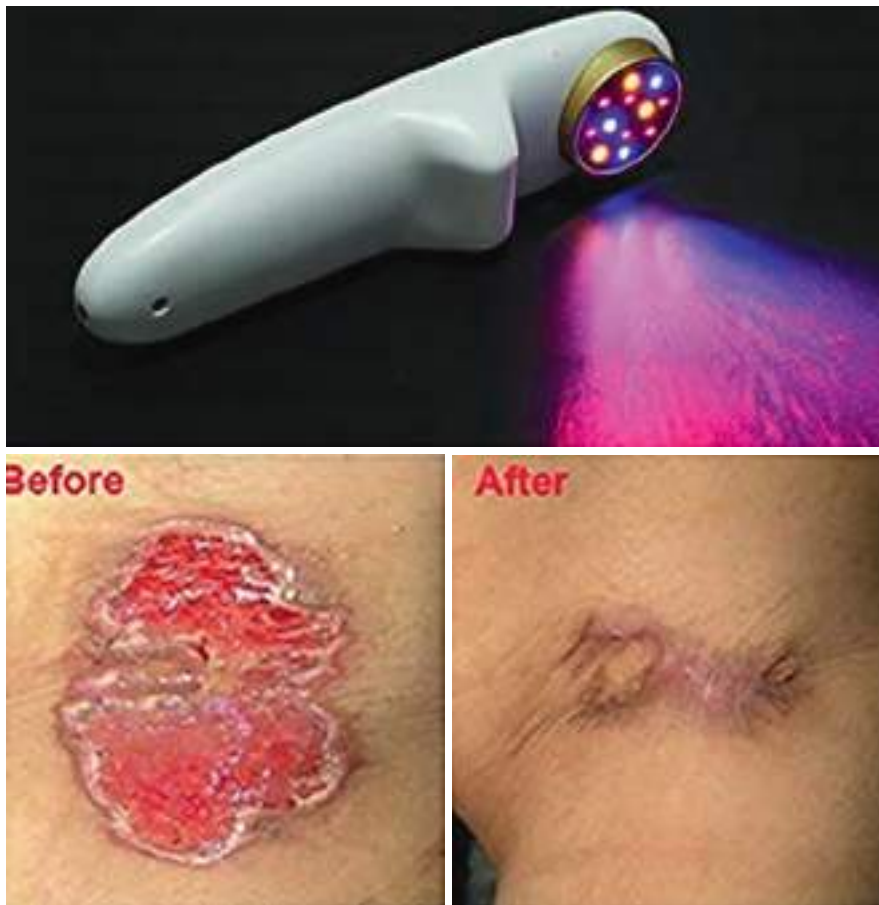Low Level Laser Therapy: (LLLT)

The power of one milliwatt per square cm or less is known as low level or cold laser. The helium-neon laser is such a cold laser and it does not generate heat. Two techniques are used for therapy, contact and non-contact. Contact therapy is used for wound margin and noncontact therapy is used for wound bed.

The wound is exposed to low level laser therapy which stimulates metabolic process. It activates microcirculation and macrophages. This in turn supplies more oxygen and facilitates macrophages to kill bacteria. It reduces inflammatory reaction, induces increased collagen deposition and increases proliferation of myofibroblasts [75]. Cold laser is believed to help wound healing and nerve regeneration. Usually the therapy is given for 15 min a day for consecutive five days in a week for 10–12 weeks in chronic ulcers.

Low Level Laser Therapy is an effective treatment for enhancing wound healing of abrasions [76]. The effect is photochemical and biostimulatory and not the effect of light. It also facilitates wound contraction of untreated wounds on the same area, suggesting an indirect effect on surrounding tissues. Further controlled data are necessary to determine the efficacy of LLLT in facilitating healing.

Carbon dioxide laser is also used as a debriding device in diabetic foot wounds. It is not low level laser therapy.



Low Level Laser Therapy Equipment. (Courtesy: [aliexpress.com](https://www.aliexpress.com))

Indication

1. Diabetic foot ulcer.
2. Venous ulcer [77, 78].
3. Post irradiation ulcer.

Contraindications

Cold laser therapy should not be used over eyes, malignant tumors, and in patients sensitive to light.

Comments

Low dose laser therapy is not a routine therapy in majority of centres. The centres exclusively dealing with wound therapy use it, but comparative clinical data is not available.

References

1. Allen DB, Maguire JJ, Mahdavian M, et al. Wound hypoxia and acidosis limit neutrophil bacterial killing mechanisms. *Arch Surg.* 1997;132:991–6.
2. Jonsson K, Jenson JA, Goodsen WH, et al. Tissue oxygenation, anemia and perfusion in relation to wound healing in surgical patients. *Ann Surg.* 1991;214(5):605–13.
3. Sayadi LR, Banyard DA, Ziegler ME, Obagi Z, Prussak J, Klopfer MJ, Evans GRD, Widgerow AD. Topical oxygen therapy & micro/nanobubbles: a new modality for tissue oxygen delivery. *Int Wound J.* 2018;15(3):363–74.
4. Moen n, Ugland H, Strömberg N, Sjöström E, Karlson A, Ringstad L, Bysell H, Amiry-Moghaddam M, Haglerød C. Development of a novel in situ gelling skin dressing: Delivering high levels of dissolved oxygen at pH 5.5. *Health Sci Rep.* 2018;1(7):e57.
5. Copeland K, Purvis AR. A retrospective chart review of chronic wound patients treated with topical oxygen therapy. *Adv Wound Care.* 2017;6(5):143.
6. Bocci VA. Scientific and medical aspects of ozone therapy. State of the art. *Arch Med Res.* 2006;37:425–35.
7. Martinez-Sanchez G, Al-Dalain SM, Menendez S, Re L, Giuliani A, Candelario-Jalil E, Alvarez H, Fernandez M. Therapeutic efficacy of ozone in patients with diabetic foot. *Eur J Pharmacol.* 2005;523:151–61.
8. Elvis AM, Ekta JS. Ozone therapy: a clinical review. *J Nat Sci Biol Med.* 2011;2(1):66–70. <https://doi.org/10.4103/09769668.82319>. [PMC 3312702. PMID 22470237](https://pubmed.ncbi.nlm.nih.gov/22470237/)
9. Wainstein J, Feldbrin Z, Boaz M, Harman-Boehm I. Efficacy of ozone-oxygen therapy for the treatment of diabetic foot ulcers. *Diabetes Technol Ther.* 2011;13:1255–60.
10. Foreman C: The FDA and HBO. Presented at Hyperbaric Medicine 1998 Advanced Symposium, University of South Carolina School of Medicine, 1998.
11. Wang C, Schwaitzberg S, Berliner E, Zarin DA, Lau J. Hyperbaric oxygen for treating wound: a systematic review of the literature. *Arch Surg.* 2003;138:272–9.. discussion 280
12. Feldmeier JJ, Hopf HW, Warriner RA, et al. UHMS position statement: Topical oxygen for chronic wounds. *Undersea Hyperb Med.* 2005;32(3):157–68.
13. Davis JC. Refractory osteomyelitis. In: Davis JC, Hunt TK, editors. *Problem wounds: the role of oxygen.* New York: Elsevier; 1988. p. 125–42.
14. Boerema I, Meyne NG, Brummelkamp WH, et al. Life without blood. *Ned Tijdschr Geneesk.* 1960;104:949–54.
15. Brummelkamp WH. Consideration on hyperbaric oxygen therapy at three atmosphere absolute for clostridial infection type welchii. *Ann NY Acad Sci.* 1965;117:688–99.
16. Thom SR, Taber RL, Mendiguren II, et al. Delayed neuropsychologic sequelae after carbon monoxide poisoning: Prevention by treatment with hyperbaric oxygen. *Ann Emerg Med.* 1995;25(4):474–80.
17. Tarborough OD, Behnke AR. The treatment of compressed air illness utilizing oxygen. *J Ind Hyg Toxicol.* 1939;21(6):213–8.
18. Hart GB, Lamb RC, Strauss MB. Gas gangrene. *J Trauma.* 1983;23(11):991–1000.
19. Bouachour G, Cronier P, Gouello JP, et al. Hyperbaric oxygen therapy in the management of crush injuries: A randomized double blind placebo controlled clinical trial. *J Trauma.* 1996;41(2):333–9.

20. Strauss MB, Hart GB. Crush injury and the role of hyperbaric oxygen. *Top Emerg Med.* 1984;6:9–24.
21. Tan CM, Im MJ, Myers RA, Hoopes JE. Effects of hyperbaric oxygen and hyperbaric air on the survival of island skin flaps. *Plast Reconstr Surg.* 1984;73(1):27–30.
22. Hunt TK, Ninkovic J, Zederfeldt BH, Silver IA. Oxygen in wound healing enhancement: cellular effects of oxygen. In: Davis JC, Hunt TK, editors. *Hyperbaric oxygen therapy.* Bethesda, MD: Undersea Medical Society; 1988. p. 111–22.
23. Baffer DJ. Pure and mixed aerobic and anaerobic soft tissue infections. *Hypereb Oxygen Rev.* 1985;6:65–96.
24. Gozal D, Ziser A, Shupak A, et al. Necrotizing fasciitis. *Arch Surg.* 1986;121(2):233–5.
25. Riseman JA, Zamboni WA, Curtis A, et al. Hyperbaric oxygen therapy for necrotizing fasciitis reduces mortality and the need for debridements. *Surgery.* 1990;108(5):847–50.
26. Davis JC. Hyperbaric oxygen therapy. *Intensive Care Med.* 1989;4:555–7.
27. Davis JC. Chronic non hematogenous osteomyelitis treated with adjuvant hyperbaric oxygen. *J Bone Joint Surg.* 1996;68:A1210–7.
28. Mader JT, Brown GL, Guckian JC, et al. A mechanism for the amelioration by hyperbaric oxygen of experimental staphylococcal osteomyelitis in rabbits. *J Infect Dis.* 1980;142(6):915–22.
29. Morrey BF, Dunn JM, Heimbach RD, Davis J. Hyperbaric oxygen and chronic osteomyelitis. *Clin Orthop Relat Res.* 1979;144:121–7.
30. Slack WK, Thomas DA, Perrins D. Hyperbaric oxygenation chronic osteomyelitis. *Lancet.* 1965;14:1093–4.
31. Feldmeier JJ, Heimbach DA, Davolt DA, Brakora MJ. Hyperbaric oxygen as an adjunctive treatment for severe laryngeal necrosis: A report of nine consecutive cases. *Undersea Hyperb Med.* 1993;20(4):329–35.
32. Feldmeier JJ, Heimbach RD, Davolt DA, et al. Hyperbaric oxygen as an adjunctive treatment for delayed radiation injury of the chest wall: A retrospective review of twenty- three cases. *Undersea Hyperb Med.* 1995;22(4):383–93.
33. Kaelin CM, Im MJ, Myres RA, et al. The effects of hyperbaric oxygen on free flaps in rats. *Arch Surg.* 1990;125(5):607–9.
34. Zamboni WA, Roth AC, Russell RC, et al. The effect of acute hyperbaric oxygen therapy on axial pattern skin flap survival when administered during and after total ischemia. *J Reconstr Microsurg.* 1989;5(4):343–7.; discussion 349–350.
35. Zatz R, Brenner BM. Pathogenesis of Diabetic microangiopathy: The hemodynamic view. *Am J Med.* 1986;80(3):443–53.
36. Doctor N, Pandya S, Supe A. Hyperbaric oxygen therapy in diabetic foot. *J Postgrad Med.* 1992;38(3):112–4.
37. Wood JD. GABA and oxygen toxicity: a review. *Brain Res Bull.* 1980;6:777–80.
38. Wood JD, Peesker SJ, Rozdilsky B. Sensitivity of GABA synthesis in human brain to oxygen poisoning. *Aviat Space Environ Med.* 1975;46(9):1155–6.
39. Yoneda Y, Kuriyama K, Takahashi M. Modulation of synaptic GABA receptor binding by membrane phospholipids: Possible role of active oxygen radicals. *Brain Res.* 1985;333(1):111–22.. (levin's page no 362)
40. Clark J. Side effects and complications. Kensington, MD: Undersea and Hyperbaric Medical Society; 2003.. levin's page no 362
41. Armstrong DG, Attinger CE, Boulton AJM, et al. Guidelines regarding negative pressure wound therapy in the diabetic foot: result of the tuscon expert consensus conference (TECC) on V.A.C. Ostomy Wound Manage. 2004;50(4 Suppl B):3s–27s.
42. Banwell PE, Teot L. Topical negative pressure (TNP): the evolution of a novel wound therapy. *J Wound Care.* 2003;12:22–8.
43. Armstrong DG, AJM B, Banwell P. Topical negative pressure: management of complex diabetic foot wounds. Oxford: Oxford Wound Healing Society; 2004.
44. Zgonis T, Stapleton JJ, Girard-Powell VA, et al. Surgical management of diabetic foot infections and amputations. *AORN J.* 2008;87(5):935–46.

45. Morykwas MJ, et al. Stat of basic research and physiologic foundation. *Plast Reconstr Surg.* 2006;1117(Supplement):121S–126.
46. Armstrong DG, Attinger CE, Boulton AJ, et al. Guidelines regarding negative wound therapy (NPWT) in the diabetic foot. *Ostomy Wound Manage.* 2004;50(4B Suppl):3S.
47. Blitz NM. Vacuum assisted closure in lower extremity reconstruction. In: Dockery GL, Craford ME, editors. *Lower extremity soft tissue and cutaneous plastic surgery.* Edinburgh: Saunders; 2006. p. 343–58.
48. V.A.C. Ulta™ Negative pressure wound therapy system. <https://www.kci1.Com/KCL1/vac-ultra>. Accessed 5 Jan 2013.
49. Kloth LC, McCullough JM, Feeder JA. Chapter 12, 13 and 14, wound healing: alternatives in management. Philadelphia: F A Davis company; 1990. p. 221–9.S.
50. Aziz Z, Cullum N, Flemming K. "Electromagnetic therapy for treating venous leg ulcers"(PDF). *Cochrane Database Syst Rev.* 2015;7:CD002933. <https://doi.org/10.1002/14651858.CD002933.pub6..> PMID 26134172
51. Aziz Z, Flemming K. Electromagnetic therapy for treating pressure ulcers. *Cochrane Database Syst Rev.* 2015;9:CD002930. <https://doi.org/10.1002/14651858.CD002930.pub6..> PMID 26334539
52. Reddy M. Pressure ulcers. *BMJ Clin Evid.* 2011;2011:3217823.. PMID 21524319
53. Cullum N, Petherick E. Pressure ulcers. *BMJ Clin Evid.* 2008;2008:2907959.. PMID 19450317
54. Barnes R, Shahin Y, Gohil R, Chetter I. Electrical stimulation vs. standard care for chronic ulcer healing: a systematic review and meta-analysis of randomised controlled trials. *Eur J Clin Investig.* 2014;44(4):429–40. <https://doi.org/10.1111/eci.12244..> PMID 24456185
55. Michailidis L, Williams CM, Bergin SM, Haines TP. Comparison of healing rate in diabetes-related foot ulcers with low frequency ultrasonic debridement versus non-surgical sharp debridement: a randomised trial protocol. *J Foot Ankle Res.* 2014;7(1):1.
56. Kavros SJ, Miller JL, Hanna SW. Treatment of ischemic wounds with noncontact, low-frequency ultrasound: the Mayo Clinic experience, 2004–2006. *Adv Skin Wound Care.* 2007;20(4):221–2.
57. Byl N, McKenzie A, Wong T, West J, Hunt T. Incisional wound healing: a controlled study of low and high dose ultrasound. *J Orthop Sports Phys Ther.* 1993;18(5):619–28.
58. Cameron MH. Chsptr 8 and 12 in physical agents in rehabilitation from research to Practice. 2nd ed. St. Louis Missouri: Saunders; 2003.
59. Ottomann C, Stojadinovic A, Lavin PT, Gannon FH, Heggeness MH, Thiele R, Schaden W, Hartmann B. *Ann Surg.* 2012;255(1):23–9.
60. Mittermayr R, VladoAntonic JH, Kaufmann H, Redl H, Téot L, Stojadinovic A, Schaden W. *Ostomy Wound Manage.* 2014;60(7):26–39.
61. Qureshi AA, Ross KM, Ogawa R, Orgill DP. Shock wave therapy in wound healing. *Plast Reconstr Surg.* 2011;128(6):721e–7e.
62. Werdin F, Tenenhaus M, Rennekampff HO. Chronic wound care. *Lancet.* 2008;372(9653):1860–2.
63. Wang CJ, Kuo YR, Wu RW, Liu RT, Hsu CS, Wang FS, et al. Extracorporeal shockwave treatment for chronic diabetic foot ulcers. *J Surg Res.* 2009;152(1):96–103.
64. Schaden W, Thiele R, Köpl C, Pusch M. Shock wave therapy for acute and chronic soft tissue wounds. *J Surg Res.* 2007;143(1):1–12.
65. Wang C-J, Wu R-W, Yang Y-J. Treatment of diabetic foot ulcers: A comparative study of extracorporeal shockwave therapy and hyperbaric oxygen therapy. *Diabetes Res Clin Pract.* 2011;92(2):187–93.
66. Moffatt CJ, O'Hare L. Venous leg ulceration: treatment by high compression bandaging. *Ostomy Wound Manage* 1995; 41(4):16–8, 20, 22–5.
67. Partsch H. Compression therapy of the legs. A review. *J Dermatol Surg Oncol.* 1991;17(10):799–805.
68. Kota AA, Selvaraj AD, Premkumar P, Agarwal S. Four Layer Dressing in the management of chronic venous ulcers. *Wound Medicine.* 2014;5:21–4.
69. iDATA Research, Inc. U.S. Market for chronic venous insufficiency treatment. 2009.

70. McGuckin M, Waterman R, Brooks J, et al. Validation of leg ulcer guide-lines in the United States and United Kingdom. *Am J Surg.* 2002;183:132–7.
71. McDaniel HB, Marston WA, Farber MA, Mendes RR, Owens LV, Young ML, et al. Recurrence of chronic venous ulcers on the basis of clinical, etiologic, anatomic, and pathophysiologic criteria and air plethysmography. *J Vasc Surg.* 2002;35:723–8.
72. Langer V. Preventing leg ulcer recurrence. *Indian Dermatol Online J.* 2014;5(4):534–5.
73. Partsch H. Understanding the pathophysiological effects of compression. In: *Understanding compression therapy.* EWMA Position document. London: MEP Ltd; 2003. p. 2–4.
74. Marston W, Vowden K. Compression therapy: a guide to safe practice. In: *Understanding compression therapy: EWMA Position document.* London: MEP Ltd; 2003. p. 11–7.
75. Cameron MH. Chapter 8 and 12 in *Physical agents in rehabilitation from research to Practice.* 2nd ed. St. Louis Missouri: Saunders; 2003.
76. Chromey PA. The efficacy of carbon dioxide laser surgery for adjunct ulcer therapy. *Clin Podiatr Med Surg.* 1992;9:709–19.
77. Sugrue ME, Carolan J, Leen EJ, Feeley TM, Moore DJ, Shanik GD. The use of infrared laser therapy in the treatment of venous ulceration. *Ann Vasc Surg.* 1990;4:179–81.
78. Lundeberg T, Malm M. Low-power HeNe laser treatment of venous leg ulcers. *Ann Plast Surg.* 1991;27:537–9.

Growth Factors (Third Generation Wound Healing Agents) and Hormones

9

Abstract

In neuropathic non infected wounds, growth factors give good results. PDGF and EGF are only two growth factors available in the market. They should be used with proper wound care practices with wound bed preparation, offloading and immobilization. Male and female sex hormones also play a role in healing process.

Wound healing is a process of tissue repair and tissue response to injury. The complex biological process involves chemotaxis, cellular reproduction, matrix protein production and deposition, neovascularization and scar modeling.

In wound management, the latest work being done is in manipulating the cellular environment of the wound with proteins, growth factors and gene therapy. Growth factors are hormone like polypeptides that control the growth, differentiation and metabolism of cells and regulate the process of tissue repair. Their effects occur by endocrine, paracrine and autocrine action. All the three stages of wound healing are controlled by growth factors which also send a signal for wound healing to stop. They may be autologous derived (solution of multiple GF isolated from the alpha granules of the platelets) or made by chemical or biochemical means outside of the body that is known as recombinant.

The name of the GF is from their tissue of origin, their biological action or the cell on which they exert their influence. They are produced by platelets, macrophages, epithelial cells, fibroblasts and endothelial cells. Growth factors are chemo attractants for neutrophils, macrophages, fibroblasts and endothelial cells. They bind to specific receptors on the cell surface. A very small quantity also exerts a powerful influence on wound healing.

PDGF, TGF β , EGF, FGF and IGF are involved in wound healing. Platelets are rich in growth factors. Growth factors initially released are subsequently degraded by proteases.

Keratinocytes are stimulated by EGF, IGF-I, TGF α or interleukins. Wound remodeling occurs under the control of collagenase produced in response to EGF, TNF, IL-1 and PDGF. Thus all stages of wound healing process are under direct or indirect control of GF.

One study of skin biopsy obtained from the edge of diabetic foot ulcer showed increased expression of TGF β 3 compared to skin biopsy of non-diabetic ulcer patients [1]. A reduced expression of insulin like GF I in basal keratinocyte layer of diabetic skin has also been noted. Glycation causes significant reduction in the ability of BFGF (Basic Fibroblast GF) to bind to its tyrosine kinase receptor and activate the signal transduction pathway. This GF abnormality may play a role in delayed wound healing in diabetic patients.

Growth factors available in the market cannot be expected to have a positive influence on wound healing unless they are used with a comprehensive wound care program.

S. No.	Growth factor	Product available in market
1.	Platelet derived growth factor	Plermin, Healace, Regranex
2.	Transforming growth factor	
3.	Epidermal growth factor	Regen-D, SLVRGEN
4.	Fibroblast growth factor	
5.	Vascular endothelial GF	
6.	Platelet rich plasma	Can be prepared in laboratory or blood bank
7.	Hepatocyte growth factor	
8.	Transforming growth factor α and β	
9.	Keratinocyte growth factor	

Platelet Derived Growth Factor (PDGF)

The molecular weight of PDGF is 24,000 Da. It is approved for clinical use. Like all other growth factors, it is a protein and is heat sensitive and requires storage at low temperature.

PDGF is mainly produced by platelets and endothelial cells but there is no effect of PDGF on endothelial cells [2].

PDGF has three forms AA, AB and BB. Human platelets contain all three forms of PDGF in a ratio of 12% AA, 65% AB and 23% BB.

Effects on Wound

Wounds treated with PDGF have marked increase in inflammatory cells including neutrophils, monocytes and fibroblasts. Granulation tissue production is increased, but PDGF has no direct effect on keratinocytes. Even though there is no stimulation of endothelial cells with PDGF, there is increase in neovascularization. Collagenase, which is important in remodeling of wound is also produced in

response to PDGF. The effectiveness of rh PDGF BB was first studied in decubitus ulcers [3, 4].

Trials

In a randomized prospective double blind trial of recombinant PDGF BB, the dose decided was 2.2 μg per cm^2 of the wound with a vehicle carboxy methyl cellulose. In this trial 48% patients healed with PDGF treatment as compared to 25% healing in vehicle group alone ($p < 0.01$) [5].

In one prospective randomized double blind clinical trial of 118 patients, becaplermin gel (30 mg/g) was shown to be significantly better than the placebo gel in the treatment of diabetic foot ulcer [6]. In another placebo controlled clinical trial with 379 patients daily applications of becaplermin gel at 30 mg/g had no effect on wound healing, but 100 mg/g had good effect [7, 8].

Examples: Plermin, Healace, Regranex.

Epidermal Growth Factor

Epidermal growth factor is produced by platelets. It has a molecular weight of 6200 Da. EGF is also produced by kidneys, salivary glands and lacrimal glands, so high concentration is found in urine, saliva and tears.

EGF stimulates the production of proteins such as fibronectin. Although EGF does not stimulate collagen production, it increases the number of fibroblasts in the wound [9]. EGF is available in a cream form alone and in combination with silver sulfadiazine. Donor site treated with silver sulfadiazine containing EGF has better results as compared to silver sulfadiazine alone. An indian phase III trial of recombinant human epidermal growth factor by Vijay Viswanathan and Sharad Pendsey concluded that rhEGF healed 69% of ulcer in 10 minutes as compared to 21% in placebo group (wounds:2006;18(7):186–196).

Example: Regen-D, SLVRGEN.

Transforming Growth Factor

The growth factor studied most extensively after PDGF is TGF β . TGF- α is produced by macrophages, keratinocytes, hepatocytes [10]. It is not available in the market for wound management.

Fibroblast Growth Factor

It is a group of heparin bound growth factors. Till today there are no clinical trials, which have proved fibroblast growth factor to be of benefit in clinical wound healing.

Vascular Endothelial Growth Factor (VEGF)

It is quite similar to PDGF. It has a molecular weight of 45,000 Da. VEGF is useful to create new blood vessels during embryonic development, after injury and to form new vessels after blockage of vessels. There is no proof that it benefits wound healing. It is not available as a dressing material in the market.

Keratinocyte GF (KGF), insulin like growth factors are other growth factors which are tried for wound healing, but no therapeutic role is proved in wound healing.

Platelet Rich Plasma [PRP], Platelet Releasate

PRP (Platelet rich plasma) is a type of advanced wound care therapy for chronic as well as acute wounds. PRP is defined as a portion of plasma fraction of autologous blood having platelet concentration above baseline (it is expected to have five times the normal concentration of platelets in PRPs). It has been used for more than 20 years. The PRP contains cytokines, many growth factors, and fibrin scaffold.

PRP needs activation prior to its application. The activation can be done by thrombin and calcium chloride. Collagen is a natural activator so it doesn't require activation when PRP is used in soft tissues. PRP is thought to be a store house of growth factors.

Classification

1. Pure PRP or leukocyte poor PRP.
2. Leukocyte and PRP.
3. Pure platelet rich fibrin (P- PRF).
4. Leukocyte and platelet rich fibrin.

Mechanism of Action of PRP

Platelet rich plasma attracts undifferentiated cells of matrix and with this cell division is enhanced. PRP is known to suppress cytokine release and reduces the process of inflammation. Stimulation of cellular division in turn promotes capillary growth and granulation tissue and epithelialization.

Some studies have shown antimicrobial activity against *E. coli*, *Staphylococcus aureus*, MRSA, and *Candida albicans*.

Method to Prepare PRP

20 ml of venous blood is collected and anticoagulated with acid citrate dextrose and centrifuged. After centrifugation it is activated by 10% calcium chloride.

How to Apply

In non-infected healthy chronic wounds, it is injected in and around the wounds every two weeks until it heals. Platelet releasate might concentrate factors that heal the wound as well as those which help in stopping the process of healing.

There is a possibility of transmission of infectious agent with platelet releasate. This risk is reduced if the releasate is harvested from a single donor or from the patient himself.

Trial

In one trial, 49 patients with chronic wounds were treated with platelet releasate [11]. This trial suggested a benefit from platelet releasate local application. In another trial, patients were treated with silver sulfadiazine, only 3 out of 23 lower extremity wounds healed [12]. When platelet releasate was applied, remaining all healed.

In a retrospective cohort study, 2517 patients with refractory DFU patients were studied [13]. They found superior effectiveness of engineered skin construct. Platelet releasate and rhPDGF were reported to be having better healing rate than standard care. rhPDGF was less costly and more effective than platelet releasate at 20 weeks of therapy [14].

Hormones

It is known that hormones play a definite role in healing of wounds. Elderly patients heal slowly. In females of menopausal period healing process is delayed due to reduction in sex hormone levels. Systemic hormone replacement therapy increases the acute wound healing. Similarly topical oestrogen also accelerates healing [15, 16].

Androgens inhibit healing. So elderly males are more prone to develop non-healing ulcers than elderly females [17].

Effects of hormones on wound healing

Process	Oestrogens	Androgens
Inflammation	Reduced	Increased
Re-epithelialization	Increased	Uncertain
Angiogenesis	Doubtful	Doubtful
Matrix deposition	Increased	Reduced
Wound contraction	Increased	Uncertain
Overall healing	Better	Not good

Comments

Diabetic foot ulcers are major health problems. There is prolonged inflammatory phase with delay in granulation tissue formation. PDGF and EGF are the only growth factors available in market and extensively studied. Growth factors are not to be misused in presence of infection and necrotic tissue. They need to be combined with proper wound bed preparation, off-loading and immobilization. Many a times it is wrongly used in presence of infection and osteomyelitis. They should be reserved for healing wounds to expedite epithelialization. PRP is cheap and safe in treating any chronic wounds especially diabetic foot ulcers.

References

1. Jude EB, Blakytyn R, Bulmer J, et al. Transforming growth factor-beta 1,2,3 and receptor type I and II in diabetic foot ulcers. *Diabet Med.* 2002;19:440–7.
2. Lynch SE, Nixon JC. Role of platelet derived growth factor in wound healing: synergistic effects with growth factors. *Proc Natl Acad Sci U S A.* 1987;84:7696–7.
3. Robson M, Phillips L. Platelet derived growth factor BB for the treatment of chronic pressure ulcers. *Lancet.* 1992;339:23–5.
4. Mustoe T, Culter N. A phase II study to evaluate recombinant platelet derived growth factor BB in the treatment of stage 3 and 4 pressure ulcers. *Arch Surg.* 1994;129:212–9.
5. Steed DL. Diabetic ulcer Study group: clinical evaluation of recombinant human platelet derived growth factor for the treatment of lower extremity diabetic foot ulcers. *J Vasc Surg.* 1995;21:71–81.
6. Steel DL. Clinical evaluation of recombinant human platelet derived growth factor for the treatment of lower extremity diabetic ulcers. Diabetic ulcer Study group. *J Vasc Surg.* 1995;21:71–8.
7. Weiman TJ, Smiel JM, Su Y. Efficacy and safety of a topical gel formulation of recombinant human platelet derived growth factor BB in patients with chronic neuropathic ulcers. A phase 3 randomized placebo controlled double blind study. *Diabetes Care.* 1998;21:822–37.
8. Bhansali A, Venkatesh S, Dutta P, et al. Which is the better option: recombinant human PDGF-BB 0.01% gel or standard wound care, in diabetic neuropathic large planter ulcers off loaded by a customized contact cast? *Diabetes Res Clin Pract.* 2009;83:e 13–6.
9. Veves A, et al. Chapter 20: Role of growth factors in the treatment of diabetic foot. In: *The diabetic foot.* 2nd ed. Totowa, NJ: Humana Press; 2006. p. 453–4.
10. Sporn MB, Robert AB. Transforming growth factor. *JAMA.* 1989;262:938–41.
11. Knighton DR, Ciresi KF. Classifications and treatment of chronic non healing wounds. *Ann Surg.* 1986;104:322–30.
12. Atri SC, Misra J. Use of homologous platelet factors in achieving total healing of recalcitrant skin ulcers. *Surgery.* 1990;108:508–12.
13. Kirsner RS, Michela M, Stasik L, et al. Advanced biological therapies for diabetic foot ulcers. *Arch Dermatol.* 2010;146(8):857–62.
14. Kantor J, Margolis DJ. Treatment options for diabetic neuropathic foot ulcers: a cost effectiveness analysis. *Dermatol Surg.* 2001;27:347–51.
15. Ashcroft GS, Green-Wild T, Horan MA, Wahl SM, Ferguson MW. Topical estrogen accelerates cutaneous wound healing in aged humans associated with an altered inflammatory response. *Am J Pathol.* 1999;155:1137–46.
16. Ashcroft GS, Dodsworth J, van Boxtel E, et al. Estrogen accelerates cutaneous wound healing associated with an increase in TGF- β 1 levels. *Nat Med.* 1997;3:1209–15.
17. Taylor RJ, Taylor AD, Smyth JV. Using an artificial neural network to predict healing times and risk factors for venous leg ulcers. *J Wound Care.* 2002;11:101–5.

Abstract

(a) Stem cell therapy:

Stem cell therapy is a future of many diseases. Adipose tissue stem cells are extensively tried for wound management. Stem cell therapy is useful in degenerative bone disease, cardiac muscular degeneration, retinal degeneration, kidney disorder and some dermatological conditions in addition to wound management. Autologous stem cell therapy is likely to be accepted more easily by medical and ethical committees.

(b) Cellular therapy:

Fibroblasts, keratinocytes, adipose derived stromal vascular fraction cells, bone marrow stem cells and platelets are used as cellular therapy. When there is more skin loss, cellular therapy is a boon. Cells are derived either from a piece of skin by processing and culture or from adipose tissue in the form of stromal vascular fraction cells. The cells when applied on the wound survive on wound and start multiplying. Autologous and allogenic cells can be used for cellular therapy.

(c) Skin and living skin equivalents:

Skin is the best dressing material. Cadaveric, allogenic, autologous and xenografts are available to cover large wounds. Acceptance of skin graft is better than bilayered skin substitutes. Skin substitutes are better to cover open bones and joints. Epidermal and Bilayered synthetic skin substitutes are very costly. Placental membrane is also available in plenty as a dressing material.

(d) Gene therapy:

For wound management, it is gene transfer treatment and not gene therapy. There are physical, chemical and viral ways to introduce gene. Growth factor genes are transferred to wound cells. This in turn produces growth factors and helps the wound to heal faster. This therapy works better than local application of growth

factors. It is a costly therapy and available in only a few centres. RNA, DNA viruses and lentiviruses are used as vectors for gene therapy.

It is relatively a new field. It brings together experts in biology, chemistry, computer science, engineering, genetics, medicine, robotics, and other fields to find solution to some of the most challenging medical problems.

Regenerative Therapy Includes

- (a) Stem cell therapy.
- (b) Cellular therapy.
- (c) Living skin equivalents.
- (d) Gene therapy.

Stem Cell Therapy

Stem cells are primitive cells with ability to develop different types of cells in the body. It can be converted into muscle, bone and ligament also. Stem cells are present in cord blood as well as in bone marrow, adipose tissue, and many other parts of the body. Separating the adult stem cells and modifying it to the required tissue is a new science for many pathological conditions as well as wound healing.

Before understanding the stem cell therapy for wounds let us understand different types of cells and stem cells so that understanding the therapy becomes easy.

Totipotent Cells


These cells can form all types of cells in the body and can also form extra embryonic/placental cells. Embryonic cells within the first couple of cell divisions after fertilization are the only cells which are totipotent. Totipotent cells can develop into any cell type, which makes them ideal for cell and gene therapies as well as tissue engineering for transplants and replacement of diseased cells. This means that the therapeutic value of totipotent stem cells is enormous. After fertilization the zygote is formed, it divides and 2–4–8–16 cell mass is formed which is called blastocyst. Blastocyst has inner cell mass called embryoblast and outer cell mass called trophoblast. The trophoblast forms placenta. The inner mass is the source of embryonic stem cells and they are totipotent.

Pluripotent Cells

These cells have got ability to become different types of cells in body, except those of placenta. [More than 200 types of cells] Cells of blastocyst up to 5–14 days of embryo are pluripotent cells.

Multipotent Cells

These cells can develop into more than one cell types, but more limited than pluripotent cells. Adult stem cells and cord blood stem cells are multipotent cells.



Stem cell therapy. (Courtesy Microscopy of stem cells)

Stem Cells Differ from Other Cells in the Following Ways

- (a) They continue to divide for long period of time.
- (b) They are unspecialized.
- (c) They can give rise to specialized cells.(muscle, nerves, skin).

There is a lot of research going on regarding the therapeutic potential of stem cells derived from adult and embryonic tissues [1].

1. Embryonic stem cells: (ESC)

ESCs are the cells within the protective layer of the blastocyst. They are pluripotent. ESCs are derived from 4 to 5 day old human embryo in the blastocyst phase. Pluripotent nature separates them from adult stem cells which are multipotent.

2. Adult stem cells

Adult stem cells are also known as progenitor cells or somatic stem cells. Adult stem cells are located in small quantities through the body including brain, skin, fat cells, skeletal muscles, blood vessels, bone marrow, liver etc. They don't renew themselves as embryonic stem cells, but if these cells are put in a different environment, they may produce a different type of cell from the originating cells. They remain in non-dividing state for years until activated by disease or tissue injury.

The pluripotent stem cells are thought to offer greater advantage than specific genes delivered to wounds because they are capable of differentiating into a variety of cell types including fibroblasts, endothelial cells, keratinocytes which are critical cellular components required for healing.

Bone Marrow Derived Stem Cells

There are three categories of bone marrow derived cells that participate in repair of connective tissue

1. Angioblast or endothelial precursor cell(EPC).
2. Fibrocyte.
3. Marrow/mesenchymal stem cell.

1. Endothelial precursor cell:

It is derived from a primitive haemopoietic cell in the bone marrow prior to differentiation into leucocyte lineage. EPCs are not true stem cells since they are apparently committed to the endothelial lineage while in circulation.

2. The Fibrocyte is a leucocyte like cell that infiltrates wounds during inflammatory phase, produces collagen and has many characteristics of antigen presenting dendritic cells [2–4].

Adoptive bone marrow transplantation confirms that these cells arrive in the circulation from the bone marrow.

3. Mesenchymal stem cells [MSC]

These are another circulating, marrow derived cells. They are a pluripotent stem cells, They can be isolated from marrow and grown for many generations in vitro and can be induced to differentiate into many types of mesodermal derivatives, including bone, cartilage, skeletal muscle and adipose tissue [5].

It has been shown that MSCs constitute a significant proportion of collagen producing, fibroblastic population in a healing wound [6]. Adipose tissue appears to be a remarkable source of MSCs, since ASCs (adipose tissue stem cells) are easily isolated from a section of whole fat or lipoaspirate.

BMMSCs (Bone marrow mesenchymal stem cells) reside in the bone marrow stroma, but only a small percentage of nucleated cells which compose the bone marrow are actually MSCs, whereas the amount of ASCs is approximately 500 fold greater when isolated from an equivalent amount of adipose tissue.

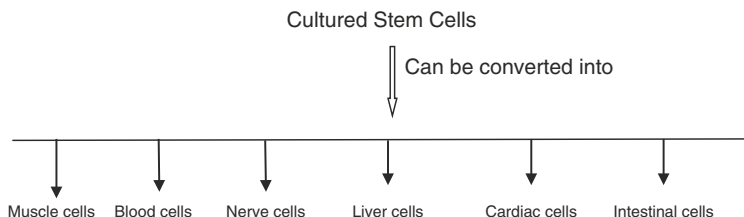
Adipose Derived Stem Cells

They are obtained by lipoaspirate. They differentiate in to mesenchyme [7, 8]. ASCs promote angiogenesis and secrete growth factors [9, 10] There are studies showing that ASCs can differentiate into keratinocytes and produce keratinocyte growth factor. It also shows epidermal regeneration and epidermal integrity [11].

Clinical Application

There is not a great deal of evidence that marrow derived cells take up permanent residence in tissues. They may be largely important during phases of acute repair where local proliferation cannot meet tissue needs [12]. It is recently noticed that many connective tissues do harbor pluripotent stem cell population including dermis, adipose tissue and skeletal muscle. There may be alternative sources of stem cells for therapeutic application.

Bone marrow contains fibroblasts, adipocytes and mononuclear cells. Mononuclear cells include haemopoietic stem cells, mesenchymal stem cells and endothelial progenitors and cellular precursors. Once there is injury, both HSC (haemopoietic stem cells) and mesenchymal stem cells are mobilized from bone marrow to the wound site, where they manage and regulate cell migration and proliferation. Recent study reveals that bone marrow cells play a major role in skin regeneration and revascularization. Several studies have shown positive results with BM MSCs on chronic wound. Even systemic administration of MSCs in critical limb ischemia also has given excellent results.



Comments

Stem cell therapy is a future of many diseases. It is also useful in wound healing. But there is a long way to go. Adipose tissue stem cells are extensively tried for wound management. Stem cell therapy is useful for degenerative bone disease, cardiac muscular degeneration, retinal degeneration, kidney disorder, chronic obstructive pulmonary disease and dermatological conditions. It is also useful in sickle cell disease, thalassemia, aplastic anemia, repair of nerves, heart, muscle and skin, blood cancers, autoimmune diseases, diabetes, and rheumatoid arthritis.

Stem cell therapy with autologous grafting is likely to be accepted more easily by the medical and regulatory committee.

Cellular Therapy

In cellular therapy, human cells are transplanted for repair of damaged tissue or cells. With novel and innovative ideas and with development of newer technologies, many different types of cells are used as part of therapy or treatment for a

variety of diseases and conditions. Fibroblasts, keratinocytes, adipose-derived stromal vascular fraction cells, bone marrow stem cells, and platelets have been used for wound healing in clinical practice. Some formulations are commercially available.

Cellular therapy can be with the use of autologous cells or allogenic cells. Cellular therapy accelerates wound healing by early epithelization and granulation tissue formation [13–15]. Wound contracture is not affected by cellular therapy [16, 17]. Artificial dermis can be used along with cellular therapy which further improves healing [18, 19].

Allogenic cells can also be used with good results [20, 21]. The allogenic cells cannot be permanent, in the healing process, they are replaced by host cells. Allogeneic cells release growth factors, extracellular matrix and basement membrane components and thereby promote migration and proliferation of host cells. Allogenic cells accelerates epithelization and granulation tissue.

For application of cells, collagen and hyaluronic acid matrices are used to form a scaffold. The cells which are ready for therapy are incorporated in scaffolds. The wound is then dressed with cell-scaffold complex and is then covered with foam dressing. Collagen and hyaluronic acid matrices promote migration of host cells and blood vessels into the structure, allowing rapid replacement by host tissue.

Procedure of Harvesting Cells for Cellular Therapy

After skin preparation, 2×2 cm skin with thickness of 0.15–0.20 mm is harvested. This skin is put in an enzyme solution which is derived from pig. This is then processed and heated for 15–30 minutes to separate the cells. The piece of skin is scraped with a scalpel to get cellular material. The separated cells are then added to a buffer solution. A cell suspension is prepared which contains keratinocytes, melanocytes, fibroblasts and langerhans cells. The suspension with the cells is then applied to the ulcer. These cells then proliferate on the wound bed.

Adipose tissue cells are harvested by liposuction from the abdominal wall. The cells are incubated in culture medium containing collagenase. It is processed and lysis of red blood cells is done. The remaining cells are washed and filtered.

Comments

Cellular therapy is a promising science. Large wounds can very well be covered with cellular therapy. This is very useful for burns patients. When autologous skin is not available, even allogeneic skin can give good results as far as wound healing is concerned. Further studies are needed to determine the fate of transplanted cells and the number of cells required to show definitive effects. Further studies are also required on the length of time for cells to be maintained after harvesting and still retain viability.

Skin and Living Skin Equivalents (LSEs)

Skin is the best dressing material. Sometimes donor skin is not available to cover large areas of wound. Sometimes the patient is not willing to use his/her own skin.

There is now a possibility of use of cadaveric skin and allogenic skin with certain limitations. Tissue engineering technology has revolutionized skin coverage. In this technique skin cells are cultured and embedded in a synthetic matrix which in turn is applied on the wound. Epithelium is cultured upon a dermal equivalent which closely resembles a skin graft. Living skin equivalent is approved by USFDA for clinical use.

Skin grafts are of two types (1) cadaveric (2) living.

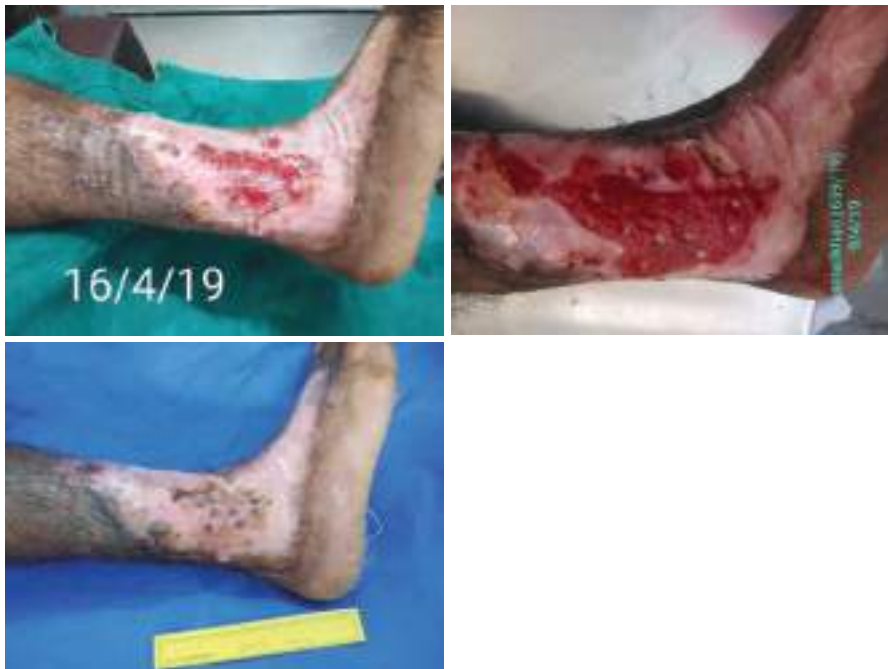
Cadaveric graft is allogenic, it can be fresh skin or cryopreserved. Cadaver skin closes and protects the wound and should be removed at a later date, leaving a well vascularized wound base that makes subsequent skin grafting more readily acceptable.

Unfortunately, the demand for cadaver skin is high and is often not available for immediate use. It can also cause problems with graft rejection and transmission of disease. Cryopreservation affords longer storage and immediate availability, but makes the allograft more susceptible to sloughing off the wound bed. Rejection of this graft starts after first week, the epidermal layer is subjected to rejection, dermis remains adhered to the wound.

Human acellular dermal regenerative tissue matrix is derived from decellularised cadaveric dermis. It is available in the market and it has given good results in some trials [22].

Different Types of Grafts:

1. Autograft—Here skin is taken from the same individual



2. Allograft (homograft)—Skin is taken from genetically non identical donor of same species. A homograft takes exactly like autograft, but it survives for 3–10 weeks before getting rejected by immune system
3. Xenograft (Heterograft)—A graft is taken from a different species. Porcine graft has close resemblance to human skin. Frog and lizard skin were used in 16th and 17th century.

The term tissue engineered skin refers to skin products produced from cells, extracellular matrix/material or a combination. In some cases it includes cells impregnated in non-biological material.

Living skin equivalents are tissue grafts made from keratinocytes and dermal fibroblasts harvested from neonatal foreskin using tissue engineering biotechnology. LSEs are approved for use in humans [23, 24]. When applied on a wound, LSEs serve as a drug- delivery system providing matrix proteins and growth factors including PDGF, TGF- β , VEGF and KGF to the wound [25]. LSEs have no professional antigen presenting cells, such as endothelial cells, leukocytes, or dermal dendritic cells; thus, they do not activate T cells and cause rejection.

Epidermal Replacements

Epithelial cells are procured from full thickness skin biopsy. Through a process epithelial cells are cultured to a broad sheet. The cultured epidermal autograph can very well be accepted because it is from the patient's own skin. This technique is expensive and takes 2–3 weeks to culture sufficient amount of epithelium. A skin biopsy of 1–3 cm² can be expanded 10,000 times by tissue culture in about 14–18 days. This process is useful to cover a huge skin loss. When epithelium is applied to a wound, It is very fragile and the skin is prone to contraction and breakdown. In the process of healing dermis also plays an important role, so efforts were made to develop dermal grafts.

Example: Epicel.

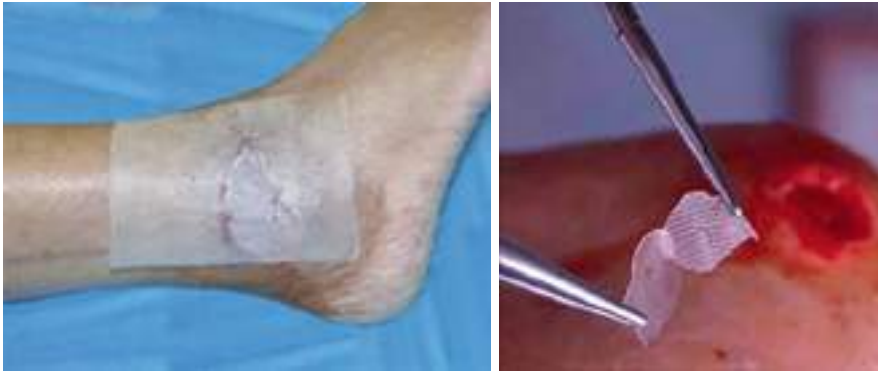Bilayered Skin Substitute (Apligraf)

Apligraf contains dermis as well as epidermis. Dermis is manufactured by adding neonatal fibroblasts in a collagen sheet. The epidermis is formed by neonatal keratinocytes which are cultured and grown on the top of dermis. This process is done in well equipped laboratory. Apligraf makes matrix proteins and growth factors and has the capacity to heal itself [26, 27]. It is the only product with FDA approval to treat both venous leg ulcers (VLUs) and diabetic foot ulcers (DFUs).

One clinical trial showed that treatment with Apligraf once a week for a maximum of 4 weeks reduces the median healing time to 38.5 days from 91 days in a control group. 75% of Apligraf treated group achieved complete healing as compared to 41% for the control group [28].

Example: OrCel.

Dermagraft



Dermagraft

It is a dermal replacement layer manufactured in a laboratory. Neonatal foreskin fibroblasts are cultured on a bio absorbable polyglactin or polyglycolic acid polymer matrix. The fibroblasts in dermagraft produce VEGF and hepatocyte growth factor [29]. It is also FDA approved. Human cells produce dermal collagen, matrix protein, growth factors and cytokines. It does not contain macrophages, lymphocytes, blood vessels, or hair follicles. It is indicated for full thickness DFUs (Diabetic foot ulcers) that have been present for longer than 6 weeks, not involving tendon, muscle, joint capsule or bone.

In a study in USA, 314 patients with diabetic foot ulcers, in which 30% of study patients had healed by 12 weeks as compared to 18.3% of control group [30].

Bilayered Acellular Matrix

Bilayered acellular matrix



It is a total synthetic dressing material. Cross-linked porous matrix of bovine tendon collagen and glucose aminoglycans such as chondroitin 6-sulfate are used to prepare a dermal replacement layer. It acts as a scaffold in which dermal skin cells regenerate and there is a process of angiogenesis, cellular migration and collagen remodeling. The top layer is a temporary epidermal substitute that is made up of silicone and functions to control fluid loss and serves as a bacterial barrier. Once dermal skin has revascularised, the silicone layer is removed and for larger wounds it can be replaced with a split thickness skin graft [31, 32]. This material is called bi-layered in which both the layers are synthetic in origin.

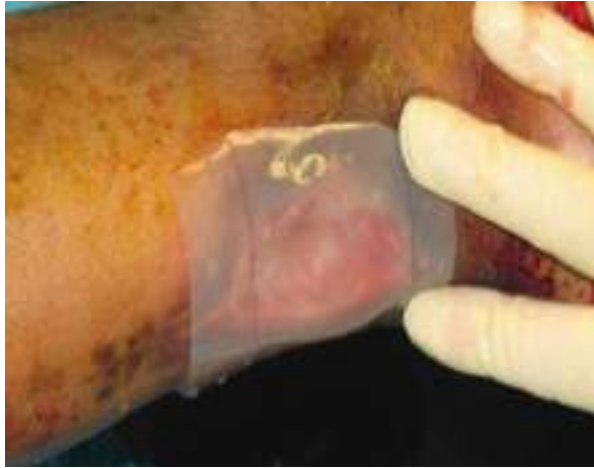The other variety is two layered temporary synthetic skin. The inner layer is tightly woven nylon fabric, the outer layer of ultrathin silicone rubber which is semi permeable. When there is good granulation tissue in the scaffold of nylon fabric, outer silicone sheet is removed and an autograft is put on it.

Normal human dermis is also used with removal of all cellular material with a process.

Uses

It is used after surgical debridement especially when there are soft tissue defects involving exposed bone, tendon, and joint after contracture release of burns, after digital injury for better healing. Take up rate of these dressings is less than autograft.

Integra applied on the wound



Example: Integra, Alloderm, Biobrane, transite.

Small Intestine Submucosa(SIS)

Small intestine submucosa is a natural acellular, extracellular matrix from porcine small intestinal submucosa(SIS) . It is a complex mixture of structural and functional proteins of proteoglycans and glycoproteins. The structure of SIS provides tensile strength and attachment site for cell surface receptors, works as a reservoir for factors which modulate angiogenesis, cell migration, cell proliferation and inflammation immune responsiveness and wound healing.

SIS has low risk of immunological reaction and increased resistance to bacterial contamination. On application of SIS, there is intense cellular infiltration followed by capillary ingrowth.

Before applying SIS, we need to remove exudates and necrotic tissue. Then we should wait for any bleeding to stop. We need to rehydrate the wound with saline and then apply SIS. Non adherent dressing needs to be applied over SIS and it should be changed after 5–7 days.

A gel is formed over the wound and we are not supposed to forcibly remove it. SIS consists of type I, II, IV and V collagen [33]

Example: Dermasis and Oasis wound matrix.

Trial

In a prospective multicenter randomized trial at 12 weeks of treatment 49% of SIS wound matrix treated patients had achieved complete wound closure as compared to 28% of rh PDGF treated patients [34].

Oxidized Regenerated Cellulose

A sterile, frozen, dried, oxidized regenerated cellulose and collagen are available as a composite dressing. It is a protease inhibitor dressing and protects endogenous growth factors. It is also a type of collagen dressing and an acellular dressing.

In one study, ulcer of more than 6 months duration, 45% achieved complete healing compared to 33% of controlled group (standard of care) at twelve weeks [35, 36].

Example: Promogran.

Placental Membrane

Since years we have been using placental membrane as a dressing material frequently in burns patients. It is now commercially available as a dressing material. It is rich in growth uronic acid. There is risk of infection and placental membrane once applied needs to be changed. Placental tissues contain amnion and chorion, out of that amnion is used as the dressing material [37].

Amniotic membrane is received and processed within 72 h from the time of delivery. It is available in the market in different sizes. The epithelial side should be identified and it is to be applied to the patient's affected area. We don't need to rehydrate. The size selected should be bigger than ulcer size [38–40]. All the necessary tests are done to prevent spread of infectious diseases through donor placenta. Amniotic dressing is changed every 7–14 days till the wound has healed.

Role in wound healing:

- It is widely used world over since early 1900s.
- It is known to have over 250 proteins (cytokines, chemokines, growth factors) that can potentially aid in wound healing process.
- It can affect many stages of wound healing process and has also antibacterial properties.
- It enhances wound healing process substantially.

Examples:

Dermacyte, AmchoPlast.

Comments

Skin is the best dressing material. Acceptance of skin graft is better as compared to that of cultured sheet of bilayered synthetic skin substitute. Cadaveric graft can be available in plenty, but its limitations are early rejection. Skin banks have started across the world to help the wound patients. Skin substitutes are very costly and not available in India. Skin substitutes either provide only epidermis, or dermis or both. This is useful for ulcers where bone, joint is exposed. It also produces different growth factors which help in healing. If both dermal and epidermal components are combined (bi layered skin) then the results are better. Placental membrane dressing is available in plenty, it can be available in small center as well and it is economical. The cultured skin substitutes provide matrix proteins and can provide cytokines, but they are not having melanocytes, macrophages, lymphocytes and langerhans cells. Research is being required to have skin substitutes having melanocytes and sweat glands.

Gene Therapy

Wound healing is a complex science where there is a role of growth factors, growth factor receptors, and cytokines. In chronic wounds healing is delayed because of deficiency of endogenous growth factors. Growth factor proteins were tried for healing of such wounds but after pre-clinical trials results were disappointing. At present only rhPDGF-BB and epidermal growth factor are approved for use in non-healing ulcers. Gene therapy was thought of in such chronic wounds to provide long term growth factors by the wound cells themselves. Fibroblasts, endothelial cells, and inflammatory cells are target cells for DNA uptake. It is thought that if these cells are modified by gene therapy, they will provide growth factors throughout the process of healing. Once the process of healing is complete the genetically modified cells no longer remain. So this is a temporary gene transfer therapy.

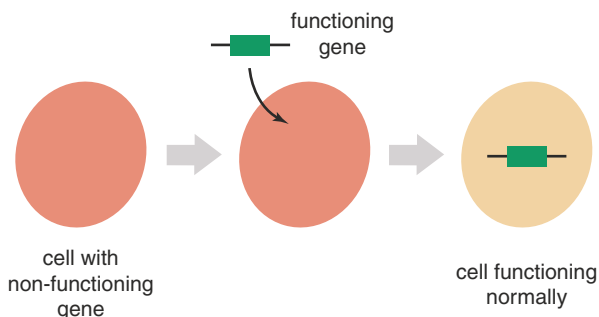
Application of local growth factor is a modality of treatment in wound management. Genetically modified cells can synthesize and deliver growth factor to the wound. Gene therapy is more useful temporarily till wound heals as compared to its limited role in genetic diseases.

Genes can be introduced in the wound by many physical means or with the help of biological vectors like viruses. Cells are manipulated before reintroduction into the wound. This may be by simple injection or with the use of gene gun. It is difficult to have stable and long term effect of a gene in a systemic disease. In non-healing wounds only transient expression is required. The introduction of naked plasmid DNA encoding the gene for VEGF has been reported to enhance healing and angiogenesis in selected patients with ulcers from arterial insufficiency [41]. Gene therapy effectively changes the cell into a productive and active cell that releases growth factor.

By 1990, many investigators proved that peptide growth factor has a clear role in wound healing. Many biotechnology groups had succeeded in expressing the recombinant proteins as potential therapeutic agent. It is known that very high doses of exogenous peptides are required for healing of chronic wounds, the same effect can be achieved by a very small quantity of proteins expressed by the resident cells. Thus several groups developed methods to improve the deficiency of peptide growth factors by introducing C-DNA copies of growth factor.

Genes in wound site cells

Gene augmentation therapy



The reason why gene therapy can be effective:

1. Growth factor molecule would be released by wound cells rather than being applied to the exterior of an infected wound environment with exudation, slough and necrosis.
2. Active principle, regardless of the end product, was DNA.
3. Several techniques are available to ensure local delivery and the action of the genes in question.
4. The action of the introduced gene would be transient, thus denoting the technique as gene transfer, as opposed to the correction of an underlying genetic defect by gene therapy.

There are several potential methods to transfer genes into skin or wounds [42, 43].

Gene transfers have achieved a successful outcome in many preclinical models using C DNAs for epidermal growth factor, TGF β , PDGF, FGF2, VEGF, hepatocyte growth factor and other peptides in the delivery system [44].

(a) **Physical Method:**

DNA vector is driven into the tissues with mechanical and electrical force. E.g., Gene gun device propels small DNA coated gold or tungsten particles into the tissue in a shotgun pattern [45].

- (b) Chemical method of DNA delivery is less efficient and less expensive. It includes liposome nanoparticles, dried methyl cellulose disc, collagen gel, calcium phosphate, lipids, chitosan.

(c) **Viruses:**

Viruses used are carriers and they are replication defective so that they cannot proliferate and cause disease.

There are different types of viruses:

- (a) RNA virus: RNA virus is one in which the genetic information is stored in the form of RNA (as opposed to DNA).
- (b) Retro virus: This is a group of RNA viruses which insert a DNA copy of their genome into the host cell in order to replicate. It changes the genome of host cell.
- (c) Lentivirus: Lentiviruses are a subtype of retroviruses. Retroviruses can only infect mitotically active cells where as lentiviruses can infect both non-dividing and actively dividing cells. Lente viruses can cause chronic and deadly diseases (HIV) characterized by long incubation period.
- (d) Adeno virus: It is a group of DNA viruses first time discovered in adenoid tissue.

These viruses infect the dividing cells and integrate their nucleic acid into the host genome [46]. Viruses are natural gene delivery system [47]. RNA viruses

(retroviruses) such as Moloney sarcoma virus and the lentiviruses are more useful as gene therapy. Retroviruses have the limitation of being able to carry DNA of only 4–5 kb size which is smaller than the size of several genes. They have stable insertion of their genome into the host genome. DNA viruses are transient gene delivery system, adenovirus do not insert viral DNA into the host genome. Adeno associated virus produces less inflammatory response, although it has limitations in the amount of genetic material it can carry and the cell type that can be infected [48, 49].

Problem of viral vectors is the possibility of insertional mutagenesis. Risk of inflammatory reaction to a viral vector is also possible [50].

Limitations of Gene Therapy

Capacity of trans gene delivery of viruses is uncertain and non-viral vectors are having limitation by the size of trans gene that can be delivered [51].

Trials

Clinical trials are done for PDGF BB delivered by an adenovirus in diabetic foot ulcer patients [52]. There are also clinical trials with good results in peripheral vascular disease with FGF-2 and VEGF in gene transfer experiments.

It proteases, growth factors proteases.

1. In a trial in Japan, hepatocyte growth factor gene [HGF] was delivered intra dermally in skin wounds which showed good wound healing and complete suppression of apoptosis [53].
2. Delivery of VEGF gene via adeno associated virus in mice resulted in stimulation of angiogenesis, re-epithelialisation, synthesis and maturation of extracellular matrix [54].

Comments

It is the gene transfer treatment and not gene therapy. Growth factors applied on the wound have limitations in action and stability. Comparatively large doses are required for local application. Gene transfer works by transferring growth factor genes to the wound cells. This in turn produces growth factors locally and helps the wound to heal faster. Though this looks excellent, it is costly and requires specialized technology and can be made available in only selective centers. We still need more trials.

It is the need of the time to develop gene therapy to inhibit proteases, as growth factors are not effective in presence of high levels of proteases. Gene therapy is tried in cancer, hemophilia and cystic fibrosis also.

References

1. Weissman IL. Translating stem and progenitor cell biology to the clinic: barrier and opportunities. *Science*. 2000;287:1442–6.
2. Quan TE, Cowper S, Wu SP, Bocknstedt LK, Bucala R. Circulating fibrocytes: collagen-secreting cells of the peripheral blood. *Int J Biochem Cell Biol*. 2004;36:598–606.

3. Abe R, Donnelly SC, Peng T, Bucala R, Metz CN. Peripheral blood fibrocytes: differentiation pathway and migration to wound sites. *J Immunol.* 2001;166:7556–62.
4. Bucala R, Spigel LA, Chesney J, Hogan M, Cerami A. Circulating fibrocytes define a new leukocyte subpopulation that mediates tissue repair. *Mol Med.* 1994;1:71–81.
5. Pittenger MF, et al. Multilineage potential of adult human mesenchymal stem cells. *Science.* 1999;284:143–7.
6. Opalenik SR, Davidson JM. Fibroblast differentiation of bone marrow derived cells during wound repair. *FASEB J.* 2005;19:1561–3.
7. Strem BM, Hicok KC, Zhu M, et al. Multipotential differentiation of adipose tissue-derived stem cells. *Keio J Med.* 2005;54:132–41.
8. Zuk PA, Zhu M, Mizuno H, et al. Multilineage cells from human adipose tissue: implications for cell based therapies. *Tissue Eng.* 2001;7:211–22.
9. Cao Y, Sun Z, Liao L, et al. Human adipose tissue derived stem cells differentiate into endothelial cells in vitro and improve postnatal neovascularization in vivo. *Biochem Biophys Res Commun.* 2005;332:370–9.
10. Rehman J, Traktuev D, Li J, et al. Secretion of angiogenic and antiapoptotic factors by human adipose stromal cells. *Circulation.* 2004;109:1292–8.
11. Nelson TJ, Behfar A, Yamada S, et al. Stem cell platforms for regenerative medicine. *Clin Transl Sci.* 2009;2:222–7.
12. Borue X, et al. Bone marrow derived cells contribute to epithelial engraftment during wound healing. *Am J Pathol.* 2004;165:1767–72.
13. Seo YK, Song KY, Kim YJ, Park JK. Wound healing effect of acellular artificial dermis containing extracellular matrix secreted by human skin fibroblasts. *Artif Organs.* 2007;31:509–20.
14. Erdag G, Sheridan RL. Fibroblasts improve performance of cultured composite skin substitutes on athymic mice. *Burns.* 2004;30:322–8.
15. Morimoto N, Saso Y, Tomihata K, Taira T, Takahashi Y, Ohta M, Suzuki S. Viability and function of autologous and allogeneic fibroblasts seeded in dermal substitutes after implantation. *J Surg Res.* 2005;125:56–67.
16. Yates CC, Whaley D, Wells A. Transplanted fibroblasts prevents dysfunctional repair in a murine CXCR3-deficient scarring model. *Cell Transplant.* 2012;21:919–31.
17. El-Ghalbzouri A, Gibbs S, Lamme E, Van Blitterswijk CA, Ponc M. Effect of fibroblasts on epidermal regeneration. *Br J Dermatol.* 2002;147:230–43.
18. Kang BS, Na YC, Jin YW. Comparison of the wound healing effect of cellulose and gelatin: an in vivo study. *Arch Plast Surg.* 2012;39:317–21.
19. Kim H, Son D, Choi TH, Jung S, Kwon S, Kim J, Han K. Evaluation of an amniotic membrane-collagen dermal substitute in the management of full-thickness skin defects in a pig. *Arch Plast Surg.* 2013;40:11–8.
20. Gallego L, Junquera L, Villarreal P, Peña I, Meana A. Use of cultured human epithelium for coverage: a defect of radial forearm free flap donor site. *Med Oral Patol Oral Cir Bucal.* 2010;15:e58–60.
21. Yanaga H, Udoh Y, Yamauchi T, Yamamoto M, Kiyokawa K, Inoue Y, Tai Y. Cryopreserved cultured epidermal allografts achieved early closure of wounds and reduced scar formation in deep partial-thickness burn wounds (DDB) and split-thickness skin donor sites of pediatric patients. *Burns.* 2001;27:689–98.
22. Winters CL, Bridigo SA, Liden BA, et al. A multicenter study involving the use of a human acellular dermal regenerative tissue matrix for the treatment of diabetic lower extremity wounds. *Adv Skin Wound Care.* 2008;21:375–81.
23. Greenleaf G, Copper ML, Hansbrough JF. Microbial Contamination in allografted wound beds in patients with burns. *J Burn Care Rehabil.* 1991;12:442.
24. Kealey GP. Disease transmission by means of allograft. *J Burn Care Rehabil.* 1997;18:10–1.
25. Yannas I. Studies on the biological activity of the dermal regeneration template. *Wound Repair Regen.* 1998;6:518–24.
26. Falanga V. How to use Apligraf to treat Venous ulcers. *Skin Aging.* 1999;7:30–6.

27. Sabolinski ML, Alvarez OM, Mulder G, Parentau NL. Cultured skin as a smart material for healing wounds: experience in venous ulcers. *Biomaterials*. 1996;17:311–20.
28. Veves A, Falanga V, Armstrong DG, et al. Graftskin a human skin equivalent, is effective in the management of noninfected neuropathic diabetic foot ulcers: a prospective randomized multicenter clinical trial. *Diabetes Care*. 2001;24(2):290–5.
29. Williams A, Marston MD. The efficacy and safety of Dermagraft in improving the healing of chronic diabetic foot ulcer. *Diabetes Care*. 2003;26:1701–5.
30. Gentzkow GD, Iwasaki SD, Hershon KS, Mengel M, Prendergast JJ, Ricotta JJ, Steed DP, Lipkin S. *Diabetes Care*. 1996;19(4):350–4.
31. Ozgonul C, Diniz Grisolia AB, Demirci H. *Ophthal Plast Reconstr Surg*. 2018;34(1):64–7.
32. Iorio ML, Goldstein J, Adams M, Devid H, et al. Functional limb salvage in the diabetic patient. *J Plast Reconstr Surg*. 2011;127(1):260–7.
33. Demling RH, Niezgoda JA, Haraway GD, et al. Small intestinal submucosa wound matrix and full thickness venous ulcers: preliminary results. *Wounds*. 2004;16:18–22.
34. Niezgoda JA, Van Gils CC, Frykberg RG, et al. Randomized clinical trial comparing OASIS Wound Matrix to TRegrenex Gel for diabetic ulcers. *Adv Skin Wound Care*. 2005;18(5 Pt 1):258–66.
35. Niezgoda JA, Van Gils CC, Frykberg RG, et al. Randomized clinical trial comparing OASIS Wound Matrix to Regranex Gel for diabetic ulcers. *Adv Skin Wound Care*. 2005;18(5 Pt 1):258–66.
36. Veves A, Sheehan P, Pham HT. A randomized, Controlled trial of Promogran (a collagen/oxidized regenerated cellulose dressing) vs standard treatment in the management of diabetic foot ulcers. *Arch Surg*. 2002;137:822–7.
37. Kakagia DD, Kazakos KJ, Xarchas KC, et al. Synergistic action of protease modulating matrix and autologous growth factor in healing of diabetic foot ulcers. A prospective randomized trial. *J Diabet Complications*. 2007;21:387–91.
38. Sharma SC, Bagree MM, Bhat AL, et al. Amniotic membrane is an effective burn dressing material. *Jpn J Surg*. 1985;15:140–3.
39. Werber B, et al. A prospective study of 20 foot and ankle wounds treated with cryopreserved amniotic membrane and fluid allograft. *J Foot Ankle Surg*. 2013;52(5):615–21.
40. Zelen, et al. A prospective, randomized comparative study of weekly versus biweekly application of dehydrated human amnion/chorion membrane allograft in the management of diabetic foot ulcer. *Int Wound J*. 2014;1(2):122–8.
41. Chua LSM, et al. An Open label prospective pilot study to evaluate the efficacy of cryopreserved amniotic tissue grafts for chronic non healing ulcers. *Wounds*. 2014;26(5):E30–8.
42. Isner JM, Baumgartner I, Rauh G, et al. Treatment of thromboangitis obliterans (Buerger's disease) by intramuscular gene transfer of vascular endothelial growth factor: Preliminary clinical results. *J Vasc Surg*. 1998;28:964–73.
43. Petrie NC, Yao F, Eriksson E. Gene therapy in wound healing. *Surg Clin North Am*. 2003;83:597–616. vii
44. Eming SA, Krieg T, Davidson JM. Gene transfer in tissue repair: status, challenges and future direction. *Expert Opin Biol Ther*. 2004;4:1373–86.
45. Davidson JM, Krieg T, Eming SA. Particle-mediated gene therapy of wounds. *Wound Repair Regen*. 2000;8:452–9.
46. Crystal R, McElvaney N, Rosenfeld M, et al. Administration of an adenovirus containing the human CFTR cDNA to the respiratory tract of individuals with cystic fibrosis. *Nat Genet*. 1994;8:42–51.
47. Crombleholme TM. Adenoviral- mediated gene transfer in wound healing. *Wound Repair Regen*. 2000;8:460–72.
48. Lu Y. Recombinant adeno associated virus as delivery vector for gene therapy- a review. *Stem Cells Dev*. 2004;13:133–45.
49. Flotte TR. Gene therapy progress and prospects : Recombinant Adeno associated virus(rAAV) vectors. *Gene Ther*. 2004;11:805–10.

50. Cai D, Mukhopadhyay T, Liu Y, Fujiawra T, Roth J. Stable expression of the wild type P gene in human lung cancer cells after retrovirus-mediated gene transfer. *Hum Gene Ther.* 1993;4:617–24.
51. Lindblad JW. Gene therapy in wound healing 2000: a promising future. *Wound Repair Regen.* 2000;8:411–2.
52. Margolis DJ, et al. Clinical protocol. Phase I trial to evaluate the safety of H5. 020CMV. PDGF- b and limb compression bandage for the treatment of venous leg ulcer: trial A. *Hum Gene Ther.* 2004;15:1003–19.
53. Ono I, Yamashita T, Hida T, Jin HY, Ito Y, Hamodo H, Akasaka Y, Ishii T, Jimbow K. Local administration of hepatocyte growth factor gene enhances the regeneration of dermis in acute incisional wounds. *J Surg Res.* 2004;120(1):47–55.
54. Galeano M, Deodato B, Attavilla D, Cucinotta D, Arsic N, Marini H, Torre V, Giacca M, Squadrito F. Adeno-associated viral vector mediated human vascular endothelial growth factor gene transfer stimulate angiogenesis and wound healing in the genetically diabetic mouse. *Diabetologia.* 2003;46(4):555–66.

Offloading, Footwear and Immobilization

11

Abstract

Diabetic foot ulcers have taught us the role of offloading. All neuropathic foot wounds require offloading to heal. The use of airbed or water bed for pressure sores is again an example of off loading. Foot pressure measurement and preparing proper foot wears is a new science. The whole footwear including insole and outsole requires modifications in many patients. But it should be kept in mind that for foot ulcers to heal best treatment is total contact cast and not the foot wears. To prevent toe deformities after forefoot surgery, specialized footwear with fillers in the insole is essential.

Similarly any wound crossing a joint requires immobilization. Soft tissue also requires plaster to heal like bone. Any wound primarily closed crossing a joint heals better if only rest to the joint is given even with some mobility. But same wound if open requires plaster immobilization to heal. There are many devices for offloading and immobilization.

Offloading

Wounds on the foot and crossing any joints are difficult to heal, more so in diabetic patient. In a normal individual without diabetes, pain sensation protects the foot. Non diabetic patient himself would not walk and take rest. This is not so with diabetic patients. Foot insensitivity allows excessive and prolonged stresses which occur in the foot which ultimately results in tissue breakdown [1, 2].

Diabetic patients develop neuropathy gradually over a period of five to ten years, so they lose their sensation and cannot protect their feet. This is the reason why patients of diabetes, leprosy, and patients of other forms of neuropathy with foot lesion need offloading and immobilization.

Mechanism of diabetic foot ulcer formation

Intrinsic factors	Extrinsic factors
Bony prominences	Improper footwear
Deformity of the joints	Walking bare foot
Callus	Accidental injuries
Change in tissue property	Sharp objects in shoe
Operated foot	Level of activity
Neuro-osteoarthropathy	
Limited joint mobility	

Repeated shear stress is known to cause calluses, which results in DFUs [diabetic foot ulcers]. Callus formation precedes ulcer formation in 82% of patients with DFUs. Calluses can increase the plantar pressure by as much as 30%. Motor impairment, shortening of the Achilles tendon (due to glycosylation) and possible rupture of the plantar fascia have the potential to produce equinovarus deformity and subsequently increase the pressure under the forefoot area [3].

When we are planning for off loading, we need to keep in mind magnitude, duration, rate and direction of stress. Selection of offloading method also depends on strength, activity level, postural stability and co-morbidities. Every unprotected step is tearing the wound apart. Postural instability patients cannot use shoes or sandals. Most effective offloading treatment is the one which does not allow comfortable walk till the wound heals. But we often provide ineffective but convenient form of offloading therapy. Patient also selects comfortable footwear rather than effective and scientific footwear.

Methods to Measure Pressure Areas

Off loading of unperceived areas of plantar stress is very important for prevention and treatment of diabetic foot disease [4]. Any process in which pressure on the appendage is reduced is considered offloading. This can be achieved through a variety of measures like shoes or socks for neuropathic foot patients. The use of wheelchair, walker or other devices also minimizes the amount of weight that is put on the foot. For bedridden patients, air bed and waterbed also serve the purpose of offloading. The amount of pressure generated can inhibit blood flow, cause local tissue ischemia and prevent the development of new blood vessels as well as tissues. As such, non-offloading can slow down the process of healing.

There are many methods of foot pressure measurement. Plaster cast, wax, sand, foam box etc. can be used to take impression of the foot and accordingly advise foot wears.

Devices used to take plantar pressure measurement and to identify high pressure areas:

1. Kinetograph:

In this method ridged deformable rubber pad is used to take foot impression.

2. Barograph:
A rubber mat is used with one side smooth, ground side pyramidal projections. It is then kept on a glass and video camera recording is done from beneath [5].
3. Harris–Beath Mat: A mat with ink is used for impression [6].
4. Podotrack: Here carbon paper is used instead of ink for impression [7].
5. Optical pedobarograph: It measures dynamic plantar pressure. There is an elevated walkway with a glass plate which is illuminated along the edge [8]. This is a barefoot pressure measurement device. A monochromatic camera detects the image and pressure is measured.
6. EMED system: EMED system is computer assisted image generating device. It can measure dynamic foot pressures. This can have both in shoe and out shoe pressure measurement. Pressure messages are converted into electric messages [9].
7. F. Scan (computerized):
This computerized method has pressure, force, gait analysis program [10, 11].
8. CAD—CAM. (Computer assisted design and computer assisted manufacturing)
Due to so many technical problems, decision of offloading shoes requires precise planning. It is the time computer should decide static and dynamic component of pressure and computer should help in manufacturing footwear.

Pressure plate analysis



Methods to Offload

Common methods to offload the foot include bed rest, wheel chair, crutch-assisted gait, total contact cast [TCC], felted foam, half shoes, therapeutic shoes, and removable cast walkers, specialized orthosis and silicone rings or cushions [12]. TCC gives better results than offloading foot wears for healing of ulcers [13]. Even simple hosiery stocking can reduce plantar pressure by 30%.

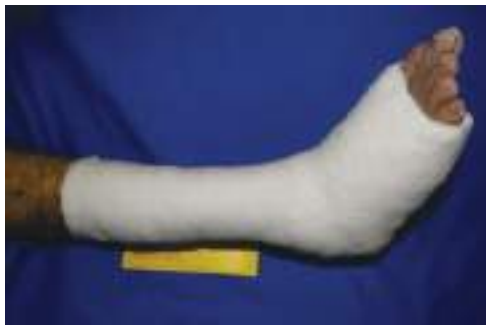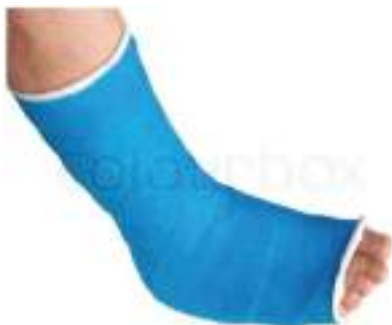The primary reason that TCC appears to be so effective at healing plantar wounds is that it reduces plantar pressure at the site of ulceration by 84–92%. The mechanism of action of TCC is not only to increase the plantar surface area of the foot but

it also transfers weight bearing load to the cast wall and so reduces pressure on plantar skin.

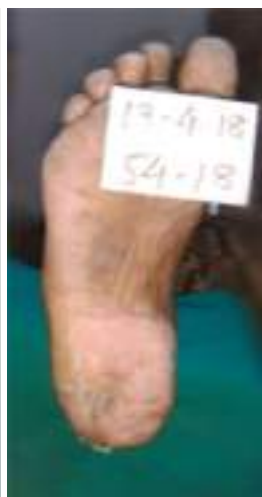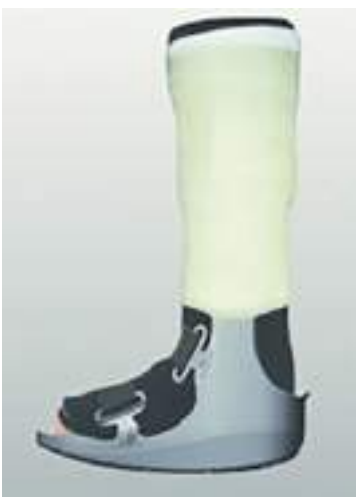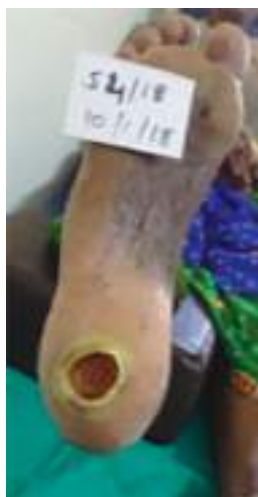For ulcers to heal, TCC (total contact cast) healing rate is more than 90% compared to other modalities (30–65%). The duration of treatment required for ulcer healing with other methods is almost double than that in TCC. So for offloading ulcers, TCC is a preferred modality.

Advantages of TCC

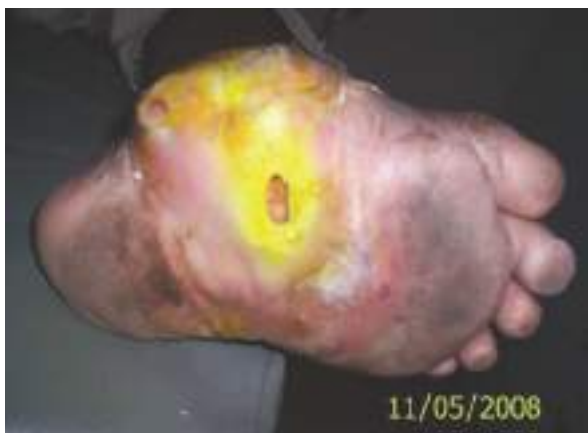1. Maintains ambulation
 2. Reduces excessive plantar pressures
 3. Immobilization helps to localize and prevent spread of infection
 4. Protects foot from further trauma
 5. Controls edema
 6. Requires less patient compliance
-



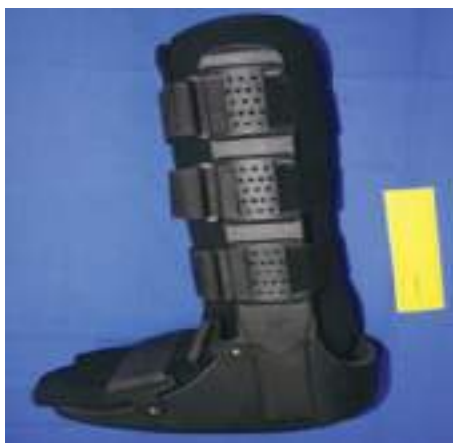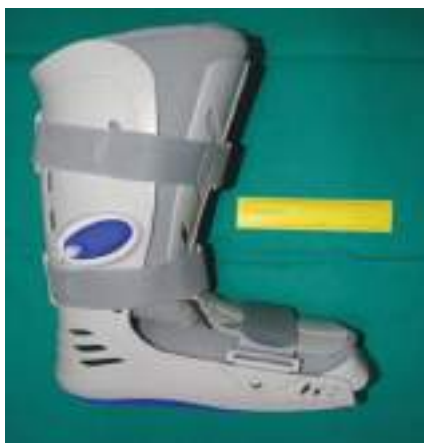Total contact cast



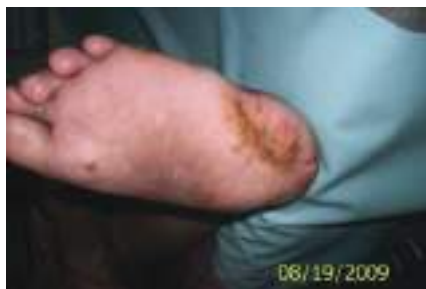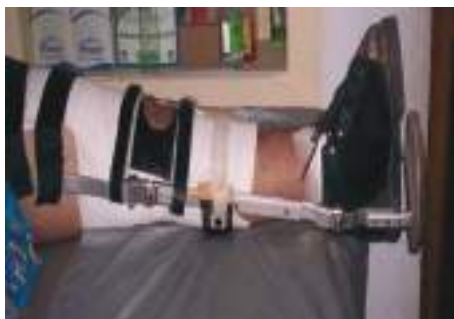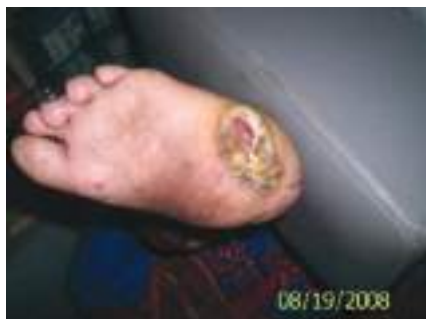Difficult to offload
wounds of Charcot foot



2 years old ulcer healed in 3 months with TCC



Air cast where there is protection of plantar areas with immobilization of MTP joints as well as ankle



Patellar tendon weight bearing caliper healed 12 years old ulcer

Footwear

Hand and foot surgeon Dr. Paul Brand once said “more diabetic patients had congratulated me on the shoes I had prescribed for them than on the foot surgery I performed.”

Our problem in prescribing offloading footwear is lack of uniform data.

How offloading footwear works?

1. It provides room for accommodating deformities.
2. It provides adequate depth for accommodating insoles, pads and socks,
3. It reduces load at critical areas.
4. It can transfer loads. Medial longitudinal arch is a large area to transfer load.
5. It can help changing the patient's gait.

It is to be made very clear that offloading foot wears are better advised for healed ulcer patients, deformed feet patients, but it is not very effective in ulcer healing.

Role of Insoles

Many types of insole materials are available like polyethylene, polyurethane, micro-cellular rubber, microcellular poron etc. All these materials don't hold their shape

for long time. Sometimes it is advisable to use combinations of different materials in insoles. Poron is open cell material and absorbs water. Its compressibility and regaining original form is excellent. Plastazoate is closed cell material, it is water resistant. This property is taken care of in preparing indoor and post operative shoes.

Material of insoles
Microcellular rubber
Poron
Plastazoate
Evazoate
Silicone
Combination of many

People believe that a very soft insole is better. But this is wrong.

If any insole can be compressed by more than 50% between thumb and finger, then probably it is too soft for effective cushioning.

5 mm of difference in positioning of insole can markedly affect the load relief.

Insole should be examined at every visit and should be changed if there are deep impressions under bony prominences. It is advisable to dispense more insoles with a foot wear. There is weather effect and pressure effect on insoles.

For relief of pressure, we can excavate a hole in the insole and also mid-sole. This is only temporarily useful as margin bottoms out and there is sometimes more pressure on surrounding area. There is also herniation of soft tissue in the hole. After some days we find bulky soft tissue in the hole which again starts getting compressed.

A moulded insole is anyway better as it can redistribute uniform pressure all over the plantar aspect of the foot. It is now the time to get dynamic foot orthosis which can help in offloading in static and walking positions.

In addition to insoles, we have load relief pads, like metatarsal cushions/pads, heel pads which help in offloading. Pads are available in 6–10 mm thickness. The thicker the pad accommodated in the shoe, the better the shoe is.

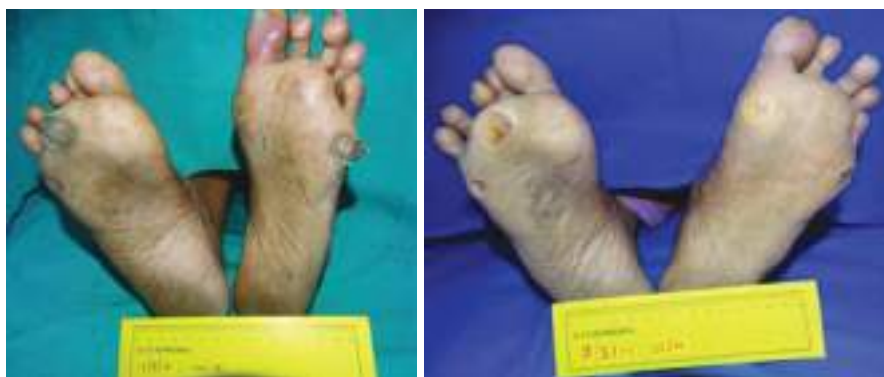Similarly use of medial arch support transfers much of the weight on medial longitudinal arch of foot.

Homemade insole
modification and pressure
points

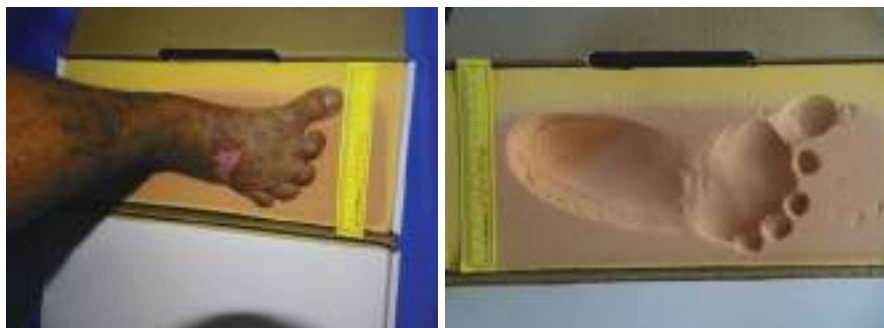



Insole modifications



Multiple callosities to be shaved off regularly and then require offloading to prevent recurrences and ulcerations

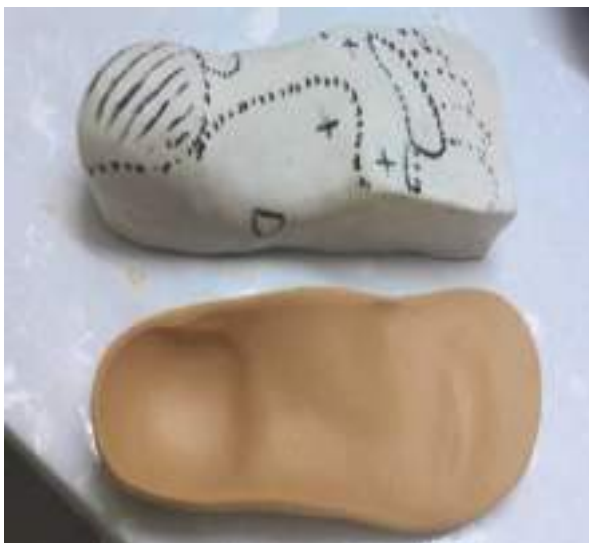

Foam to take foot impression

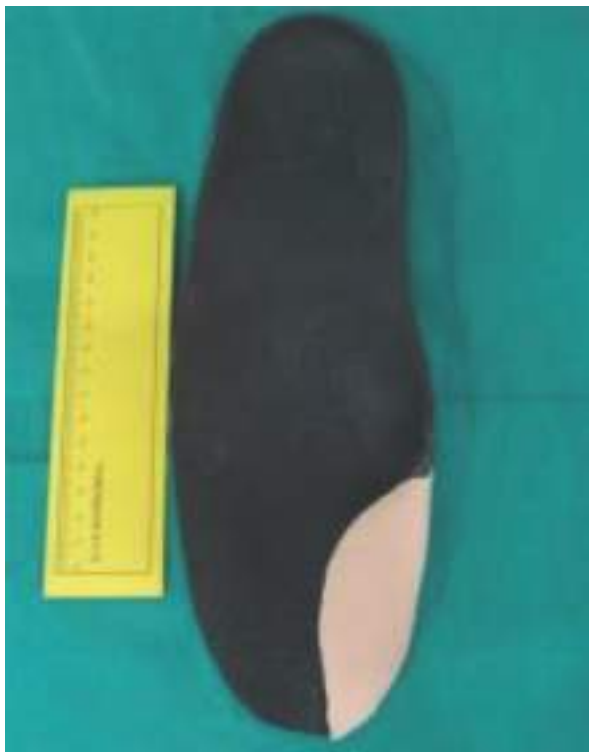Insole with tiles like pegs which can be removed for offloading



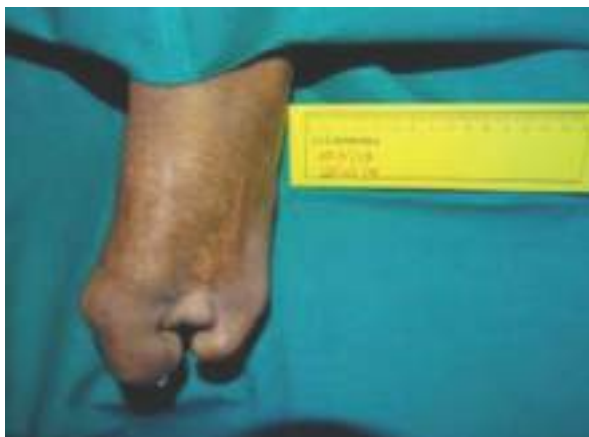Plaster of Paris mould to prepare insole



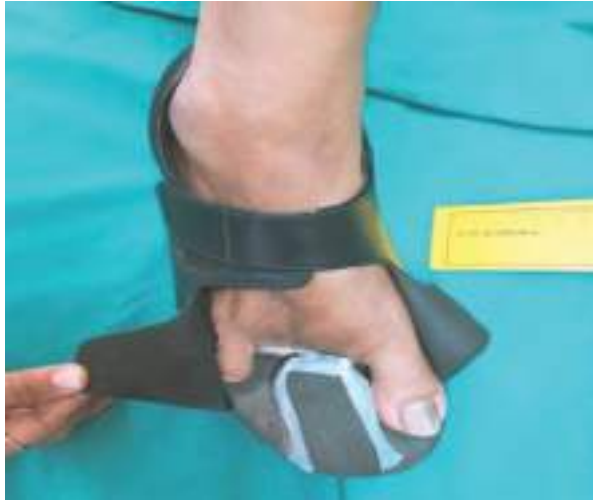Great toe filler in the insole



Deformities of the toes because of not wearing specialized foot wears with filler in the insole



Filler in the insole to prevent crowding of toes and foot deformity after 2nd, 3rd and 4th toe amputation



Medial arch support to distribute plantar pressure to non weight bearing part of foot to give rest to other weight bearing part

Out Sole Modifications

Changes in outsole can also alter pressure bearing areas of foot. Forefoot offloading (forefoot wedge) and heel offloading (heel wedge) out soles are commonly used. For stable charcot foot, midfoot offloading foot wears are also given and rocker bottom outsole also offloads midfoot. For unstable charcot foot, foot wears cannot work and we need to give ankle fixation orthosis like CROW (Charcot restraint orthotic walker).

If heel height is more than 2 in. there is major shift of weight to 1st and 2nd metatarsal heads. Patients of forefoot wounds should avoid high heel footwears.

Rigid plate in the outsole (usually carbon fibre) prevents excessive pressure at metatarsal heads. Rigid outsole prevents extension of MTP joints and so there is no

trauma under MTP joint area. To prevent recurrent callosities and ulcers at MTP head area, rigid outsole gives good protection.

Forefoot orthowedge to
offload forefoot area



Heel offloading footwear



Rocker bottom sandal

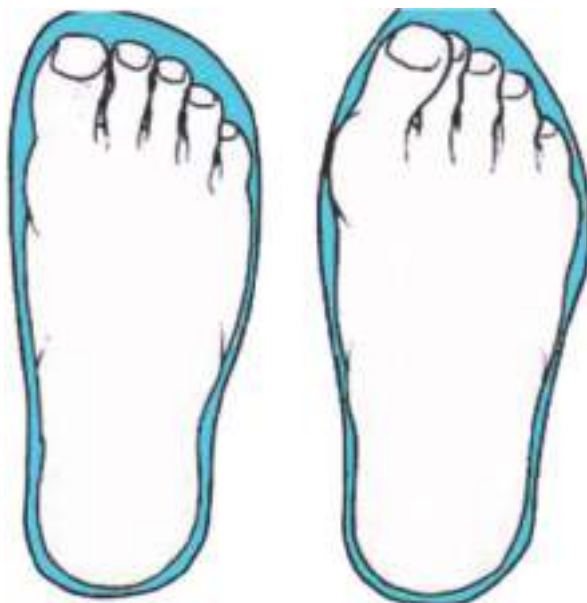

The same principle is applied to rocker and roller out soles, where foot moves as a unit without extension of forefoot joints. These outsoles are sometimes problematic, because aged patients feel insecurity and sometimes may fall down if they are not properly trained for walking. Sometimes the outsole becomes flattened and the function is lost. There is a need for immobilization to heal even plantar ulcers. If joints and tendons are moving, ulcers would never heal.

Patients with following problems should wear specialized foot wears.

Deformed foot
Healed foot
Neuropathic foot
Unstable foot
Callosities and cones
Immediate post operative
One short and one long leg
Abnormal gait

Narrow toe box deforms forefoot. Wide toe box is advisable



How to select a footwear?

1. Newly diagnosed diabetic patient.

All newly diagnosed diabetic patients should be advised not to wear hawai slippers or chappals. Ask them to shake out their shoes, dry out web spaces & wear good quality shoes.

2. **Patient at risk of ulcer.**

For such patients sports shoes are ideal. If the toes are deformed, extra depth or super extra depth foot wears with customized insoles give better offloading.

3. **Ulcer patients.**

As such foot wears are poor devices for offloading, ulcer patients are to be discouraged to wear shoes. They should first use TCC like offloading devices and once ulcer heals, start using preventive foot wears.

Half shoes (forefoot or heel) are good alternatives.

For ulcer patients, when they are on other offloading devices, we should start planning for offloading foot wears.

4. **Healed ulcer.**

We should give time for fragile soft tissues to consolidate, lack of rest results in recurrences. Usually there is 28% recurrence of ulcers at 12 months time [14] and 100% recurrence at 40 months [15] time. This is purely because of negligence, not wearing offloading foot wears, inability to understand the cause of recurrence by patients.

Moulded insoles, outsole modifications etc. should always be done after ulcer healing.

5. **One short foot and one normal foot.**

If transmetatarsal or chopart amputation is done, patients usually prefer to wear cosmetically good looking equal size foot wears, but same length of a footwear in a small foot gives tremendous pressure on stump. It is advisable to prepare a small footwear for the small foot. If cosmetically patient does not accept different sizes of foot wears, it is advisable to give rocker sole on small foot.

6. **Footwear for a Charcot foot patient.**

It is a difficult problem. If forefoot and mid-foot Charcot changes are there a good quality moulded insole with Poron/MCR insole can serve the problem. We can even give rocker bottom footwear.

For ankle Charcot, we need to give PTB (Patellar Tendon Bearing Brace) or CROW (Charcot Restraint Orthotic Walker). This is required till instability remains.

Sometimes we do insole/ out sole modifications together. For forefoot orthowedge foot wear, we keep posterior 2/3 of the insole hard (EVA) and anterior 1/3 soft (Poron/MCR). This gives additional cushioning & offloading. We also give 5–7 mm of level difference in insoles, which helps in offloading. Similarly for heel problems, soft heel pad with heel wedge footwears give better results.

7. **“Fit” of shoe.**

Ideally fitting shoes are absolutely a must for better offloading.

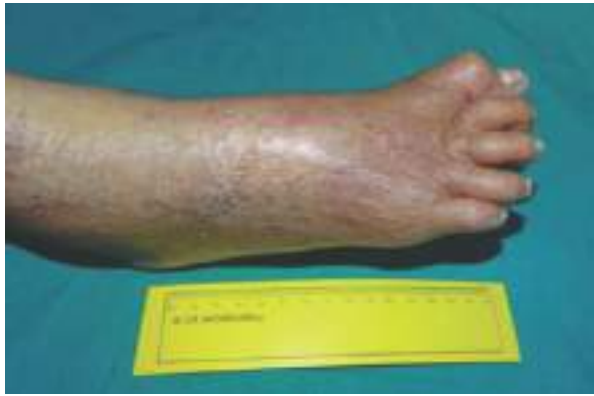Again let it be very clear that therapeutic footwear is inferior to TCC, as offloading is not adequate. The therapeutic footwear play important role in prevention of recurrences of planter ulcers, but should not be advised as a primary offloading strategy to heal ulcers. Immobilization of the limb can help to localize minor infection and prevent its spread to adjacent tissue [16].

Silicone Devices

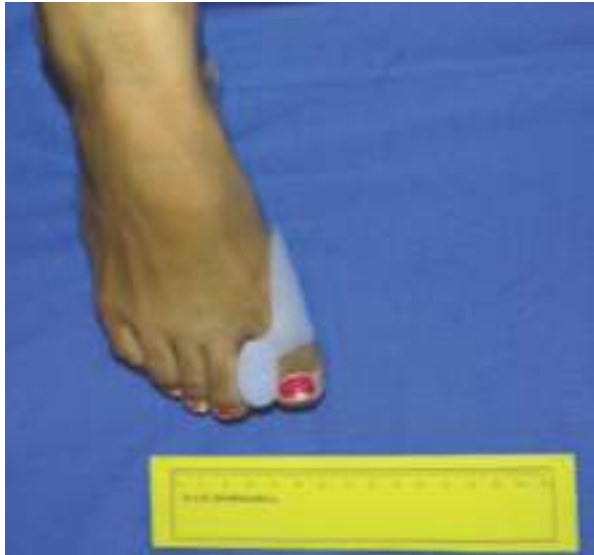There are different silicone devices available to be kept in a foot wear to offload the pressure areas.

For toe tip ulceration to heal we off load with silicone splint. There are splints available for one toe, two toes, three toes, four toes and five toes. For hallux valgus, a special splint is available. Metatarsal cushion helps to off load the toes. Similarly silicone insoles, silicone medial arch and silicone heel pad is available for off loading different parts of the feet.

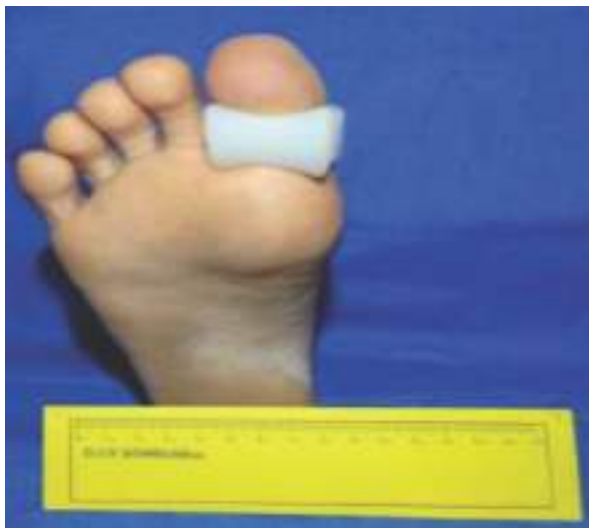Claw toes and hammer toes precipitates callosity and ulceration



Hallux valgus silicone splint



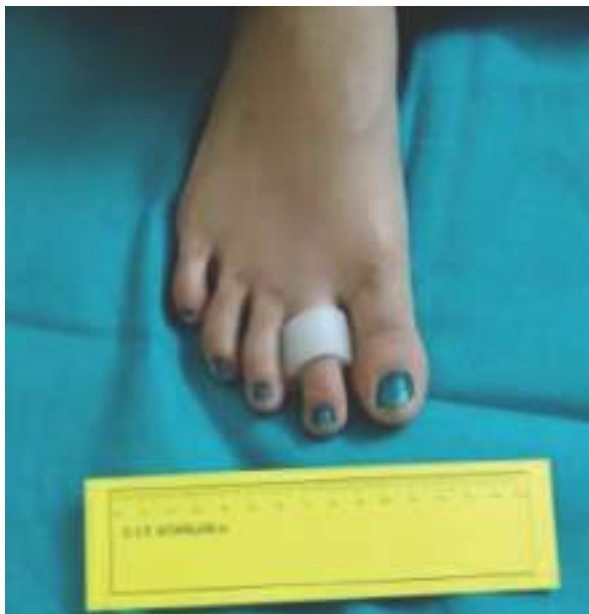Silicone toe ring



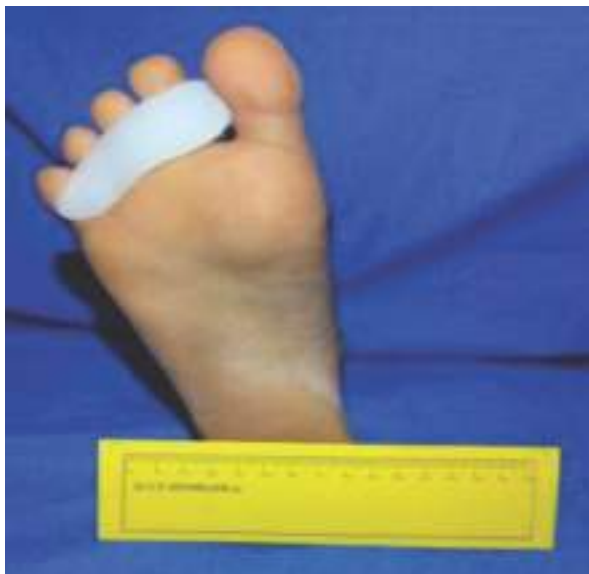Silicone insoles



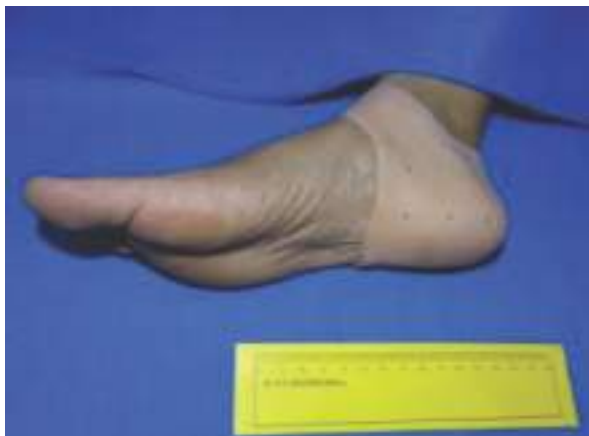Silicone single toe ring



Silicone multiple toe ring



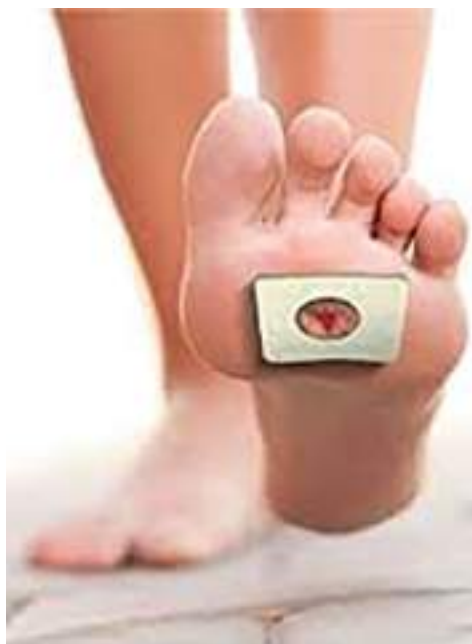Silicone heel



Adhesive Felt Pads [Felted Foam Dressing (FFD)]

Adhesive felt pads are available in the market to offload ulcers and callosities. Felted foam dressing is described in literature since almost 10 years [17–20]. It is cut to shape and stuck to plantar aspect of the foot. It remains in position indoor as well as outdoor. The patients may not wear therapeutic footwear continuously indoor as well as outdoor and we may not get the result. With adhesive felt pad even if patient walks at home, there is offloading. No comparative data is available for healing rates with TCC and FFD.

Example: Prozole.



Compliance is a problem as far as duration of wearing foot wears is concerned. Most of the patients wear foot wears only outdoor, that too for an hour or so. Majority of time they are indoor where they continue walking unprotected.

It is required to wear offloading foot wears for more than 60% of day time [21] to prevent recurrences and footwear to be effective. In another study, it was found that only 12% of people use for more than 80% of daytime [22]. The main issue is cosmetic look. During holidays, weddings, other ceremonies, patients don't wear them because they don't feel it attractive [23]. Sometimes while wearing foot wears they feel unsafe.

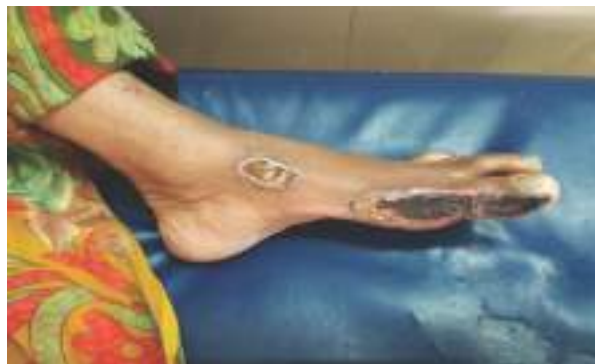Immobilization

Immobilization is a principle which should be followed in any wounds near joint crease. Operated wounds crossing the joints heals well with minimum of immobilization, but once the wound gaps or there is an open wound near or across a joint, immobilization is a must. For example, operation of knee replacement is done with a long incision crossing the knee joint. Patient is mobilized and even some physiotherapy is started, but because the wound is primarily closed, it heals well. But if there is a full thickness open wound over patella it does not heal until knee is immobilized. So is the case with wounds around shoulder, ankle and even hip.

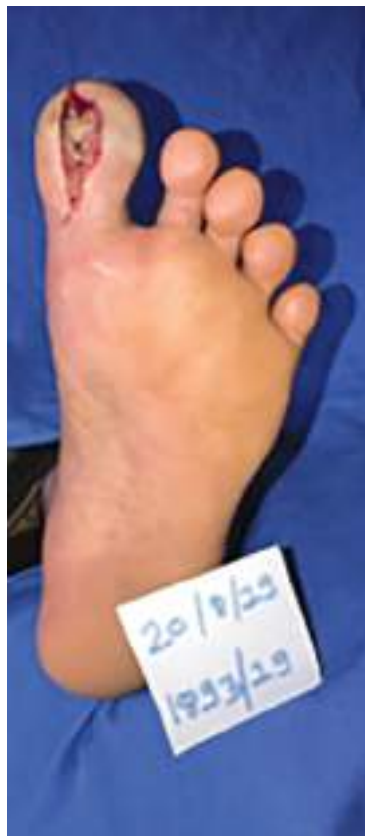Immobilization of joints is done by plaster cast or splint. If a tendon or muscle is visible in the floor and is moving, it should be considered as a content of an ulcer and if the content of the ulcer is not fixed, ulcer would not heal. No dressing can heal such wounds without immobilization.

Not only to.

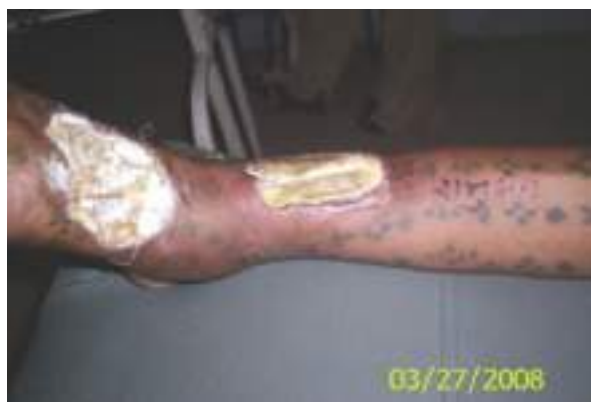Medial side of first metatarsophalangeal joint ulcers need immobilization of MTP joint

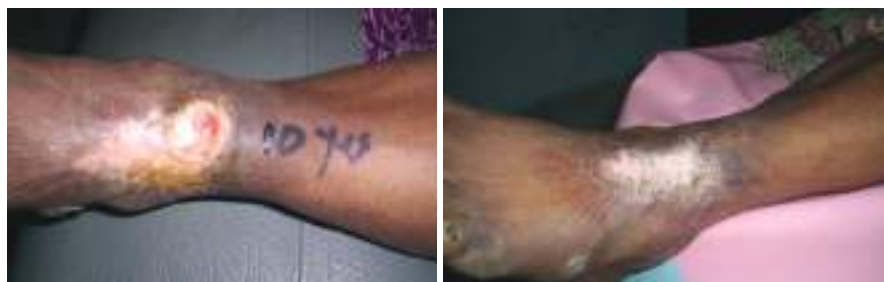

Interphalangeal and MTP
joint ulcers need
immobilization



Ulcers containing tendons
and muscle in the floor require
immobilisation





Ulcer in front of the ankle of 10 years duration healed in 20 days after wound margin excision and plaster immobilization

Comments

Off loading is a principle required to be followed for any wounds, more so for feet. A disabled person walking on any part of the body also needs off loading. The air bed, water bed provided for pressure sores is also a type of off loading. Offloading for feet can be achieved by many ways. For foot ulcer to heal, footwear should not be advised. Mixture of insole and out sole modifications is required for keeping an ulcer healed. Soft tissue also needs plaster to heal if a wound is around a joint or if it has muscle, tendon in the floor as a content of an ulcer. The immobilization should be continued till scar becomes strong, otherwise it breaks and reulcerates.

References

1. Bauman JH, Girling JP, Brand PW. Plantar pressures and trophic ulceration: An evaluation of footwear. *J Bone Joint Surg.* 1963;45:652–73.
2. Ctercteko GC, Dhanendran M, Hutton WC, LeQusne LP, et al. Vertical forces acting on the feet of diabetic patients with neuropathic ulceration. *Br J Surg.* 1981;68:608.
3. Armstrong DG, Nguyen HC. *Diabetes Care.* 2001;24(6):1019–22.
4. American Diabetes Association. Consensus development conference on diabetic wound care. *Diabetes Care.* 1999;22:1354–60.
5. Elftman H. A cinematic study of the distribution of pressure in the human foot. *Anat Rec.* 1934;59:481.
6. Harris RI, Beath T. Army foot survey. Ohawa: Report of national research council of Canada; 1947.
7. Barnes D. A comparative study of two barefoot pressure measuring systems. BMSc thesis, University of Dundee; 1994.
8. Holmes GB, Willits NH. Practical considerations for the use of the pedobarograph. *Foot Ankle.* 1991;12(2):105–8.
9. Wolf L, Stess R, Graf P. Dynamic foot pressure analysis of the diabetic Charcot foot. *J Am Pediatr Med Assoc.* 1991;81:281.
10. Rose N, Feiwell LA, Cracchiolo AC. A method for measuring foot pressure using a high resolution, computerized insole sensor: the effect of heel wedges on plantar pressure distribution and center of force. *Foot Ankle.* 1992;13(5):263–70.

11. Pitei D, admonds M, Lord M, et al. F SCAN: a new method of in-shoe dynamic measurement of foot pressure. *Diabet Med.* 1993;7(Suppl, 2):S39.. (abstract)
12. *Diabetes Care.* 2008;31(11):2118–9.
13. Lavery LA, Vela SA, Lavery DC, Quebedaux TL. Reducing dynamic foot pressures in high risk diabetics with foot ulcerations: A comparison of treatments. *Diabetes Care.* 1996;19:818–21.
14. Chantelau E, Kushner T, Spraul M. How effective is cushioned therapeutic footwear in protecting diabetic feet? A clinical study. *Diabet Med.* 1990;7:355–9.
15. Uccioli L, Faglia E, Monticone G, et al. Manufactured shoes in the prevention of diabetic foot ulcers. *Diabetes Care.* 1995;18:1376–8.
16. Mueller MJ, Diamond JE, Sinacore DR, et al. Total contact casting in treatment of diabetic plantar ulcers: Controlled clinical trial. *Diabetes Care.* 1989;12:384–8.
17. Zimmy S, Schatz H, Pfohl U. The effects of applied felted foam on wound healing and healing times in the therapy of neuropathic diabetic foot ulcers. *Diabet Med.* 2003;20:622–5.
18. Ritz G, Kushner D, Friedman S. A successful technique for the treatment of diabetic neurotrophic ulcers. *J Am Podiatry Med Assoc.* 1992;82:479–81.
19. Kiewied J. Felt therapy for leprosy patients with an ulcer in a pressure area (letter). *Lepr Rev.* 1997;68:378–81.
20. Fleischli JG, Larvery LA, Vela SA, Ashry H, Lavery DC. Comparison of strategies for reducing pressure at the site of neuropathic ulcers. *J Am Podiatr Med Assoc.* 1997;8:466–472.2q.
21. Macfarlane DJ, Jensen JL. Factors in diabetic footwear compliance. *J Am Podiatr Med Assoc.* 2003;93:485–91.
22. Armstrong DG, Dang C, Nixon BP, Boulton AJ. The hazards of the holiday foot: persons at high risk for diabetic foot ulceration may be more active on holiday. *Diabet Med.* 2003;20:247–8.
23. Boulton AJ, Jude EB. Therapeutic footwear in diabetes: the good, the bad, and the ugly? *Diabetes Care.* 2004;27:1832–3.

Hypertrophic Scars and Keloids

12

Abstract

Overexpression of fibrous tissue results in formation of hypertrophic scars and keloids. Normal apoptosis of fibroblasts is lacking in such abnormal scars. Chest wall scars and scars crossing the joints have more chances to be hypertrophic. This also leads to joint contractures.

These scars can be managed by pressure garments, pressure bandages, local application of silicone gel material and certain local creams. Steroid injections, 5-fluorouracil injection help in regression of keloids.

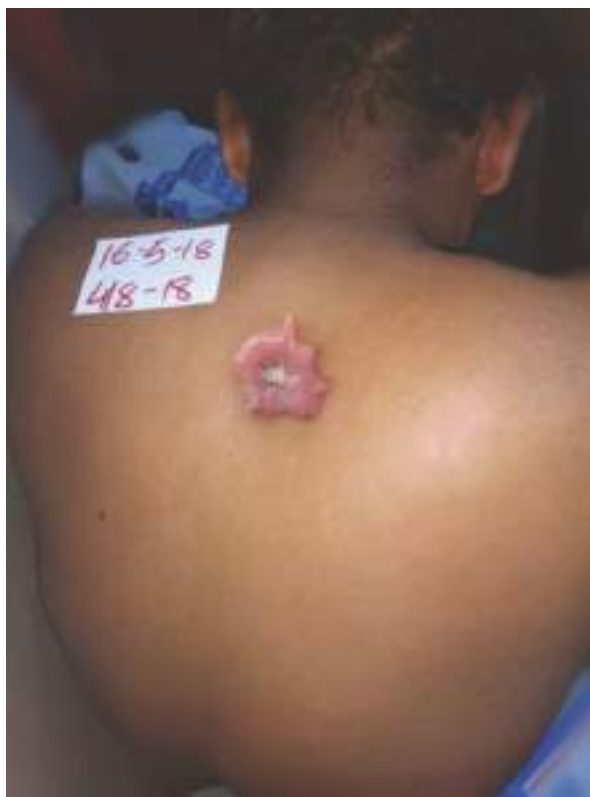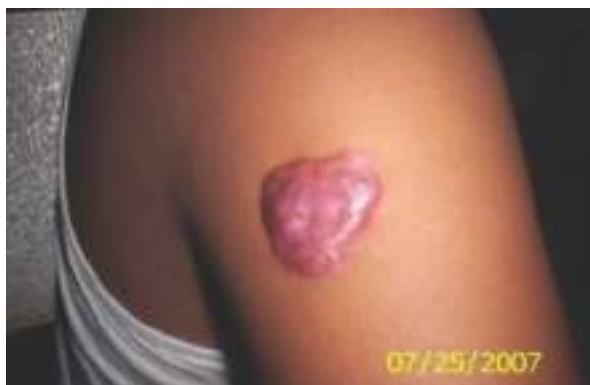Apoptosis is an important feature of wound repair and its regulation. In keloid fibroblasts there is less of apoptosis than normal fibroblasts. Keloid fibroblasts have high rates of apoptosis with treatment of steroids, gamma interferon and with less of oxygen supply [1, 2].

Hypertrophic scar can be managed by following methods

- (a) Pressure therapy: Pressure garments are used for prevention. 24–30 mmHg pressure for 6–12 months helps to reduce hypertrophic scar.
- (b) Silicone gel sheet.
- (c) Intralesional steroid injection: Local steroid creams are not so effective but injections of steroids in scar are effective.
- (d) Cryo-therapy: The cryo-therapy induces vascular damage, tissue anoxia and ultimately tissue necrosis. It is generally used for very small scar.
- (e) Radio therapy: Superficial X-rays, brachytherapy, electron beam therapy have been used with good results.
- (f) Laser therapy: Good results are observed with 585 nm pulsed dye laser (PDL)
- (g) Anti metabolites like 5-fluorouracil and mitomycin C.
- (h) Surgical modalities: Excision, z-plasty, etc.

Silicone Gel Sheet

When we discuss about wound healing, care of healed scar is also equally important. When the deposition of fibrous tissue doesn't stop there is hypertrophic scar or keloid formation. Self adhesive silicone gel sheet is medically proven to be up to 90% effective in the improvement of red, dark, or raised scars.



Mechanism of Action

It occludes the skin to hydrate the scar area. This means moisture is locked into the skin around scar, reducing the blood supply and deposition of collagen, what the body uses to rebuild deeply wounded skin [3]. The stratum corneum is responsible for regulation of transepidermal water loss. In hypertrophic scar patients the stratum corneum allows more water loss. This process stimulates keratinocytes to produce more cytokines which in turn activates fibroblasts to release more collagen. Silicone gel sheet prevents these chemical changes. Application of silicone gel sheet for 2–3 months controls collagen deposition.

It must not be used on open or infected wounds or over scabs or stitches. It can be used for healed wounds to prevent keloid formation and also on hypertrophic scar and keloid [4].

Do not use ointment or cream under the gel sheet.

Some gel sheets available in the market are durable, comfortable, and reusable for up to 28 days. Silicone gel sheets are ideal for day and night use and also safe to use in children and adults. Silicone is also available in simple gel form for local application.

Allium cepa extract in combination with heparin sodium and allantoin is also thought to be effective in prevention and management of hypertrophic scar [5–7]. Plain silicone and silicone dioxide combination in gel form is also effective in managing scars [8–10].

Steroids reduce extracellular matrix production, reduces inflammatory protein production, decreases cytokine production to help scar management [11]. Triamcinolone 10–40 mg/ml is to be injected intrakeloidal [12].

Examples: Scarend gel, Scarend silicone gel, Cica care, scaraze.

Comments

Keloids are usually not excised. Steroid injections and hyaluronic acid injection in the keloids give good results but this is useful for small scar. Acne, posttraumatic, postsurgical and post-chicken pox scars can be very well managed with local application of silicone and other available gels. Extensive burns scar cannot be managed by injection therapy. Silicone gel sheet and compression therapy help to reduce the hypertrophic scars and keloids. There are pressure garments also available for hypertrophic scars and keloids.

References

1. Tanaka A, Hatoko M, Tada H, et al. Expression of p53 family in scars. *J Dermatol Sci* 2004;34:303–304.
2. Ladin DA, Hou Z, Patel D, et al. p53 and apoptosis alteration in keloid and keloid fibroblast. *Wound Repair Regen*. 1998;6:28–37.

3. Nilsson GE. Measurements of water exchange through skin. *Med Biol Eng Comput.* 1977;15:209–18.
4. Sawada Y, Sone K. Hydration and occlusion treatment for hypertrophic scars and keloids. *Br J Plast Surg.* 1992;45:599–603.
5. *Vet Med.* 2012;57(6):287–92.
6. *J Clin Aesthet Dermatol.* 2012;5(6):18–24.
7. *J Drugs Dermatol.* 2012;11(1):74–81.
8. Wiseman, et al. *Trials.* 2017;18:72. *J Cutan Aesthet Surg* 2009;2(2):104-106.
9. *J Cutan Aesthet Surg.* 2009;2(2):104–6.
10. Tang HL, KSR L, Ing T. *BMJ Case Rep.* 2015;2015
11. Cohen JK, Diegelmann RF. The biology of keloid and hypertrophic scar and the influence of corticosteroids. *Clin Plast Surg.* 1977;4:297–9.
12. Sclafani AP, Gordon L, Chadha M, et al. Prevention of earlobe keloid recurrence with postoperative corticosteroid injection versus radiation therapy: a randomized, prospective study and review of the literature. *Dermatol Surg.* 1996;22:569–74.



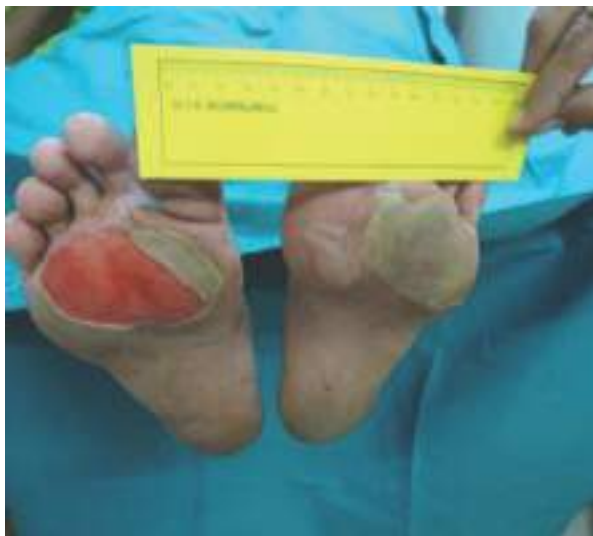Abstract

There are many different types of wounds which we come across in our day to day practice. We need to take biopsy in so many patients. There are some medicines responsible for ulcers, some autoimmune conditions and some systemic diseases associated with skin ulcerations. In some ulcers it is difficult to know why they are not healing and sometimes out of many local wound dressing materials, some dressing material works wonders. These rare types of skin ulcers need expertise to diagnose and treat.

Burns Wounds

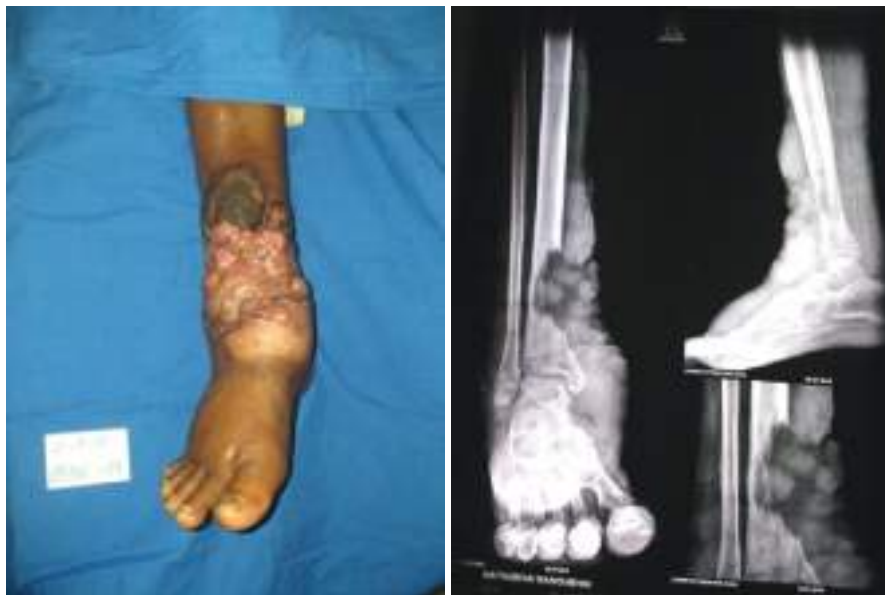The management of burns patient depends upon the depth of the burns and extent of the burns. Previously open method was preferred to closed method, but nowadays closed dressing is advisable to maintain moist wound environment. Warm room with humidity around 60–65% is advisable for better healing. All burns wounds initially are sterile, to prevent infection is a main concern. In burns, edema causes ischemia and oxygenation of tissue is crucial. Early fasciotomy and escharotomy is indicated. In electric burns there is more of edema of muscles which again causes distal ischemia.

Thermal burns of feet



Silver sulpha diazine types of preparations are routinely used. Because of large surface area, iodine preparations are not used to avoid iodine toxicity. Extensive skin grafting is required but cultured keratinocytes provide huge area of coverage and is ideal though expensive. Amnionic membrane dressing also is advisable as it is available in plenty [1–5].

Malignant Wounds



Malignant wound eroding the bone

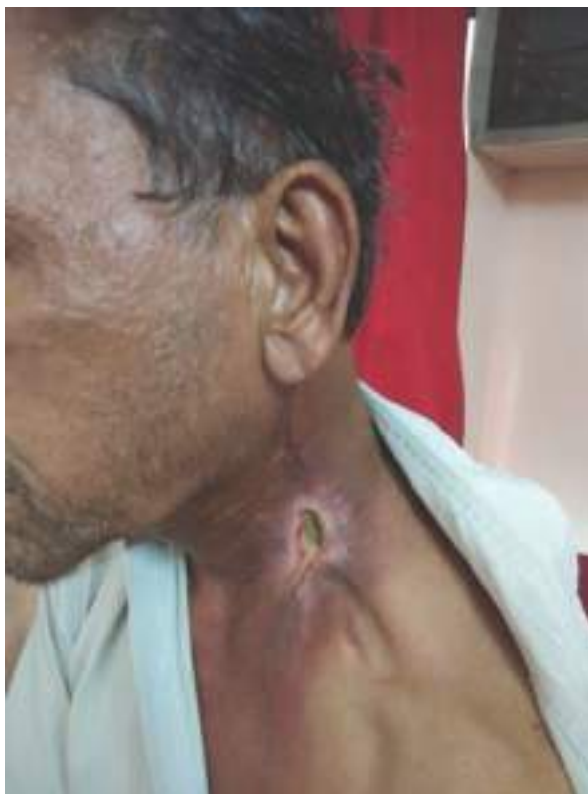After the definitive treatment of malignant wounds, the other treatment required is control of bleeding, control of foul smell and if possible to heal. The foul odor is probably because of bacteroides. There are some volatile fatty acids which are end products and they are responsible for bad smell [6]. Activated charcoal dressing absorbs malodorous chemicals before they pass to the atmosphere. Metronidazole is effective against both gram positive and gram negative organisms. Silver dressings and sugar paste and honey dressings have antibacterial properties and smell removing properties. Topical application of sucral fate paste, 1:1000 concentration of local adrenalin helps to control bleeding. Sometimes cauterization of bleeder or ligation of vessels is required [7–11].

Radiation Wounds

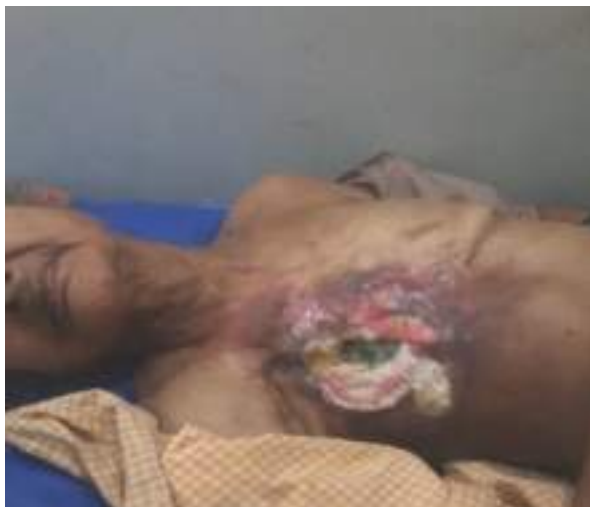Non healing ulcers are a complication of radiotherapy. It can develop upto decades after radiation. **Radiation causes endarteritis and dermatitis.**

[12] The local treatment includes wound dressings, gentian violet application and hyper baric oxygen therapy [13]. Skin grafting and local skin flaps usually do not survive. Vascularized myocutaneous flaps and omental flaps can help in healing of ulcers.

Ca larynx treated by
radiotherapy



Radiation wound where ribs are eroded and lung is seen through the wound

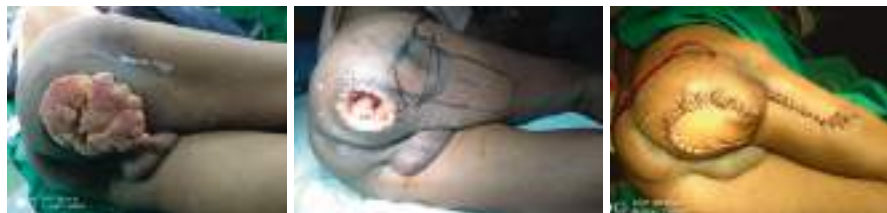

Pressure Ulcers

Normal end capillary pressure is 32 mmHg. If more pressure is maintained over a bony prominence, it leads to ulceration. Pressure for a shorter time may not damage the tissue, but same pressure for a longer time may cause ulceration. Similarly very high pressure for short period may not cause ulceration. Muscle is more susceptible for pressure induced ischemia because of its greater metabolic requirement. In addition to direct pressure, shear forces are more significant as it also compromises the circulation. There are different stages of pressure injury formation:

1. Stage of hyperemia: There is cutaneous redness which becomes normal in 1 h of removal of pressure.
2. Stage of ischemia: This develops if pressure continues for 2–6 h.
3. Stage of necrosis: There is induration and blue discoloration of skin with frank necrosis if pressure is not relieved for more than 6 h. This is an irreversible change.
4. Stage of ulceration: Infection develops and necrotic area ulcerates in two weeks time.

Prevention is the best treatment, conventional dressing materials are useful but sometimes extensive reconstructive surgery is required [14].



This is a case of ischial tuberosity area pressure sore treated by a flap.(Curtsey Dr. Bhaumik Bhayani, Plastic Surgeon, Rajkot)

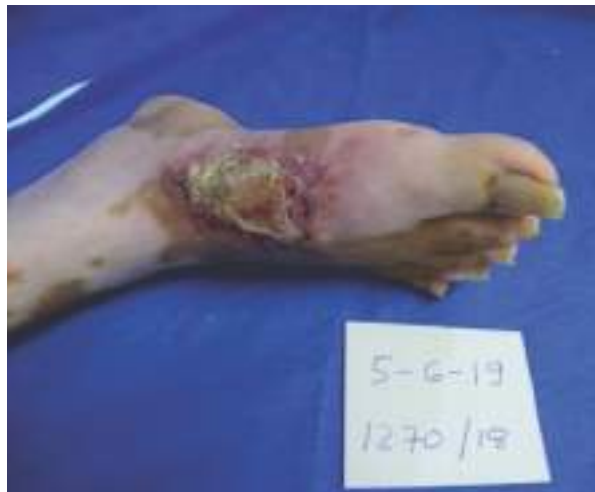Vasculitic Ulcers

Vasculitis is inflammation of blood vessels and it represent on the surface of skin in different physical signs. Primary vasculitis is classified as follows:

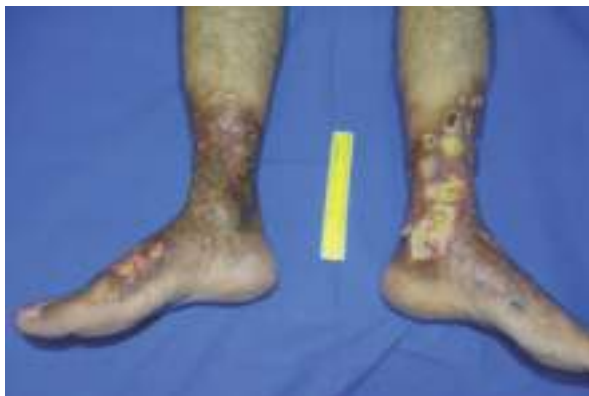1. Chronic lymphocytic vasculitis
2. Leukocytoclastic vasculitis
3. Leukemic vasculitis
4. Vasculitis in granulomatosis
5. Wegener's granulomatosis
6. Giant cell (temporal arteritis)

If small vessels are involved there is palpable purpura and superficial ulcers and when medium sized vessels are involved, there are painful nodules which form deep ulcerations. Vasculitis can affect capillaries, arteries of limbs, renal, coronary and hepatic arteries and even large arteries like aorta. The vasculitic ulcers have etiology of autoimmune disease, rheumatoid arthritis, and inflammatory conditions. Some of the vasculitic ulcers may be associated with inflammatory bowel disease, inflammatory arthropathies myeloproliferative diseases, dermatomyositis, SLE, bullous pemphigoids, antiphospholipid syndrome, rheumatoid arthritis, etc. The immunosuppressant treatment of different types is the treatment for vasculitic ulcer [15–17].

Foot ulcer in a case of ulcerative colitis



Vasculitic ulcers

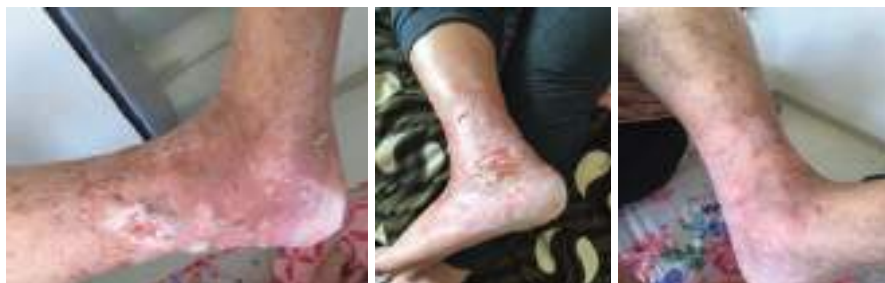

Vasculitic ulcers require local wound care in addition to systemic immunosuppressive therapy. Sometimes adequate dose of antibiotics for a long time is required for healing.

Case Presentations

Hydroxyurea Induced Leg Ulcers

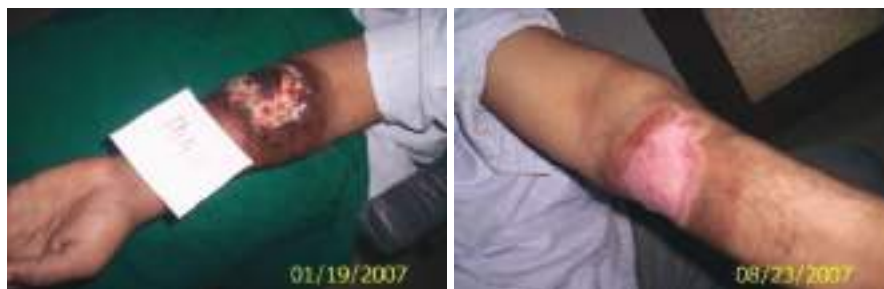A 70 year male patient [himself a Doctor] was suffering from polycythaemia vera rubra for last 35 years. He developed very painful ulcers in both his legs. Dressings were done with many different antiseptics and many types of antibiotics were given. He was treated by many surgeons and plastic surgeons, but ulcers never healed for six months. He was on hydroxy urea medication for polycythemia. Only after discontinuation of hydroxyl urea, it started healing and then healed in three months after discontinuation of hydroxyurea. Hydroxy urea induced ulcers are seen usually 15 years after treatment initiation [18–20].



Lupus Vulgaris

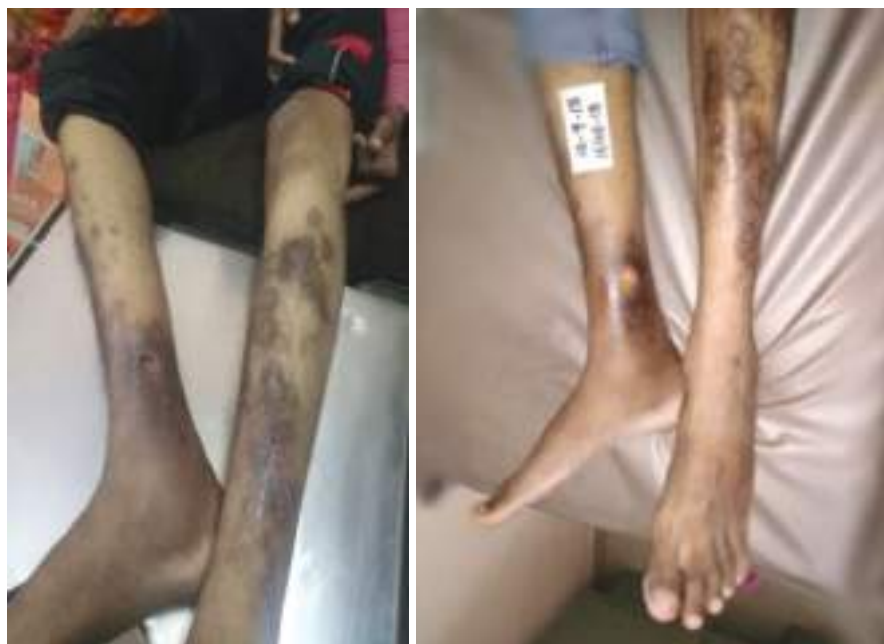Tuberculous ulcers are more common in head and neck area which are usually secondary to underlying lymph node infection. Primary tubercular skin lesion is not common in other parts of the body except face and neck. We had this patient of

45 years female who presented with non healing left forearm ulcer of 6 months duration which was not healing with conventional and advanced dressings. Biopsy confirmed the diagnosis of lupus vulgaris which then healed with anti tuberculous treatment [21, 22].



This was biopsy proved tuberculus ulcer which healed after debridement with anti tubercular treatment and silver foam dressings.

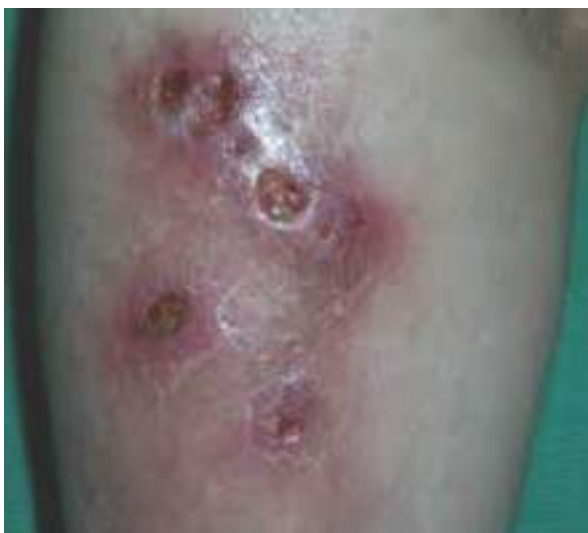Ulcer in Thalassemia Patient



This young male patient of 27 years, presented with right leg non healing recurrent ulcer. Patient was being treated for this ulcer by different antibiotics and local anti-septics. We treated this patient with levofloxacin, aspirin and elasto crepe bandage with local debriding ointment. The ulcer healed.

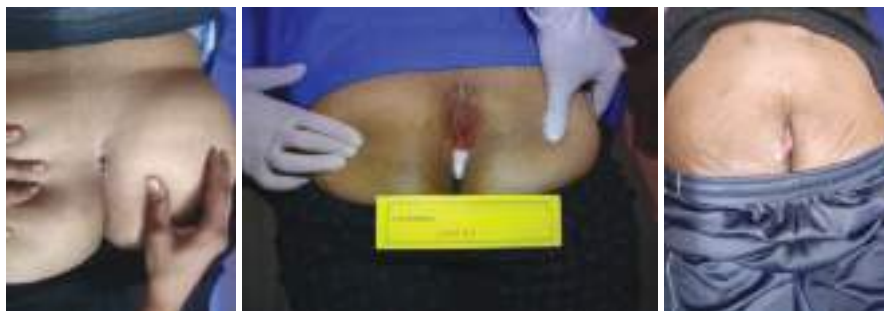
All hemoglobinopathies like thalassemia, sickle anemia, and anemia of other etiology can have leg ulcer. In patients of thalassemia, anemia is one cause but other cause is supposed to be high fetal hemoglobin concentration. Leg ulcer occurs in 25% of pts. of sickle cell disease. Hyperbaric oxygen therapy has a role for treatment [23, 24].

Necrobiosis Lipoidica Ulcers



Necrobiosis lipoidica diabetorum is the word used for the leg lesions. It is also seen in non diabetic patients. The subcutaneous tissue becomes hard and sometimes it is at multiple sites in the legs. It is sometimes misdiagnosed as infective pathology and drained. These types of wounds than take a very long time to heal. Sometimes patients may present directly with an ulcer with indurated base. Local application of antiseptics does not work. Good quality corticosteroid helps in wound healing. This patient of 55 years female presented with multiple small infected ulcers of 4 months duration. We took a biopsy to prove it as necrobiosis lipoidica [25–27].

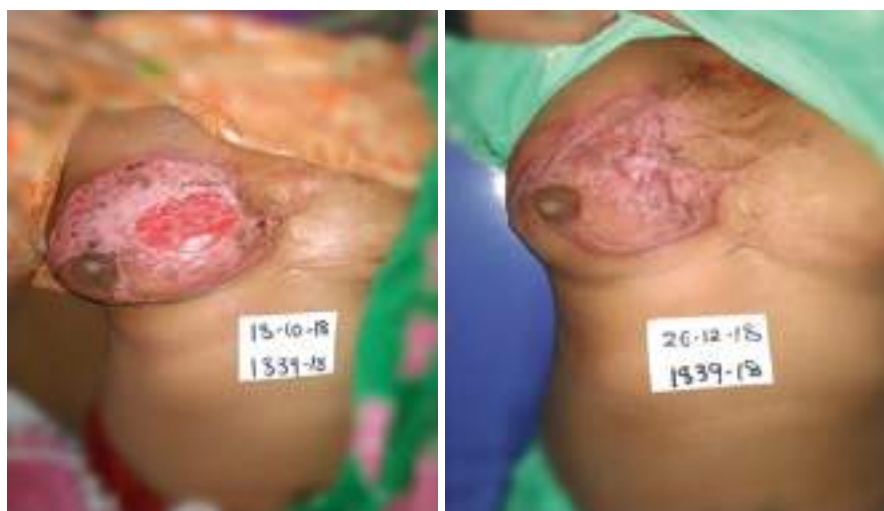Pilonidal Sinus and Post Pilonidal Surgery Wounds



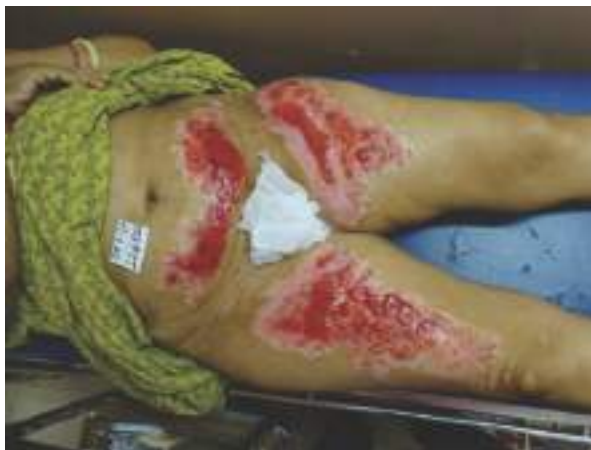Pilonidal sinuses are very notorious. Traditional procedures of excision and keeping it open, excision and closure, excision and flap reconstruction all have limitations and there are chances of recurrences. The granulation tissue and the process of healing are unpredictable in pilonidal sinuses. Complete healing with good scar breaks very fast and reulcerates. My experience is scooter, bicycle driving is responsible for delayed healing or nonhealing for many working men and women. Prolonged sitting on a hard surface with stretching of wound margin apart might play a role. I advise to avoid such activities for 6–12 weeks after complete healing for the scar to become mature and strong [28–36]. As usual hair in the back is ofcourse the route cause in many.

Unusual Ulcers

(a)



This patient had breast ulcer with gradually spreading infection. Histopathology was nonspecific infection. All the blood reports were normal. In spite of repeated debridements and antibiotics according to culture and sensitivity, it was spreading from all the sides. Many different types of local dressing materials were tried, but there was no response. It persisted for 2 months. After starting oral corticosteroids it healed.

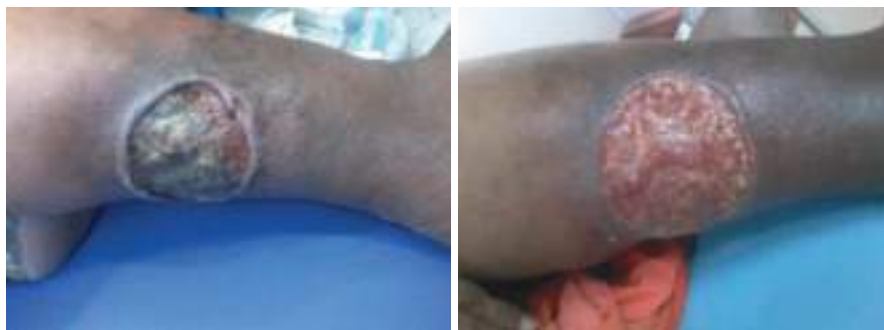

(b) {Burns case}

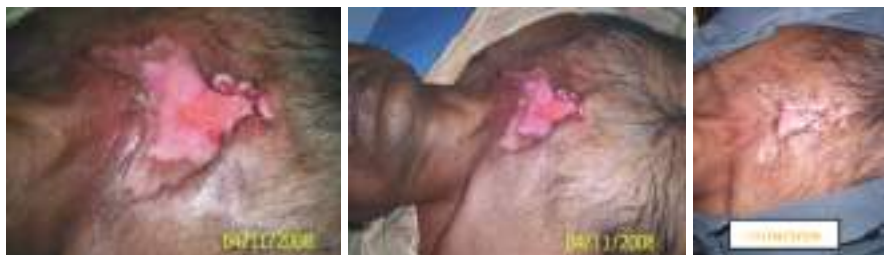This patient had burns. She was treated with many antiseptics and different types of antibiotics. Ulcers were not healing for 10 months. Biopsy did not show vasculitic features and was suggestive of non specific inflammation. All the blood reports were normal. It healed only after giving oral corticosteroids.

(c) **Pyoderma gangrenosum**

Pyoderma gangrenosum is an inflammatory skin disorder. It requires immunosuppressants in addition to local wound care [37–39].

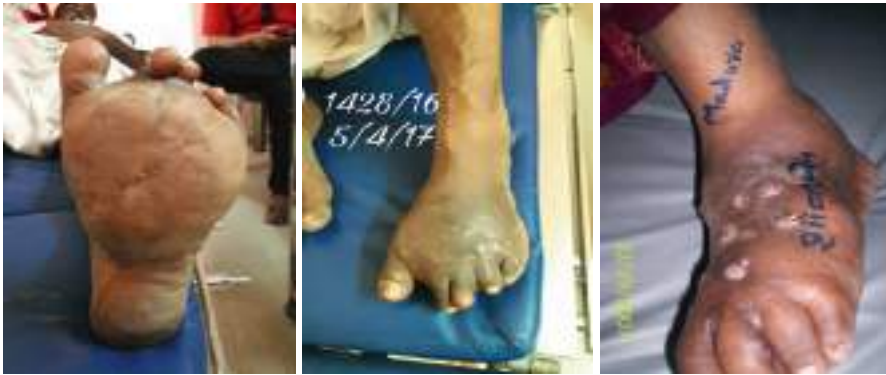

(d) **Ulcer over sternum**



This patient presented with nonhealing ulcer over anterior chest of one year duration. Multiple biopsies were taken which were suggestive of non specific inflammation. Iodine, silver, and multiple foam dressings were tried for one month without appreciable healing. Even growth factor did not heal the wound. Collagen dressing in the form of a sheet ultimately healed the wound.

- (e) **Madura foot:** Sinuses anywhere in the body including foot cannot be managed by simple dressings. Sinuses can be due to suture material or foreign body, osteomyelitis, maduromycosis and actinomycosis. As such, role of local dressing is minimal in sinuses anywhere. The route cause of sinus should be treated.

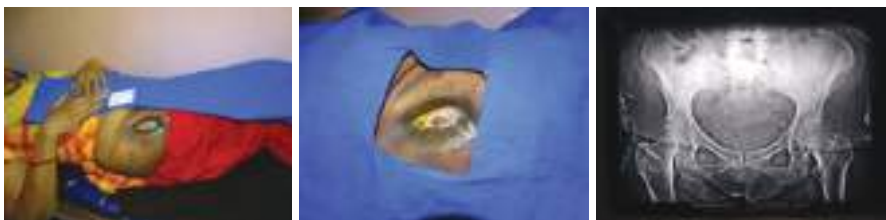

Madura foot

We come across rare types of wounds in our day to day practice. Raynaud's ulcer requires calcium channel antagonist, vasodilators, infusion of Prostaglandin E1 or epoprostenol (prostacyclin) in addition to local wound care [40–45].

There is one condition known as calciphylaxis. There are calcium deposits in the base of ulcers; it is seen in hyperparathyroid patients and in patients undergoing dialysis. There is lot of fibrosis and calcification in the base of the ulcer. These wounds are very difficult to heal. A very rare cause of a leg ulcer is Paget's disease.

- (f) **Calcinosis cutis**



This patient had non-healing ulcer of three years duration over right gluteal region. Excision, debridement and histopathology were done which was suggestive of calcification. X-rat showed similar calcification in opposite gluteal region without ulceration. There was no evidence of healthy granulation tissue formation and healing. Blood reports were suggestive of borderline hyperparathyroidism with normal serum calcium level. The endocrinologist did not advise any specific treatment for parathyroid [46–49].

References

1. Settle JAD, editor. Principles and practice of burn management. New York: Churchill Livingstone; 1996.
2. Babu M, Shanmuganathan N, Karthikeya Prabhu B. In: Surabahi S, Tiwari VK, Goel A, editors. Wound healing in burns from principles and practice of burn care. New Delhi: Jaypee Brothers Medical Publishers; 2010. p. 51–68.
3. Zawaki BE. In: Boswick Jr JA, editor. The local effects of burn injury. The art and science of burn care. Rockville: Aspen; 1987. p. 27.
4. Zawaki BE. Reversal of capillary stasis and prevention of necrosis in burns. *Ann Surg.* 1974b;139:98.
5. Sarabahi S. In: Sarabahi S, Yiwari VK, Goel A, editors. Burn wound management from principle and practice of burn care. New Delhi: Jaypee publishers; 2010. p. 153–95.
6. Editorial. Management of smelly tumours. *Lancet.* 1990;1:141–2.
7. Moody M, Grocott P. Let us extend our knowledge base. Assessment and management of fungating malignant wounds. *Prof Nurse.* 1993;8(9):587–90.
8. Fairburn K. Towards better care for women. Understanding fungating breast lesions. *Prof Nurse.* 1993;8(12):204–12.
9. Haisfield-Wolfe ME, Rund C. Malignant cutaneous wounds: a management protocol. *Ostomy Wound Manage.* 1997;43:56–66.
10. Naylor W. Malignant wounds: etiology and principles of management. *Nurs Stand.* 2002;16:45–53.
11. Bird C. Managing malignant fungating wounds. *Prof Nurse.* 2006;15(4):253–6.
12. Landthaler M, Hagspiel HJ, Braun-falco O. Late irradiation damage to the skin caused by soft X-ray radiation therapy of cutaneous tumours. *Arch Dermatol.* 1995;131(2):182–6.
13. Borg M, Wilkinson D, Humeniuk V, Norman J. Successful treatment of radiation induced breast ulcer with hyperbaric oxygen. *Breast.* 2001;10(4):336–41.
14. Goel A. Chapter 24: Pressure sores. In: Principle and practice of wound care; 2012. p. 293–5.
15. Assmann G, Pfreunds Chuh M, Voswinkel J. Rituximab in patients with rheumatoid arthritis and vasculitis associated cutaneous ulcers. *Clin Exp Rheumatol.* 2010;28(57):81–3.
16. Lui NL, Thumboo J, Fong KY. A case of refractory vasculitis ulcer in systemic lupus erythematosus patients responding to rituximab and hyperbaric oxygen therapy. *Int J Rheum Dis.* 2009;12(4):366–9.
17. Veale DJ, Muir AH, Morley KD, JFF B. Treatment of vasculitic leg ulcers in connective tissue disease with iloprost. *Clin Rheumatol.* 1995;14(2):187–90.
18. Kato N, Kimura K, Yasukawa K, Yoshida K. Hydroxyurea-related leg ulcers in a patient with chronic myelogenous leukemia: a case report and review of the literature. *J Dermatol.* 1999;26:56–62.
19. Suehiro M, Kishimoto S, Wakabayashi T, Ikeuchi A, Miyake H, Takenaka H, Okano A, Hirai H, Shimazaki C, Yasuno H. Hydroxyurea dermatopathy with a dermatomyositis-like eruption and a large leg ulcer. *Br J Dermatol.* 1998;139:748–9.

20. Best PJ, Daoud MS, Pittelkow MR, Pettitt RM. Hydroxyurea-induced leg ulceration in 14 patients. *Ann Intern Med.* 1998;128:29–32.
21. Ghorpade A. Lupus vulgaris over a tattoo mark--inoculation tuberculosis. *J Eur Acad Dermatol Venereol.* 2003;17(5):569–71. <https://doi.org/10.1046/j.1468-3083.2003.00787.x>. PMID 12941097.
22. James WD, Berger TG, et al. *Andrews' diseases of the skin: clinical dermatology.* New York: Saunders Elsevier; 2006. p. 335. isbn:978-0-7216-2921-6.
23. Matta N, Abbas O, Maakaron JE, Koussa S, Daderian RH, Taher AT. Leg ulcers in patients with β -thalassaemia intermedia: a single centre's experience. *J Eur Acad Dermatol Venereol.* 2013;28(9):1245–50. <https://doi.org/10.1111/jdv.12211>.
24. Eckman JR. Leg ulcers in sickle cell disease. *Hematol Oncol Clin North Am.* 1996;10:1333. CrossRefPubMedWeb of ScienceGoogle Scholar.
25. Quimby SR, Muller SA, Schroeter AL. The cutaneous immunopathology of necrobiosis lipoidica diabetorum. *Arch Dermatol.* 1988;124(9):1364–71. [PubMed].
26. Gebauer K, Armstrong M. Koebner phenomenon with necrobiosis lipoidica diabetorum. *Int J Dermatol.* 1993;32(12):895–6.
27. Hashemi DA, Brown-Joel ZO, Tkachenko E, Nelson CA, Noe MH, Imadojemu S, Vleugels RA, Mostaghimi A, Wanat KA, Rosenbach M. Clinical features and comorbidities of patients with necrobiosis lipoidica with or without diabetes. *JAMA Dermatol.* 2019;155(4):455–9.
28. Bascom JU. Pilonidal disease: long-term results of follicle removal. *Dis Colon Rectum.* 1983;23:800–7. <https://doi.org/10.1007/BF02554755>.
29. Bascom JU. Repeat pilonidal operations. *Am J Surg.* 1987;154(1):118–22. [https://doi.org/10.1016/0002-9610\(87\)90300-X](https://doi.org/10.1016/0002-9610(87)90300-X).
30. Bessa SS. Comparison of short-term results between the modified Karydakakis flap and the modified Limberg flap in the management of pilonidal sinus disease: a randomized controlled study. *Dis Colon Rectum.* 2013;56(4):491–8. <https://doi.org/10.1097/DCR.0b013e31828006f7>.
31. Hull TL, Wu J. Pilonidal disease. *Surg Clin North Am.* 2002;82(6):1169–85. [https://doi.org/10.1016/S0039-6109\(02\)00062-2](https://doi.org/10.1016/S0039-6109(02)00062-2).
32. Humphries AE, Duncan JE. Evaluation and management of pilonidal disease. *Surg Clin North Am.* 2010;90:113–24. <https://doi.org/10.1016/j.suc.2009.09.006>.
33. Käser SA, Zengaffinen R, Uhlmann M, Glaser C, Maurer CA. Primary wound closure with a Limberg flap vs. secondary wound healing after excision of a pilonidal sinus: a multicentre randomised controlled study. *Int J Color Dis.* 2015;30(1):97–103. <https://doi.org/10.1007/s00384-014-2057-x>.
34. Kepenekci I, Demirkan A, Celasin H, Gecim IE. Unroofing and curettage for the treatment of acute and chronic pilonidal disease. *World J Surg.* 2010;34(1):153–7. <https://doi.org/10.1007/s00268-009-0245-6>.
35. McCallum IJ, King PM, Bruce J. Healing by primary closure versus open healing after surgery for pilonidal sinus: systematic review and meta-analysis. *BMJ.* 2008;19:868–71. <https://doi.org/10.1136/bmj.39517.808160.BE>. PubMed.
36. Omer Y, Hayrettin D, Murat C, Mustafa Y, Evren D. Comparison of modified Limberg flap and modified elliptical rotation flap for pilonidal sinus surgery: a retrospective cohort study. *Int J Surg.* 2015;16:74–7. <https://doi.org/10.1016/j.ijsu.2015.02.024>.
37. Langan SM, Powell FC. Vegetative pyoderma gangrenosum: A report of two new cases and a review of the literature. *Int J Dermatol.* 2005;44(8):623–9. <https://doi.org/10.1111/j.1365-4632.2005.02591.x>. PMID 16101860.
38. Rashid RM. Seat belt pyoderma gangrenosum: Minor pressure as a causative factor. *J Eur Acad Dermatol Venereol.* 2008;22(10):1273–4. <https://doi.org/10.1111/j.1468-3083.2008.02626.x>. PMID 18837131.
39. Brooklyn T, Dunnill G, Probert C. Diagnosis and treatment of pyoderma gangrenosum. *Br Med J.* 2006;333(7560):181–4. <https://doi.org/10.1136/bmj.333.7560.181>. PMC 1513476. PMID 16858047.

40. Hemashettar BM, Siddaramappa B, Munjunathaswamy BS, et al. Phaeoacremonium krajdennii, a cause of white grain eumycetoma. *J Clin Microbiol.* 2006;44(12):4619–22. <https://doi.org/10.1128/JCM.01019-06>. PMC 1698411. PMID 17005754.
41. Severo LC, Oliveira FM, Vettorato G, Londero AT. Mycetoma caused by *Exophiala jeanselmei*. Report of a case successfully treated with itraconazole and review of the literature. *Rev Iberoam Micol.* 1999;16(1):57–9. PMID 18473595.
42. Vilela R, Duarte OM, Rosa CA, et al. A case of eumycetoma due to *Madurella grisea* in northern Brazil (PDF). *Mycopathologia.* 2004;158(4):415–8. <https://doi.org/10.1007/s11046-004-2844-y>. PMID 15630550.
43. Dorlands Medical Dictionary: botryomycosis. 2008. Archived from the original on 5 Sept 2008. Retrieved 10 July 2018.
44. Capoor MR, Khanna G, Nair D, et al. Eumycetoma pedis due to *Exophiala jeanselmei*. *Indian J Med Microbiol.* 2007;25(2):155–7. <https://doi.org/10.4103/0255-0857.32726>. PMID 17582190.
45. Loulergue P, Hot A, Dannaoui E, et al. Successful treatment of black-grain mycetoma with voriconazole. *Am J Trop Med Hyg.* 2006;75(6):1106–7. PMID 17172376.
46. Jiménez-Gallo D, Ossorio-García L, Linares-Barrios M. Calcinosis cutis and calciphylaxis. *Actas Dermosifiliogr.* 2015;106(10):785–94.
47. Valenzuela A, Chung L. Calcinosis: pathophysiology and management. *Curr Opin Rheumatol.* 2015;27(6):542–8.
48. Gunasekera NS, Maniar LEG, Lezcano C, Laga AC, Merola JF. Intralesional sodium thiosulfate treatment for calcinosis cutis in the setting of lupus panniculitis. *JAMA Dermatol.* 2017;153(9):944–5.
49. García-García E, López-López R, Álvarez-Del-Vayo C, Bernabeu-Wittel J. Iatrogenic calcinosis cutis successfully treated with topical sodium thiosulfate. *Pediatr Dermatol.* 2017;34(3):356–8.

Index

A

Absorbent dressings, 59–67, 71
Acellular matrix, 128, 129
Acriflavin, 44
Acriflavineum chloride, 44
Acticoat, 52
Adipose tissue stem cells (ASCs), 122, 123
Adult stem cells, 120, 121
Alginates
 in malodor, 80
 uses, 61
Allevyn, 61
Alloderm, 129
Allograft, 125, 126
AmchoPlast, 130
Anabact, 80
Apligraf, 126
Aqua cell hydrofibre, 59, 65
Autolytic debriders, 26, 38, 63, 64, 66, 69

B

Bacitracin, 48
Bacteroides, 165
Benzocaine, 45
Benzoin, 47
Betadine, 49
Biatain, 52, 59, 61
Biobraine, 129
Biofilm, 5, 21, 23, 40, 45, 49, 51, 53, 100
Biological vectors, 131
Biozel, 78
Bleach, 35
Bleaching agent, 46
Bone marrow mesenchymal stem cells (BMMSCs), 122

C

Cadaveric graft, 125
Cadaverine, 130
Cadexomer iodine, 48–50
Calcium sulphate, 55
Calgisorb, 59, 65
Carboxy methyl cellulose (CMC), 63, 65, 70, 115
Castor oil, 45
Cellular therapy, 123, 124
Cetrimide, 45
Charcoal dressings, 79
Chlorhexidine, 43, 53
Chloroxylonol, 45
Chondroitin 6-sulfate, 128
Collagen dressings-mechanism of action, 74
Compression bandage, 37, 105, 106
Cotton and acrylic fibre, 62
Cytokines, 2, 13, 21, 51, 116, 127, 130, 131, 161

D

Debridement
 autolytic, 26, 38, 69, 70
 biological, 26, 35–38
 chemical, 26, 31–34, 37, 40
 mechanical, 26–31, 97
Deficiency
 calory, 17
 copper, 17
 iron, 17, 18
 proteins, 18, 131
 vitamin A, 17
 vitamin B, 17
 vitamin C, 17, 18
 vitamin D, 17

Deficiency (*cont.*)

- vitamin E, 17
- vitamin K, 17
- zinc, 17, 18

Dermacyte, 130

Dermagraft, 126, 127

Dermasis, 129

Dermatitis, 45, 165

Dettol, 45

Dressings

- antiseptic, 2, 50, 56, 59, 61, 76, 168
- autolytic, 6, 38
- debriders, 33, 54
- hydrocolloides, 59
- moisturizers, 69
- paraffin, 7, 48

Dried methyl cellulose, 132

E

Electric therapy

- effects, 100
- indications, 99

Elemental silver, 50, 51

Embryonic stem cells (ESC), 120, 121

Endothelial growth factor (EGF), 114, 115, 118

Epithelization, 13, 16, 78, 116, 118, 124

Ethanol, 47

Extracellular matrix, 23, 40, 78, 82, 87, 124, 126, 129, 133, 161

Extracorporeal shock wave therapy (ESWT), 101

Exudates, 2, 4, 5, 7, 16, 19, 27, 48, 59–61, 65, 66, 76, 77, 81, 95, 102, 129

F

Fibroblasts, 2, 3, 5, 12–14, 16, 18, 38, 47, 48, 65, 78, 82, 98, 113, 114, 121, 123, 124, 126, 127, 131, 159, 161

myofibroblasts, 14

Fibrocyte, 122

Foam dressings, 52, 59–63, 70, 80, 95, 124, 154, 169, 173

Foille, 45

Fusidic acid, 55

G

Gene gun, 131, 132

Gentamicin, 55, 56

Glucose oxidase, 76

Glycerine, 70

magnesium sulfate, 69–71

Gold particles, 132

Growth factors, 3, 11, 13, 15, 16, 19, 21, 23, 37, 38, 54, 86, 99, 113–118, 122, 124, 126, 127, 130–133, 173

Gulluronic acid, 64

H

Haemopoietic stem cells (Hsc), 123

Healoderm, 78

Hepatocyte growth factor, 114, 127, 132, 133

Hexosamine, 15, 18

Honey

- manuka, 41, 73, 76, 77, 81
- pasture, 2, 73, 76
- mechanism of action, 76
- clinical use, 77

Hyaff, 78

Hyalofill, 78

Hyaluronic acid (HA), 78, 124
functions, 78

Hydrocortisone, 45

Hydrofibre, 65

Hydrogel, 4, 37, 52, 61, 69, 70, 77, 81

Hydrogen peroxide (H₂O₂), 2, 33, 38, 43, 46, 76, 77

Hydroxy proline, 15, 18

Hyper baric oxygen therapy (HBOT)

- hyperbaric chambers, 94
- indications, 91
- mechanism of action, 92
- side effects, 94

Hypochlorous acid (HOCL), 54, 96

I

Inflammation, 1, 5, 12, 13, 15, 54, 76, 78, 86, 116, 117, 129, 167, 172, 173

Insulin and dressing, 82

Integra, 129

Iodine

- cadexomer, 48–50
- povidone, 2, 48, 49, 77

Ionsil, 52

Isopropanol, 45

K

Kaltostat, 59, 65

Kolasil, 52

L

Liofoam, 61
Liposome nanoparticles, 132
Living skin equivalents (LSEs), 124–126

M

Maggots, 26, 35, 80
Mal odor, 63, 79
Mannuronic acid, 64
Marrow/mesenchymal stem cells
 (MSC), 122, 123
Matrix, 13, 14, 60, 74, 113, 116, 117,
 125–130
Matrix metalloproteases, 19
Melgisorb, 59, 65
Mepilex, 61
Mepilex Ag, 52
Merbromine, 44
Mercurochrome, 44
Mercurocol, 44
Mesenchymal stem cells
 (MSC), 101, 122, 123
Metalloproteases, 23
Metronidazole, 37, 55, 74, 80, 165
Microdacyn spray, 54
Muco polysaccharide, 13, 15
Mupirocine, 55

N

Nanocrystalline silver, 50, 52
Negative pressure wound therapy (NPWT)
 contraindications, 97
 equipment, 95
 mechanism, 96
 uses, 96
Neosporin, 48

O

Oasis wound matrix, 129
Octenidine dihydrochloride, 41, 53
Offloading, 137–142
Organization, 13, 45
Oxidized regenerated cellulose, 74, 76, 130
Oxofrin, 54
Oxum, 54
Oxygen wound therapy, 94
Ozone therapy
 bagging, 89
 mechanism of action, 89

P

Para-chloro-meta-xenol (PCMX), 45
Peptide growth factor, 131
Peroxide, 13, 46
Phenoxy methanol, 53
Pine oil, 45
Placental membrane, 130
Platelet derived growth factors (PDGF),
 113–115, 118, 126, 129, 132, 133
Polyethylene glycol, 48, 77
Polyglactin, 127
Polyglycolic acid, 127
Polyhexamethylene biguinide (PHMB), 53,
 56, 59
Polyisobutylene, 63
Poly lactic acid, 55
Polymethyl methacrylate (PMMA), 55, 56
polymyxin, 54
Polyvinyl pyrrolidone, 70
Porcine, 126, 129
Pramoxine, 45
Propylene glycol, 70
Proteases, 3–5, 15, 39, 81, 113, 130, 133
Purilone, 70
Pyridine, 53

R

Reconstitution, 11, 19
Regeneration, 1, 12, 15, 19, 106, 122, 123
Repair, 1, 3, 11–14, 74, 78, 86, 113, 122,
 123, 159
Rifampicin, 55

S

Savlon, 45
Silica, 74
Silver alginate, 50
Silver carboxymethyl cellulose, 81
Silver chloride, 50
Silver dressings, 51, 52, 54, 165
Silver metal, 50
Silver oxide, 50
Silver phosphate, 50
Silver stream, 52
Silver sulfadiazine, 52, 77, 117
Silver sulphate, 50
Small intestine submucosa
 (SIS), 129
Sodium hypochlorite, 54
Sorbalgan, 59, 65

- Stem cells
 multipotent, 120
 pluripotent, 120
 totipotent, 120
Sugar paste, 76, 77, 165
 mechanism, 76
- T**
Tetrachlorodecaoxide (TCDC), 54, 56
Tielle, 61, 62
Tincture benzoin, 47
Tincture iodine, 43
Tobramycin, 55
Transite, 129
Tungsten, 132
- U**
Ulcers, venous stasis, 50, 80, 101, 102, 105, 106
Ultrasonic therapy, 99
 contraindications, 100
 debridement, 31
- V**
Vancomycin, 54, 55, 65
Vascular endothelial growth factor (VEGF), 86, 96, 115, 126, 127, 131–133
Vascularization, 13
Vectors, 131–133
Venous stasis, 27, 29, 102, 105, 106
Viruses
 adenovirus, 133
 DNA, 132
 lenti, 132, 133
 moloney, 133
 RNA, 132, 133
- W**
Wokadine, 49
Wound contracture, 14, 124
Wound healing
 primary, 15
 secondary, 15
Wound healing factors
 and diabetics, 3
 local, 18
 systemic, 18, 19
Wound tensile strength, 14–15, 17, 18
- X**
Xenograft, 119, 126
- Z**
Zeasorb, 45
Zolene HC, 45
Zotobac, 53
Zyomet gel, 80